

## UPDATE

# Imaging Techniques in Cardiovascular Medicine

Javier Bermejo,<sup>a</sup> Fernando Alfonso,<sup>a</sup> and Xavier Bosch<sup>b</sup>

<sup>a</sup>Editores Asociados y <sup>b</sup>Editor Jefe de REVISTA ESPAÑOLA DE CARDIOLOGÍA.

During the past 2 decades, imaging techniques have come to play an indispensable role in practically all cardiovascular illnesses and not only in those conditions where these techniques have typically been used to determine the existence of a disease (for example, aortic or pericardial disease). The inclusion of echocardiographic findings in the diagnostic criteria of infectious endocarditis is only 1 simple example of the role that imaging techniques play in cardiovascular diagnosis.<sup>1</sup>

The zenith of cardiovascular imaging during the last decade has been achieved due to 3 basic factors. First, technical improvements have increased the ability to anatomically determine diagnosis by means of using imaging techniques that have, on one hand, overcome old limitations<sup>2</sup> and, on the other, opened new horizons.<sup>3,4</sup> Secondly, the irruption of functional imaging has allowed the use of these noninvasive techniques to evaluate functional aspects of circulatory hemodynamics as well as physiology and cardiovascular metabolism. In the field of ischemic cardiopathy, the functional image provides irreplaceable information for clinical and basic investigations, but it has also become indispensable for guiding the therapeutic approach to treating patients with heart disease in daily practice. Finally, the clinical efficacy of decisions based on imaging techniques, in terms of improved prognosis and avoiding mortality/morbidity, has been clearly demonstrated. If during the 1980s research on cardiovascular diagnosis was dedicated to demonstrating the precision of measurements obtained with imaging, at present its clinical usefulness per se has been definitively established.

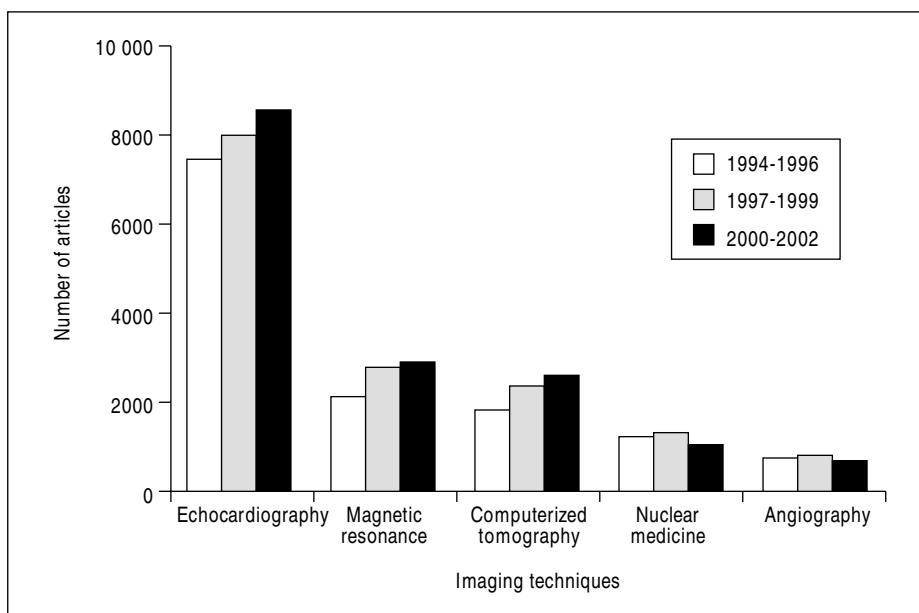
Analysis of references in the Medline database shows that diagnosis by imaging, in any of its modalities, comprises approximately 20% to 25% of the scientific articles on the circulatory system. On the other hand, approximately 15% of the articles about diagnosis by means of imaging are dedicated to the cardiovascular system. These percentages have remained at the same level over the years, despite expected

changes in the percentage of articles dedicated to each of these techniques (Figure 1). While this is a very rudimentary indication of the use of a resource in the healthcare setting, these data show the great weight of medical imaging in present-day cardiovascular studies.

As mentioned previously, the most clinically relevant studies on cardiac imaging published in recent years have been dedicated to demonstrating the therapeutic, prognostic, and social effect of these techniques.<sup>5</sup> These epigraphs refer to concepts such as the percentage of cases in which the results of an imaging technique have changed a therapeutic approach, avoided mortality/morbidity, improved quality of life, or changed the cost-to-benefit ratio of medicine from a social perspective. It is obvious that such aspects are of interest not only to the specialists charged with performing diagnostic tests, but also to any physician dedicated to the treatment of cardiovascular diseases.

From this perspective, the REVISTA ESPAÑOLA DE CARDIOLOGÍA is beginning a new «Update» section dedicated to diagnostic imaging techniques in cardiovascular medicine. We have used a different approach than the usual one to meet this goal, by selecting chapters that cover specific clinical problems. The aim is to update the information that imaging techniques can provide to the clinical cardiologist and to highlight the best approach for the indication and interpretation of the tests with regard to a particular patient. To this end, we have given maximum weight to the aspects of clinical efficacy mentioned previously, in an attempt to simplify as much as possible the technical details of the various diagnostic modalities.

The method of establishing the diagnosis of a coronary illness in the patient with chest pain or left ventricular systolic dysfunction will be the object of a specific monograph. Similarly, we will review the current role of imaging techniques in prognostic categorization after acute myocardial infarct, as well as the evaluation of myocardial viability in the patient who is a candidate for coronary revascularization. In recent years, the limitations of coronary angiography in establishing the clinical relevance of coronary lesions in certain situations have been revealed. In these cases, treatment decisions must be based on complementary



**Fig. 1.** Number of articles on diagnostic cardiovascular imaging published in the last 3 trienniums. Data obtained from Medline from the key words (MESH) «cardiovascular system» and each of the imaging techniques.

imaging techniques, which will be the subject of another chapter. We will dedicate individual articles to making therapeutic decisions about patients with suspected acute aortic syndrome or pericardial illness. The diagnosis of left ventricular systolic dysfunction requires, today, the incontrovertible evidence of relaxation anomalies or ventricular compliance that require the use of imaging techniques. Consequently, the diagnosis of and therapeutic approach to diastolic dysfunction will be addressed in another chapter. The adult patient with congenital cardiopathy is a frequent source of diagnostic and therapeutic uncertainty; an assured treatment approach depends in great measure on adequate indication for and interpretation of images. The evaluation of cardiac valve disease is the most illustrative example of the replacement of cardiac catheterization by imaging techniques, typically echocardiography. Nevertheless, the limitations and real clinical value of this technique for various valvulopathies have undergone important changes in recent years. Similarly, magnetic resonance and computerized axial tomography (CAT) have been shown to offer very valuable information about specific valvulopathy. Finally, the evaluation of a patient with ischemia or cerebral infarct requires a multidisciplinary approach in which imaging techniques have a determining role in therapeutic decisions. Each of these themes will be the subject of review in the current «Update.»

For authorship of the articles we are counting on the contribution of authorities whose expertise will be obvious in the quality of the articles provided. The single focus of these «Updates» required an enormous amount of review, analysis, integration, reflection, and synthesis in order to satisfy the proposed objectives. We are grateful to the authors for the effort behind each of the contributions in this series, and we hope that the readers of the REVISTA ESPAÑOLA DE CARDIOLOGÍA find them interesting and, above all, useful.

## REFERENCES

1. Durack DT, Lukes AS, Bright DK. New criteria for diagnosis of infective endocarditis: utilization of specific echocardiographic findings. Duke Endocarditis Service. *Am J Med* 1994;96:200-9.
2. Caidahl K, Kazzam E, Lidberg J, Neumann Andersen G, Nordanstig J, Rantapää Dahlqvist S, et al. New concept in echocardiography: harmonic imaging of tissue without use of contrast agent. *Lancet* 1998;352:1264-70.
3. Kim WY, Danias PG, Stuber M, Flamm SD, Plein S, Nagel E, et al. Coronary magnetic resonance angiography for the detection of coronary stenoses. *N Engl J Med* 2001;345:1863-9.
4. Achenbach S, Moshage W, Ropers D, Nossen J, Daniel WG. Value of electron-beam computed tomography for the noninvasive detection of high-grade coronary-artery stenoses and occlusions. *N Engl J Med* 1998;339:1964-71.
5. Fryback DG, Thornbury JR. The efficacy of diagnostic imaging. *Med Decis Making* 1991;11:88-94.