

UPDATE

Clinical Decision Making Based on Cardiac Diagnostic Imaging Techniques (IX)

Image Techniques for the Evaluation and Clinical Decision Making of Patients With Stroke

Miguel A. García Fernández, Javier Bermejo, and Mar Moreno

Sección de Cardiología no Invasiva, Laboratorio de Ecocardiografía, Hospital General Universitario Gregorio Marañón, Madrid, Spain.

The clinical relevance of cardiac embolism a potential cause of stroke is progressively increasing, mainly due to the recent progress in diagnostic imaging. In the present paper, we update and review the state of the art of the different etiologies currently accepted of a cardiac source of stroke. Furthermore, we review the clinical role of different image techniques, emphasizing the doubts and realities of each particular approximation.

Key words: Stroke. Cardiac embolism. Image techniques. Echocardiography. Magnetic resonance. Computerized tomography.

Full English text available at: www.revespcardiol.org

Utilidad de las técnicas de imagen en la valoración etiológica y toma de decisiones en el paciente con ictus

La embolia cardíaca como mecanismo etiológico del ictus ha adquirido cada vez más relevancia clínica, fundamentalmente por el importante avance en las técnicas de diagnóstico por imagen producido en los últimos años. En este artículo hacemos una revisión y puesta al día de la etiología que puede generar el corazón como origen de fuente embólica. Igualmente, hacemos una revisión del valor que tienen para el clínico las distintas opciones diagnósticas, así como las dudas y realidades de las diferentes aproximaciones terapéuticas

Palabras clave: Ictus. Embolia cardíaca. Técnicas de imagen. Ecocardiografía. Resonancia magnética. Tomografía computarizada.

INTRODUCTION

The frequency of stroke and its associated mortality have decreased over the last 25 years in most developed nations. However, cerebrovascular disease is the third leading cause of death in Spain and the most frequent cause of death among women.¹ The prevalence of the disease is nearly 7000 cases per 100 000 persons older than 64 years.² The prevention and correct treatment of patients with stroke and its complications thus have important repercussions, not only for the patients themselves but also for their families, health services and society in general.

Section sponsored by Laboratorio Dr. Esteve

Correspondence: Dr. M.A. García Fernández.
Sección de Cardiología no Invasiva. Laboratorio de Ecocardiografía.
Hospital General Universitario Gregorio Marañón.
Dr. Esquerdo, 43. 28007 Madrid. España.
E-mail: Magfeco@primustel.es

BASIC CONCEPTS OF STROKE FOR THE CARDIOLOGIST

Generally speaking, cerebrovascular diseases are caused by damage to the cerebral circulation resulting in a transitory or permanent change in brain function. These disorders, which can be grouped according to their overall pathological mechanism, have different clinical repercussions (Figure 1).

Ischemic stroke

Ischemic stroke is the result of a quantitative or qualitative reduction in blood supply to the brain. Ischemic stroke in a localized area of the brain is usually divided into two broad groups:^{3,4}

1. Transient ischemic attack (TIA). This is a focal or monocular dysfunction of the brain secondary to a thrombotic event or arterial embolism, with symptoms lasting less than 24 hours. There are four large subgroups of TIA, depending on the symptoms: retinal, lacunar, hemispheric and atypical. A topographical classification of the vascular territory affected makes it

ABBREVIATIONS

TIA: transient ischemic attack.
 ASA: atrial septal aneurysm.
 TCD: transcranial Doppler.
 TEE: transesophageal echocardiography.
 TTE: transthoracic echocardiography.
 PFO: patent foramen ovale.
 MRI: magnetic resonance imaging.
 CT: computerized tomography.

possible to distinguish between carotid, vertebrobasilar or indeterminate involvement.

2. Cerebral infarction. This involves a change in blood supply to a territory of the brain, and symptoms last longer than 24 hours. There are five subtypes with important clinical implications:

_ Atherothrombotic infarction: this is usually a medium-sized or large infarction with a cortical or subcortical topography and arising in carotid or vertebrobasilar vessels. A basic indicator of atherothrombotic infarction is that the patient suffers arteriosclerosis; this results in symptoms of peripheral vascular disease, alterations in the coronary vessels, and either occlusion or stenosis of the cerebral arteries.

_ Cardioembolic infarction: this is a medium-sized or large infarction with a cortical topography. The *only* known cause is emboligenic heart disease.

_ Lacunar infarction: this is a small infarction in patients with a history of hypertension or other risk factors. The infarction is localized to the territory of a cerebral perforant artery and is accompanied by lacunar syndrome. This presents as a pure sensory syndrome, ataxic hemiparesis and clumsy hand syndrome, a motor sensory syndrome or pure motor hemiparesis.

_ Infarction of unusual cause: this is an infarction in which the first three causes are all ruled out. Its origin is related with numerous systemic diseases, including neoplasia, myeloproliferative syndromes, coagulation disorders, connective tissue disorders and infections. The infarction can be of any size, and be localized cortically or subcortically in a carotid or vertebrobasilar territory.

_ Cerebral infarction of indeterminate origin: this is the catch-all term for all those cases not included in the previous groups.

Hemorrhagic stroke

This type of stroke is related with a hemorrhage in the cranial cavity secondary to extravasation from a ruptured blood vessel. Hemorrhagic strokes account for 20%-25% of all strokes. They are most commonly related with hypertension, followed by arteriovenous malformations, aneurysms, use of anticoagulants, hematological disease and use of drugs such as cocaine and alcohol.

IMAGING TECHNIQUES FOR EVALUATION OF PATIENTS WITH STROKE

A patient with suspected stroke undergoes a battery of diagnostic tests to provide a definitive diagnosis

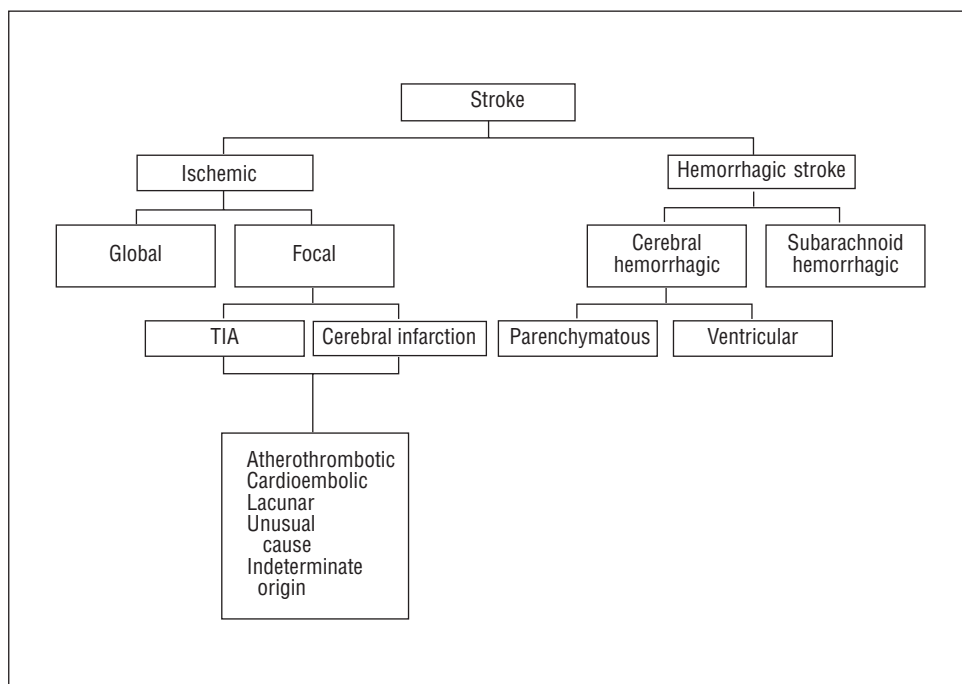


Fig. 1. Pathological classification of stroke. TIA: transient ischemic attack. Adapted from Diez Tejedor E, et al.⁴

TABLE 1. Immediate tests in patient with stroke

Central cT without contrast
Electrocardiogram
Chest x-ray
Blood workup
Coagulation test
Glycemia
Electrolytes
Spinal x-ray if the patient fails to respond and the possibility of trauma exists
Blood gasses if there are data suggestive of hypoxemia
Lumbar puncture if subarachnoid hemorrhage is suspected

CT indicates computerized tomography.

TABLE 2. Major indications for transesophageal echocardiography

-
1. Prosthetic heart valve
 2. Patient younger than 50 years with stroke
 3. Rheumatic mitral stenosis with stroke
 4. Suspected paradoxical embolism
 5. Poor window with suspected heart embolism
 6. Transesophageal echocardiography with diagnostic uncertainty
 7. Repeated stroke

A. Other indications for transesophageal echocardiography

1. Emboligenic atrial fibrillation
2. Suspected aortic arteriosclerosis
3. Mitral valve lesion

B. Indication for transthoracic echocardiography

Any patient with suspected cardioembolic stroke

TABLE 3. Etiology of cerebral embolism

Atrial fibrillation
Left ventricle
Acute myocardial infarction
Dilated cardiomyopathy
Mural thrombus
Ventricular aneurysm
Left atrium
Interventricular septal aneurysm
Interatrial communication
Patent foramen ovale
Atrial thrombus
Myxoma
Left atrial thrombus
Valve lesions
Mitral valve rheumatic disease
Mitral valve prolapse
Infectious endocarditis
Non-bacterial endocarditis
Libman-Sacks endocarditis
Valve prosthesis
Fibroelastic
Valve calcifications
Mitral ring calcification
Antiphospholipid syndrome
Procedure
Catheterization
Bypass surgery
Angioplasty
Valvuloplasty
Intra-aortic balloon
Heart transplant

and information regarding severity and prognosis, as well as the result of any treatment options (Tables 2 and 3).

Imaging techniques have revolutionized the evaluation of patients with stroke. These techniques can be grouped under three main headings:

1. Neuroimaging techniques.
2. Cardiac imaging techniques: cardiac embolism
3. Doppler echocardiography of the supra-aortic trunk and transcranial Doppler.

Neuroimaging techniques

Evaluation of the cerebral anatomy is fundamental in patients with stroke, not only to establish a topographic diagnosis of the lesion, but also to define the origin, reach a differential diagnosis and distinguish between non-reversible areas and areas with a chance of recovery. Many methods are available to evaluate these patients:

Computerized tomography (CT)

Undoubtedly, CT is the most widely used technique

to study patients with stroke; it should be done systematically and as soon as possible. The main advantage of CT is its high specificity for the differential diagnosis between ischemic and hemorrhagic stroke. However, its sensitivity for the early detection of ischemic tissue is low, and up to 60% of patients have a strictly normal cranial CT during the initial hours after a stroke.

Cranial magnetic resonance imaging (MRI)

Conventional MRI offers no real advantages over cranial CT for the detection of cerebral infarction. Bryan⁵ showed that during the first three hours after an ischemic stroke there is no difference between conventional MRI and CT without contrast. However, the new MRI diffusion techniques seem superior during the early stage of ischemia. Alterations in diffusion can be detected less than one hour after occlusion of the middle cerebral artery.^{6,7} The sensitivity and specificity of these techniques in acute stroke are almost 100%^{8,9} and diagnostic errors occur mostly in small lacunar lesions in the brain stem. Modern MRI techniques with injection of paramagnetic contrast agents

provide information about the intravascular space and enable the state of cerebral perfusion to be directly and dynamically evaluated. Magnetic resonance perfusion studies afford greater sensitivity in the early detection of ischemia. The combination of diffusion and perfusion studies gives very useful hemodynamic information to evaluate the therapeutic results of fibrinolysis versus neuroprotective agents.

Cardiac imaging techniques: cardiac embolism

Transthoracic echocardiography (TTE), and more especially transesophageal echocardiography (TEE), play a basic role in the search for the cardiac embolism causing the stroke. Their systematic use in the evaluation of patients with stroke has led to the understanding of the actual meaning of old etiologies which were traditionally considered to be the origin of the embolic source, as well as to the recognition of new causes, some with important clinical implications and of great interest to the cardiologist (Table 1). This review will make special mention of those causes of stroke for which echocardiographic study is essential:

Valve calcification

Radiographic techniques were the first to show the presence of valve calcifications in vivo. Fluoroscopy with field amplification is able to disclose calcium deposits on the valves or valvular rings.¹⁰ Likewise, CT and cine-CT are highly sensitive techniques for the visualization of calcifications.¹¹ Echocardiography, however, is the technique of choice because it makes it possible to localize the calcium in the aortic sigmoid valves or the mitral valve and ring, as well as providing clear definition of its extent.

Much controversy exists concerning the mechanism by which intracardiac calcium may be the cause of embolism. Embolization of calcified material is unusual, though cases have been reported in the cerebral vascular tree, and in peripheral and even in coronary embolisms.¹²⁻¹⁵ The embolism is most likely related with platelet activation and fibrin deposits on the irregular surface of the calcium in contact with the bloodstream.¹⁶

The classic study by Nair¹⁷ found stroke in 10% of the patients with mitral ring calcification and only 2% of 101 age- and sex-matched controls.¹⁸ Likewise, in a study of persons older than 80 years of age, 20% of a group of more than 500 patients with mitral ring calcification had had peripheral thromboembolism versus 12% of the control group. In the BAATAF study, after 28 months of follow-up, 7.8% of the patients with calcifications had embolic events, compared with 1.7% of the control group.¹⁹ Consideration should be given to associated factors which might introduce errors

when evaluating the results. Atrial fibrillation has been shown to be more common in patients with mitral ring calcification, and this could be the real cause of the stroke.^{20,18} Nevertheless, the Framingham study showed the incidence of stroke to be significantly higher in patients with ring calcification.²¹ After adjusting for variables such as sex, age, diabetes and atrial fibrillation, the relative risk was twice as high in patients with calcium.

No study has yet shown any therapeutic benefit in patients with mitral ring calcification. Its diagnosis, therefore, should not lead to a change in therapy.

Strands

Strands, which are 5-to-10-mm-long, thin, mobile, filamentous attachments, are usually situated on the atrial surface of the mitral valve, though they may also be detected on the aortic valve, especially on the ventricular surface, and on artificial heart valves. Magarey first described these structures in 1949 after an exhaustive analysis of more than 250 specimens. He defined them as endothelialized fibrin deposits in the area of leaflet coaptation, probably related with increased stress in areas of maximum valvular tension.²²

Transesophageal echocardiography is the diagnostic technique of choice. All care should be taken, and the study should be undertaken with multiplanar esophageal imaging to provide an exhaustive study of the valve (Figure 1). Diagnostic problems may occasionally arise in patients with suspected endocarditis; the vegetations are usually thicker and irregular, although it is often not possible to make a definitive diagnosis.

The presence of strands in the left heart has sometimes been related with an increased risk of stroke.^{23,24} However, long-term follow-up studies of patients with an incidental TEE finding of strands show the four-year probability of stroke to be very low—less than 1%.²⁴ Furthermore, Cohen confirmed that the presence of strands in older patients does not increase the risk of stroke.²⁴ Although strands occasionally disappear after treatment with dipyridamole,²⁵ the requirement for prophylactic therapy in patients with strands and stroke has not yet been established, nor has the most appropriate treatment, i.e., anticoagulation versus antiplatelet agents.

Spontaneous echocardiographic contrast

In 1983 our group first described the finding, with TTE, of intracavitary echogenic images in the left atrium of patients with mitral valve disease.^{26,27} With the advent of TEE and higher frequency probes (5 MHz), spontaneous contrast has become a much more frequent finding, seen in 30%-70% of patients with mitral stenosis in atrial fibrillation. The technique cu-

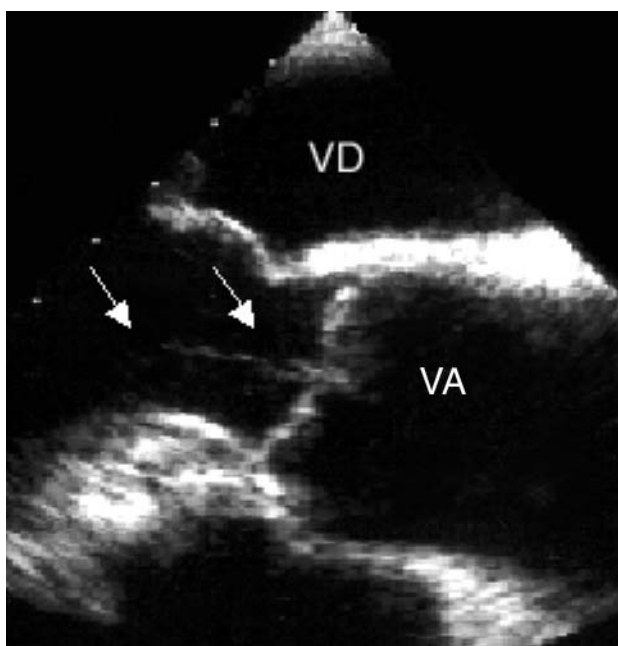


Fig. 2. Strand on the ventricular surface of the aortic valve (arrows). RV indicates right ventricle; AV, aortic valve.

rently used for the detection and evaluation of spontaneous contrast is TEE, particularly with high frequency probes (Figure 2). The prevalence of spontaneous contrast in the left atrium is 19%-59%, depending on the series and clinical circumstances of the patients.²⁸⁻³¹ Factors related with the presence of spontaneous contrast include atrial fibrillation, left ventricular dilatation and reduced left atrial flow.

Spontaneous contrast in the left atrium occurs in 30%-70% of the patients with mitral stenosis, and its frequency is directly related with the severity of stenosis. Spontaneous contrast in the left atrium is found in about 25% of the patients with non-rheumatic atrial fibrillation and in 50% of those with rheumatic atrial fibrillation.^{28,31} Although the association of spontaneous contrast in the left atrium with atrial flutter is less frequent than its association with atrial fibrillation, its finding on echocardiography is not uncommon in patients with atrial flutter. Irani, for example, reported an incidence of 26%.³² The presence of mitral incompetence appears to be associated with a lower prevalence of spontaneous contrast in the left atrium.^{33,34}

The association in the left atrium of spontaneous contrast and thrombi has been widely reported.^{26,27,35-37} From 29% to 60% of the patients with spontaneous contrast in the left atrium also have thrombi in this chamber,^{35,31} and about 80% of the patients with thrombi in the left atrium also have spontaneous contrast in this chamber.^{32,38} Spontaneous contrast in the left atrium is associated with a greater incidence of stroke and other acute arterial embolisms, especially in the presence of other conditions such as left atrial dilata-

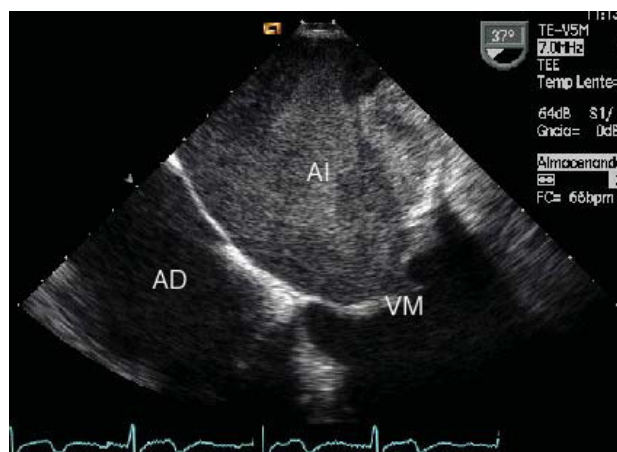


Fig. 3. Transesophageal echocardiography in a patient with mitral stenosis. The left atrium is full of spontaneous contrast. RA indicates right atrium; MV, mitral valve; LA, left atrium.

tion, and particularly, atrial fibrillation.³⁹⁻⁴¹ This occurs not only in patients with mitral valve disorders, but is also seen in other situations. Shen et al, used TEE to study 86 patients with dilated cardiomyopathy and reported that 36 (42%) had intracavitary spontaneous contrast, located in the left atrium in 35.⁴² The presence of spontaneous contrast in this study was related with a greater prevalence of intracavitary thrombi and with a higher incidence of stroke. Leung et al, who used TEE to study 272 patients with non-rheumatic atrial fibrillation, found spontaneous contrast in the left atrium in 161 (59%).⁴³ After 17.5 months of follow-up, the annual incidence of stroke or other type of acute arterial embolism was 12% in patients with spontaneous contrast in the left atrium. Long-term mortality was significantly higher in patients with spontaneous contrast. Indeed, the only independent risk factor for the occurrence of embolic events was the presence of spontaneous contrast in the left atrium.⁴³

Despite the relation between spontaneous contrast in the left atrium, the formation of atrial thrombi and the incidence of systemic thromboembolism, no studies have yet identified those patients in sinus rhythm with spontaneous contrast in the left atrium who might benefit from long-term anticoagulation therapy.

Aortic arch atheromas

The first clear evidence of an association between atheromatous plaques in the aorta and ischemic stroke was provided by Amarenco. In a series of 500 autopsy studies he found ulcerated plaques in 26% of the patients with stroke and only 5% of the control subjects. Because no echocardiographic study had been undertaken prior to death, the correlation between these findings and TTE was unknown. After the introduction of

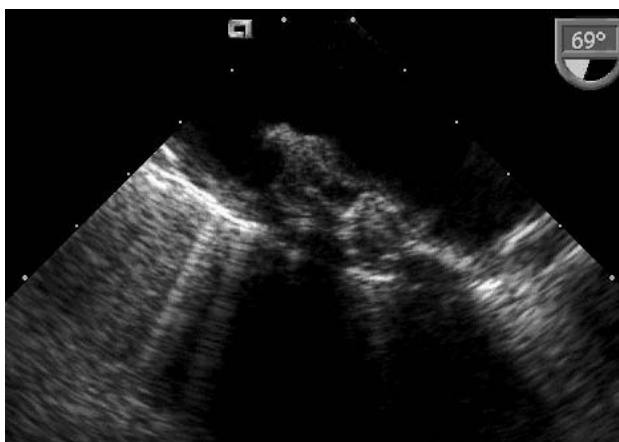

Fig. 4. Transesophageal echocardiography of the thoracic aorta in a patient with complicated ulcerated aortic plaque.

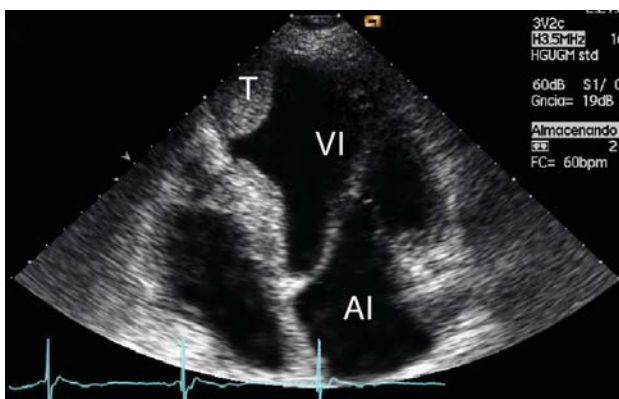


Fig. 5. Apical thrombus (T) in a left ventricle aneurysm after acute myocardial infarction. LA indicates left atrium; LV, left ventricle.

TEE (Figure 3), numerous studies have confirmed that the presence of an atheroma in the aortic arch is associated with a 3-to-9-fold higher risk of stroke.⁴⁴⁻⁴⁷ The greatest increase in risk is seen in patients in whom TEE shows morphologically complex plaques, with superimposed ulcerations and thrombi, which can result in up to a 17-fold increase in risk.⁴⁸ Results of the SPAF study suggest that once complex plaques are detected, anticoagulation with warfarin to maintain the INR between 2 and 3 is an alternative means of reducing embolic events.⁴⁹ Greater controversy surrounds the regimen for patients with stroke who have large, non-complicated plaques (>4 mm). Although such patients may benefit from anticoagulation with warfarin,⁴⁹ the most reasonable option is probably antiplatelet drugs and statins. Surprisingly, no controlled studies have yet defined the real role of antiplatelet agents in the prevention of events in patients with complicated plaques. Stern⁵⁰ suggested the use of endarterectomy to extract complicated atheromas. However, this procedure is associated with substantial morbidity and mortality, and it should be reserved for highly selected cases.

Ventricular thrombi

Transthoracic echocardiography is the diagnostic technique of choice for both acute myocardial infarction and for dilated cardiomyopathy; TEE is useful only in exceptional cases. Echocardiographically, a thrombus presents as a space-occupying mass in the ventricular cavity, with greater birefringence than the adjacent myocardium and usually situated in an area of poor contraction (Figure 4).

From 1% to 2.5% of the patients with acute myocardial infarction have a stroke, more than half within one week and the rest within one month. The risk remains relatively high for the first three months, and decreases thereafter. The causes of stroke within the context of infarction are well known. They include localization of the infarction (anterior infarctions are four times as likely to cause thrombi as inferior infarctions), the presence of accompanying atrial fibrillation, and ventricular dysfunction.

Echocardiography can be useful to establish anti-coagulation regimens in patients with acute myocardial infarction. In inferior infarctions, anticoagulation should be given if TTE shows the presence of thrombi. In anterior infarctions, anticoagulation should be given until TTE rules out the presence of an apical thrombus. Anticoagulation therapy should not exceed 6 months and the thrombus should be monitored for mobility, protrusion and size. Longer-term anticoagulation therapy is especially beneficial in patients with poor ventricular function. In the SAVE study, each 5% reduction in ejection fraction was associated with an 18% increase in the risk of stroke.⁵¹

In patients with dilated cardiomyopathy, the risk of peripheral vascular disease is from 2% to 4% per year, and TTE is again the diagnostic technique of choice to detect it. A clear relation exists between ejection fraction as measured by echocardiography and the risk of embolization. The SOLVD study⁵² linked this relation especially with female sex. No studies have yet been reported which evaluate the efficacy of anticoagulation in patients with dilated cardiomyopathy. However, if a thrombus is seen in the echocardiographic study, warfarin therapy should be given until serial studies demonstrate that it has disappeared.⁵³ The SAVE study⁵¹ showed the usefulness of preventive therapy with aspirin in the absence of echocardiographic evidence of thrombus, in patients who are in sinus rhythm and who have no history of embolization.

Infectious endocarditis

Peripheral embolism is one of the most common complications in patients with infectious endocarditis, although the actual incidence is difficult to establish because the embolism may often be subclinical. Autopsy studies have shown embolization rates in the

brain of up to 40%.⁵⁴ In our series, neurological alterations were the first sign in 33% of all patients,⁵⁵ although systemic embolization was only seen in 27%. The embolic accident usually occurs before a correct diagnosis is established. Thus, Steckelberg⁵⁶ reported that the appearance of embolic events declined with time after therapy was started, from 13 per 1000 patient-days during the first week of therapy to fewer than 1.2 per 1000 patient-days after the second week of therapy.

Together with microbiological studies, TEE is the main tool for diagnosing endocarditis (Figure 5). Attempts have been made to identify echocardiographic factors that might identify a subgroup of patients at high risk for peripheral embolization. The location of the vegetation may define one risk group, although not all studies concur. Rohmann et al⁵⁷ found that 25% of the patients with mitral involvement had peripheral embolism, versus only 9.7% of the patients with aortic endocarditis ($P<.05$). Likewise, the frequency of embolism increased when the vegetations involved the anterior mitral leaflet (37%). Others have reported similar results.⁵⁸ However, contradictory results also exist, such as those by the groups of Mügge and Weyman, who failed to find any relation between the location of the vegetations and the risk of embolization.^{59,60}

Vegetation size and mobility have received particular attention in studies related with the risk of embolization. However, varying results have been reported, probably due to the difficulty involved in standardizing the size of the vegetations and the use of different devices. General agreement exists, however, that vegetations larger than 10 mm are associated with a greater risk of thromboembolization. Heart surgery is indicated in patients with recurrent embolization, persistently positive cultures despite appropriate antibiotic therapy, heart failure and abscesses, and may be advised in patients with fungal endocarditis.

Atrial septal aneurysm

Atrial septal aneurysm (ASA) is a protrusion of the interatrial septum larger than 10 mm into either of the atrial chambers. Diagnosis is established at autopsy⁶¹ or by angiography.⁶² Clinically, TTE or TEE have now become the diagnostic techniques of choice (Figure 6) and it has been reported in up to 2.2% of all normal persons who undergo TEE.⁶³ Importantly, however, the odds of ASA in young patients with stroke were up to four times as great as in an age-matched control group.⁶³

Much controversy surrounds the reasons why ASA may cause peripheral emboli. It has been suggested that the aneurysm might be the site of formation of the thrombus. However, thrombi could only be detected within the aneurysm in 1% of a series of almost 200

patients with ASA.⁶⁴ Nevertheless, in many patients ASA is associated with other sources of embolism such as patent foramen ovale (PFO), atrial fibrillation or mitral valve prolapse, any of which might be the true cause of the embolic event.

The recent publication of the results of the PFO-ASA study have clarified certain diagnostic aspects and have important clinical repercussions.⁶⁵ A total of 581 patients with stroke of unknown origin were followed for four years. The risk of recurrent stroke was very low (2.3%) among the patients with PFO, moderate among the patients with both PFO and ASA (15.2%), and low among the patients with neither of these abnormalities (4.2%). No recurrences were seen among the patients with only ASA. Only the subgroup of patients with both PFO and ASA had a higher risk of recurrent stroke (4.2-fold increase). Aspirin is probably the treatment of choice in patients with either ASA or PFO. More aggressive therapy should be given to patients with both ASA and PFO diagnosed by TEE; such treatment might involve a combination of antiplatelet agents, oral anticoagulants or interventional closure of the PFO. Nevertheless, these alternative approaches should be evaluated in randomized trials.

Mitral valve prolapse

Although numerous studies have demonstrated the association between mitral valve prolapse and stroke, discrepancies exist as to the true value of this association. This is mainly because diagnostic criteria for mitral valve prolapse vary greatly, and because another cause of the thromboembolism may also be present in patients with mitral valve prolapse. Nishimura, in a longitudinal study of a large number of patients, found that 60% of those with stroke also had atrial fibrillation, thereby hindering determination of the direct cause of the mitral valve prolapse.⁶⁶

Given the low absolute risk of stroke and the controversies arising in its diagnosis, which complicates the reporting of results, the recommendation to give primary prophylactic treatment to patients with isolated mitral valve prolapse does not seem justified.

Patients with mitral valve prolapse who develop symptoms of retinal or cerebral ischemia could be considered for treatment with antiplatelet agents. Results from the SPAF study suggest that warfarin might be recommended for patients with mitral valve prolapse and significant left atrial dilatation or atrial arrhythmia, or both.⁶⁷

Patent foramen ovale

Evaluation of PFO is best done with TEE. Although Doppler color flow echocardiography reveals the presence of a shunt, peripheral intravenous injection via an arm vein and TEE is more sensitive for the detec-

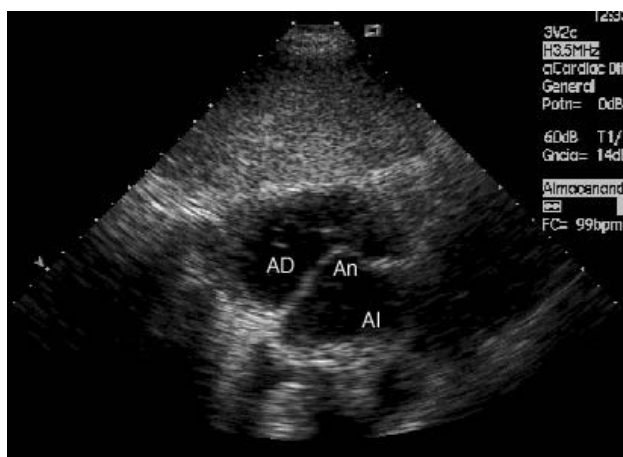


Fig. 6. Subcostal echocardiography shows the presence of an atrial septal aneurysm protruding into the right atrium (RA). LA indicates left atrium.

tion of minimal shunts. The study is undertaken under basal conditions following the Valsalva maneuver, which increases right atrial pressure and disclosed any interatrial shunts not present under normal basal conditions (Figure 7).

Transesophageal echocardiography has shown the incidence of PFO to be 3%-39%. Chen et al^{68,69} demonstrated that almost all patients with PFO undergoing surgery or catheterization were correctly identified with TEE. Detection of PFO is important because studies in patients with acute stroke and control subjects younger than 55 years of age showed PFO to be three times as common in patients with ischemic strokes as in the normal population.⁷⁰ Furthermore, the combined annual rate of recurrent acute stroke in patients with PFO is 3%.

The reasons why PFO may be responsible for stroke in a patient with suspected cardiac embolism remain controversial. The possibility of paradoxical embolism via the PFO has been suggested. However, this attractive hypothesis remains questionable, as pre-existing deep vein thrombosis is usually understood to be the origin of the paradoxical embolism. An increasing number of reports confirm that the rate of deep vein thrombosis, as well as pulmonary embolism, is very low in patients with PFO and acute stroke, indicating that in many cases this may not be the causative mechanism.⁷¹ Other possibilities include direct embolism of a thrombus arising in the abnormal part of the septum,⁷² cerebral ischemia related with a greater incidence of paroxysmal atrial fibrillation in these patients,⁷³ and the frequent association with ASA, which may be the true cause of the thromboembolism.^{74,75} The approaches to treatment are the same as for ASA.

Coagulation disorders

Of hypercoagulation states, the antiphospholipid

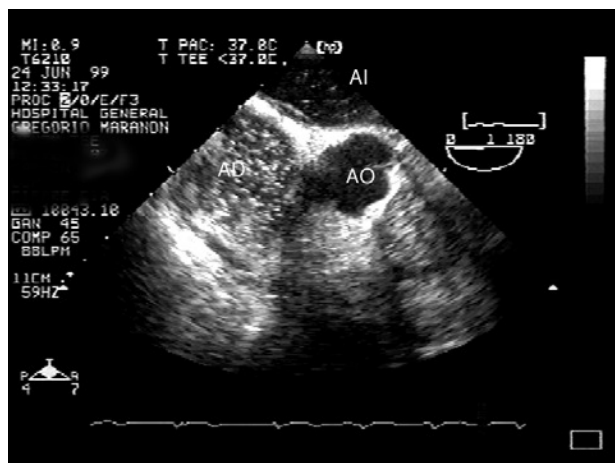


Fig. 7. Transesophageal echocardiography in a patient with patent foramen ovale. After injection, contrast material can be seen passing into the left atrium. RA indicates right atrium; AO, aorta; LA, left atrium.

syndrome is an example of a coagulation disorder associated with cardiac embolism and vascular thrombosis. Galve et al., one of the most active groups in the study this syndrome, reported mitral and aortic valve involvement in 38% of the patients with the primary antiphospholipid syndrome.⁷⁶⁻⁷⁹ The lesions are seen on echocardiography as localized thickening of the valve. Histologically, the lesion is composed of dense fibrous tissue with platelets and thrombi at the edges of the mass. Exceptionally, associated intracavitary thrombi with no other heart lesions are found (Figure 8).

The finding of antiphospholipid antibodies in the absence of symptoms does not indicate that the patient should be treated. Patients with symptoms of thrombosis or stroke probably require treatment with warfarin. Some authors recommend keeping the INR between 3 and 3.5.⁸⁰ In patients with an isolated PFO, no other specific therapy should be initiated than, hypothetically, profilaxis against endocarditis.

Doppler echocardiography of supra-aortic trunks and transcranial Doppler

Diagnosis and monitoring of stroke

Transcranial Doppler (TCD) has now become a basic complementary diagnostic technique in patients with stroke because it is able to detect intracranial stenosis. Correlation studies comparing TCD with invasive methods involving arteriography have reported very high rates of sensitivity and specificity for the diagnosis of intracranial stenosis.⁸¹ Transcranial Doppler enables diagnosis of acute occlusion by transtemporal analysis of mean cerebral artery flow compared with the contralateral artery. Follow-up after the stroke shows when arterial recanalization occurs, and whether it is spontaneous or due to throm-

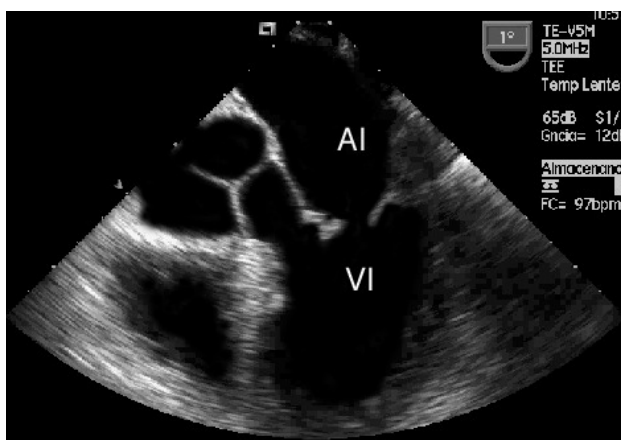


Fig. 8. Transesophageal echocardiography in a patient with the primary antiphospholipid syndrome. There is slight thickening of the free edge of the anterior mitral leaflet. LA indicates left atrium; LV, left ventricle.

bolysis. Demchuk⁸¹ recently established a classification of the degree of reperfusion according to the flow characteristics on TCD, and confirmed that it predicts severity, early recovery and death in patients treated with fibrinolysis. However, the tortuous anatomy of the basilar artery may sometimes limit the usefulness of TCD.

Study of patent foramen ovale

A very important alternative technique to TEE for the evaluation of PFO is detection of microcavitations in the cerebral circulation after peripheral intravenous injection of agitated saline solution. The signals detected are generated by microbubbles which produce a short, high intensity Doppler signal on interaction with the ultrasound waves. This signal is known as a high intensity transient signal (HITS). Serena et al⁸² showed that it is possible to evaluate the severity of the shunt through the foramen ovale, and more importantly, defined a group of patients at high risk for stroke. The magnitude of the shunt is determined by counting the number of Doppler signals detected in the middle cerebral artery. Large shunts include those with more than 25 signals (shower pattern) or uncountable signals (curtain pattern) (Figure 8). The presence of either of these two patterns is associated with an increased risk of stroke (odds ratio, 3.5), particularly in patients with cryptogenic stroke (odds ratio, 12). This important study clearly defines the usefulness of TCD as a complement to TEE for the study of patients with patent foramen ovale, and the clinical implications of this anomaly.

Doppler echocardiography of supra-aortic trunks

Almost 30% of the patients with stroke have carotid

disease. Thus far, coronary angiography has been the technique of choice to establish the severity of carotid disease and its therapeutic indications. The ECST⁸³ and NASCET⁸⁴ studies showed that surgical treatment is indicated for lesions larger than 75%-80%. Doppler echocardiography of the supra-aortic trunks shows not only the localization of the atheromatous plaque, but also its severity. The most commonly used parameter is maximum systolic velocity, which indicates more than 70% stenosis when flow velocity is greater than 215 cm/s. Almost half of all patients with TIA have carotid stenosis of less than 50%. In these patients it is necessary to evaluate the characteristics of the plaque and identify those patients whose alterations place them at high risk for arterial stroke.

Doppler monitoring of HITS has been described in patients with atrial fibrillation, artificial heart valves or intracranial stenosis, and during endarterectomy. Among patients with significant carotid disease HITS are more common in those with symptomatic carotid stenosis. They could, therefore, be an important marker of unstable plaque, thereby predicting the possibility of a clinical embolism.

DIAGNOSTIC PROCEDURES IN PATIENTS WITH ISCHEMIC STROKE

When a patient has symptoms of stroke, the first step is to determine whether it is ischemic or hemorrhagic in origin. This initial diagnosis conditions all subsequent decision-making and choice of therapy. Table 2 lists the tests which should be performed as soon as the patient reaches the hospital. Computed tomographic techniques are well standardized to distinguish between the two possible origins of the stroke, especially when we consider that the signs and symptoms between the two types largely overlap.

Once the type of stroke has been established, if the patient also has a suspected heart embolism there is no general agreement about when TTE or TEE should be performed. Our recommendations are given below (Table 3):

Indications for transthoracic echocardiography

Transthoracic echocardiography should be done in any patient with heart embolism, whether suspected or demonstrated by screening. By echocardiography and clinical examination we were usually able to diagnose from 8% to 10% of all patients; however, with the introduction of standard echocardiography this figure has risen to 15%-17%. This figure is still low, but it is nevertheless twice the figure when the technique is not used. Currently, echocardiography is a basic technique used systematically in clinical cardiology, and we do not believe that a low detection rate justifies its non-

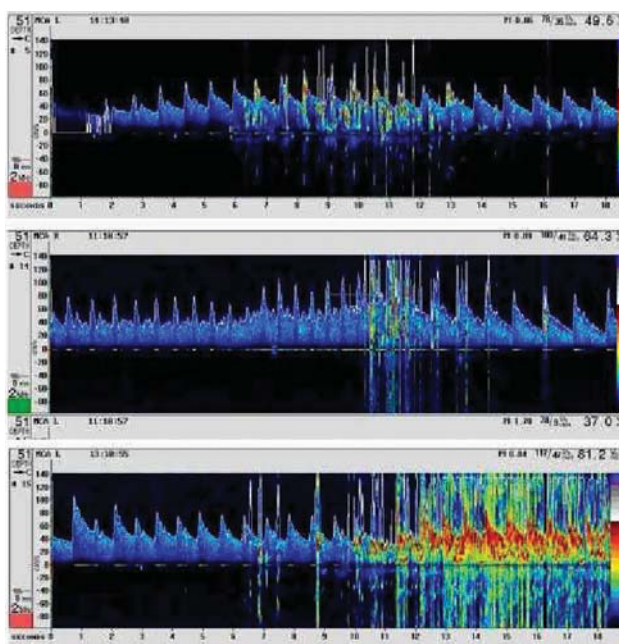


Fig. 9. Diagnosis of patent foramen ovale by Doppler study of the middle cerebral artery. Top: pattern suggesting more than a slight degree of shunting. Center: shower pattern. Bottom: curtain pattern.

use. In our experience, almost 25% of the patients with proven carotid disease also have a secondary embolic cause. Therefore, a positive finding after supra-aortic echocardiography does not make TTE unnecessary.

Major indications for transesophageal echocardiography

The most commonly indication for this examination is undoubtedly stroke in a young person. In these cases the search for a PFO requires the use of TEE, which is also needed in any patient with suspected paradoxical embolism. Transesophageal echocardiography should also be performed in any patient with an artificial heart valve and symptoms of stroke. Finally, TEE should be done in patients with suspected heart embolism in whom the findings with TTE are uncertain, or who has a poor window.

Other indications for transesophageal echocardiography

Transesophageal echocardiography should probably also be done in patients with stroke and mitral valve lesions or emboligenic atrial fibrillation, as well as in patients with stroke in whom aortic arteriosclerosis is strongly suspected. These latter patients should be examined for the presence of complicating atheromatous plaques.

CONCLUSION

Cerebrovascular stroke, especially cardioembolic stroke, requires the combination of different hospital specialties for its correct evaluation. Specifically designed stroke units should be created for this purpose. Collaboration between the echocardiography laboratory and the neurology department is fundamental to develop and implement protocols for the correct diagnosis and care of patients with neurological problems. The notable advances over recent years have led to the discovery of new causes and an understanding of their importance as sources of heart embolism. Nevertheless, despite these advances, doubts still surround the choice of the best treatment options, and further research is required in this fascinating field of diagnosis.

REFERENCES

1. Sudlow CLM, Warlow CP, for the international stroke incidence collaboration. Comparable studies of the incidence of stroke and its pathological types. Results from an international collaboration. *Stroke* 1997;28:491-9.
2. López-Pousa S, Vilalta J, Llinas J. Prevalencia de la enfermedad cerebrovascular en España: estudio en un área rural de Girona. *Rev Neurol* 1995;23:1081-6.
3. Arboix A, Álvarez-Sabín J, Soler L, en nombre del Comité de Redacción *ad hoc* del Grupo de estudio de Enfermedades Cerebrovasculares de la SEN. Ictus. Clasificación y criterios diagnósticos. *Neurología* 1998;13(Supl 3):3-10.
4. Díez Tejedor E, Soler R. Concepto y clasificación de las enfermedades cerebrovasculares. In: Castillo J, Álvarez-Sabín J, Martín-Vilalta JL, Martínez-Vila E, Matías-Guiu J, editors. *Manual de enfermedades vasculares cerebrales*. 2nd ed. Barcelona: Prous Science, 1999.
5. Bryan RN, Levy LM, Whitlow WD, Killian JM, Preziosi TJ, Rosario JA. Diagnosis of acute cerebral infarction: comparison of CT and MR imaging. *Am J Neuroradiol* 1991;12:611-20.
6. Warach S, Gaa J, Siewert B, Wielopolski P, Eleman RR. Acute human stroke studied by whole brain echo planar diffusion-weighted magnetic resonance imaging. *Ann Neurol* 1995;37:231-41.
7. Moseley ME, Cohen H, Kucharczyk J, Mintorovitch J, Hasegarty HS, Wndland MF, et al. Diffusion-weighted MR imaging of acute stroke; correlation with T2-weighted and magnetic susceptibility-enhanced MR imaging in cats. *Am J Neuroradiol* 1990;11: 423-9.

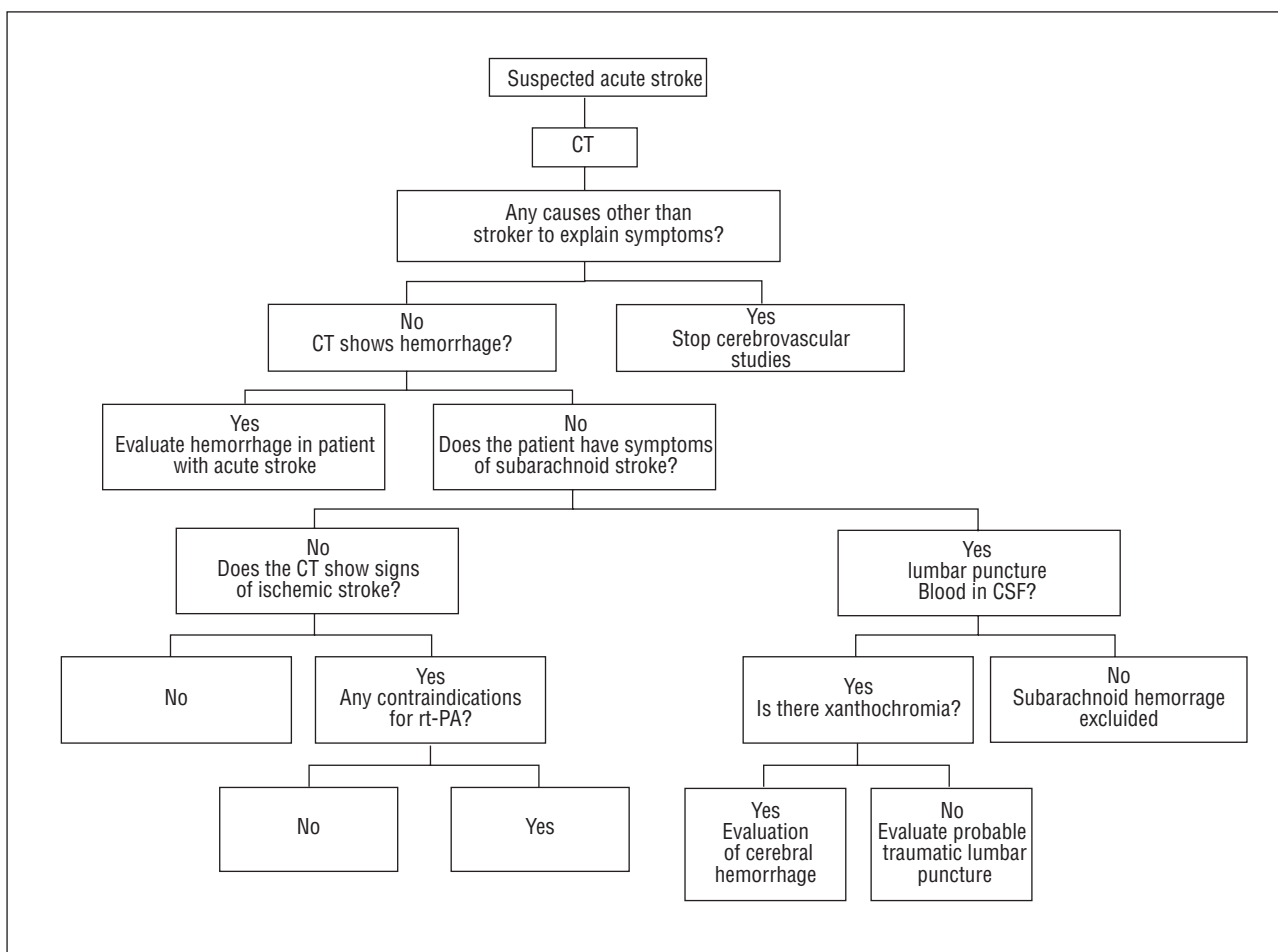


Fig. 10. Clinical management based on image techniques in patients with suspected stroke. CT indicates computerized tomography; CSF, fluid; rt-PA, recombinant tissue plasminogen.

8. Seega J, Elger B. Diffusion and T2-weighted imaging: evaluation of edema reduction in focal cerebral ischemia by the calcium and serotonin antagonist levopami. *Magn Reson Imag* 1993;11:401-9.
9. Lövblad KO, Laubah HJ, Baird AE, Curtin F, Xhlaug G, Edelman RR, et al. Clinical experience with diffusion-weighted MR in patients with acute stroke. *Am J Neuroradiol* 1998;19:1061-6.
10. Sosman MC, Wosika PH. Calcification in aortic mitral valves –with a report of twenty-three cases demonstrated *in vivo* by the roentgen ray. *Am J Roentgenol* 1933;30:328-48.
11. Kapila A, Hart R. Calcific cerebral emboli and aortic stenosis: detection of computed tomography. *Stroke* 1986;17:619-21.
12. Holley KE, Bahn RC, McGoan DC, Mankin HT. Spontaneous calcific embolization associated with calcific aortic stenosis. *Circulation* 1963;27:197-202.
13. Ridolfi RL, Hutchins GM. Spontaneous calcific emboli from calcific mitral annulus fibrosus. *Arch Pathol Lab Med* 1976;100: 117-20.
14. Ranqurel G, Merrelle L, Vincent D, Catala M, Arzimanoglu A, Vacheron A. Spontaneous calcific cerebral embolus from a calcific aortic stenosis in a middle cerebral artery infarct. *Stroke* 1989;20:691-3.
15. O'Donoghue ME, Dangond F, Burger AJ, Soujanen JN, Zarich S, Tarsy D. Spontaneous calcific embolization to the supraclinoid internal carotid artery from a regurgitant bicuspid aortic valve. *Neurol* 1993;43:2715-7.
16. Suri R, Jersaty RM. Multiple coronary emboli from a calcified rheumatic aortic valve. *Circulation* 1994;90:623-4.
17. Nair CK, Sketch MH, Ahmed I, Thomson W, Ryschon K, Woodruff MP, et al. Calcific valvular aortic stenosis with and without mitral annular calcium. *Am J Cardiol* 1987;60:865-70.
18. Nair CK, Thomson W, Ryschon K, Cook C, Hec TT, Sketch MH. Long-term followup of patients with echocardiographically detected mitral annular calcium and comparison with age- and sex-matched

- control subjects. *Am J Cardiol* 1989;63:465-70.
19. BAATAF. The effect of low-dose warfarin on the risk of stroke in patients with nonrheumatic atrial fibrillation. *N Engl J Med* 1990;323:1505-11.
 20. Savage DD, Garrison RJ, Castelli WP, McNamara PM, Anderson SJ, Kannel WB, et al. Prevalence of submitral (anular) calcium and its correlates in a general population-based sample (the Framingham study). *Am J Cardiol* 1983;51:1375-8.
 21. Benjamin EJ, Plehn JF, D'Agostino RB, Belanger AJ, Comai K, Fuller DL, et al. Mitral annular calcification and the risk of stroke in an elderly cohort. *N Engl J Med* 1992;327:374-9.
 22. Magarey RR. On the mode of formation of Lambl's excrescences and their relation to chronic thickening of the mitral valve. *J Path Bact* 1949;61:203-8.
 23. Roberts JK, Omarali I, Di Tullio MR, Sciacca RR, Sacco RL, Homma S. Valvular strands and cerebral ischemia. Effect of demographics and strand characteristics. *Stroke* 1997;28:2185-8.
 24. Cohen A, Tzourio C, Chauvel C, Bertrand B, Crassard I, Bernard Y, et al. Mitral valve strands and the risk of ischemic stroke in elderly patients. The French Study of Aortic Plaques in Stroke (FAPS) Investigators. *Stroke* 1997;28:1574-8.
 25. Orsinelli DA, Pearson AC. Detection of prosthetic valve strands by transesophageal echocardiography: clinical significance in patients with suspected cardiac source of embolus [abstract]. *J Am Coll Cardiol* 1993;21:A218.
 26. García-Fernández MA, Moreno M, Banuelos F. 2-D echo for detecting blood stasis. *Circulation* 1983;67:1160-1.
 27. García-Fernández MA, Moreno M, Banuelos F. Two-dimensional echocardiographic identification of blood stasis in the left atrium. *Am Heart J* 1985;109:600-1.
 28. Torrecilla EG, García-Fernández MA, San Román D, Muñoz R, Palomo J, Delcán JL. Left atrial spontaneous echocardiographic contrast after heart transplantation. *Am J Cardiol* 1992;69:817-8.
 29. Beppu S, Nimura Y, Sakakibara H, Nagata S, Park YD, Izumi S. Smoke-like echo in the left atrial cavity in mitral valve disease: its features and significance. *J Am Coll Cardiol* 1985;6:744-9.
 30. Erbel R, Stern H, Ehrenthal W, Schreiner G, Treese N, Kramer G, et al. Detection of spontaneous echocardiographic contrast within the left atrium by transesophageal echocardiography: spontaneous echocardiographic contrast. *Clin Cardiol* 1986;9:245-52.
 31. Derumeaux G, Mouton-Schleifer D, Redonnet M, Bessou JP, Soyer R, Saoudi N, et al. Prevalence of intra-auricular thrombi detected by transesophageal echocardiography in patients with cardiac transplants. *Arch Mal Coeur Vaiss* 1994;87:1459-65.
 32. Irani WN, Grayburn PA, Afridi I. Prevalence of thrombus, spontaneous echo contrast, and atrial stunning in patients undergoing cardioversion of atrial flutter. A prospective study using transesophageal echocardiography. *Circulation* 1997;95:962-6.
 33. Mitusch R, Lange V, Stierle U, Maurer B, Sheikhzadek A. Transesophageal echocardiography determinants of embolisms in non rheumatic atrial fibrillation. *J Cardiol* 1995;11:27.
 34. Bonnefoy E, Perinetti M, Girard C, Robin J, Ninet J, Barthelet N, et al. Systematic transesophageal echocardiography during the postoperative first 24 hours after mitral valve replacement. *Arch Mal Coeur Vaiss* 1995;88:315-9.
 35. Castello R, Pearson AC, Labovitz AJ. Prevalence and clinical implications of atrial spontaneous contrast in patients undergoing transesophageal echocardiography. *Am J Cardiol* 1990;65:1149-53.
 36. Iliceto S, Antonielli G, Sorino M, Biasco G, Rizzon P. Dynamic intracavitary left atrial echoes in mitral stenosis. *Am J Cardiol* 1985;55:603-6.
 37. Lee TM, Su SF, Chien KL, Lin YJ, Chen WJ, Chen MF, et al. Left atrial spontaneous echo contrast in patients with permanent pacemakers. *Heart* 1997;78:262-7.
 38. Heppell RM, Berkin KE, McLenachan JM, Davies JA. Haemostatic and haemodynamic abnormalities associated with left atrial thrombosis in non-rheumatic atrial fibrillation. *Heart* 1997;77:407-11.
 39. Daniel WG, Nellessen U, Schroder E, Nonnast-Daniel B, Bednarski P, Nikutta P, et al. Left atrial spontaneous echo contrast in mitral valve disease: an indicator for an increased thromboembolic risk. *J Am Coll Cardiol* 1988;11:1204-11.
 40. Jones EF, Calafiore P, McNeil JJ, Tonkin AM, Donnan GA. Atrial fibrillation with left atrial spontaneous contrast detected by transesophageal echocardiography is a potent risk factor for stroke. *Am J Cardiol* 1996;78:425-9.
 41. Paemelaere JM, Sirinelli A, Dreyfus X, Maillard L, Pottier JM, Raynaud P. Transesophageal echocardiography and systemic ischemic incidences: 235 cases. *Rev Neurol (Paris)* 1996;152:27-31.
 42. Shen WF, Tribouilloy C, Rida Z, Peltier M, Choquet D, Rey JL, et al. Clinical significance of intracavitary spontaneous echo contrast in patients with dilated cardiomyopathy. *Cardiology* 1996;87:141-6.
 43. Leung DY, Black IW, Cranney GB, Hopkins AP, Walsh WF. Prognostic implications of left atrial spontaneous echo contrast in nonvalvular atrial fibrillation. *J Am Coll Cardiol* 1994;24:755-62.
 44. González-Torrecilla E, García-Fernández MA, Pérez-David E, Bermejo J, Moreno M, Delcán JL. Predictors of left atrial spontaneous echo contrast

- and thrombi in patients with mitral stenosis and atrial fibrillation. *Am J Cardiol* 2000;86:529-34.
45. Amarenco P, Cohen A, Tzourio C, Bertrand B, Hommel M, Besson G, et al. Atherosclerotic disease of the aortic arch and the risk of ischemic stroke. *N Engl J Med* 1994;331:1474-9.
 46. di Tullio MR, Sacco RL, Gersony D, Nayak H, Weslow RG, Kargman DE, et al. Aortic atheromas and acute ischemic stroke: a transesophageal echocardiographic study in an ethnically mixed population. *Neurology* 1996;46:1560-6.
 47. Tunick PA, Rosenzweig BP, Katz ES, Freedberg RS, Pérez JL, Kronzon I. High risk for vascular events in patients with protruding aortic atheromas: a prospective study. *J Am Coll Cardiol* 1994;23:1085-90.
 48. Di Tullio MR, Sacco RL, Savoia MT, Sciacca RR, Homma S. Aortic atheroma morphology and the risk of ischemic stroke in a multiethnic population. *Am Heart J* 2000;139:329-36.
 49. Ferrari E, Vidal R, Chevalier T, Baudouy M. Atherosclerosis of the thoracic aorta an aortic debris as a marker of poor prognosis: benefit of oral anticoagulants. *J Am Coll Cardiol* 1999;33:1317-22.
 50. Stern A, Tunick PA, Culliford AT, Lachmann J, Baumann FG, Kanchuger MS, et al. Protruding aortic arch atheromas: risk of stroke during heart surgery with and without aortic arch endarterectomy. *Am Heart J* 1999;138:746-52.
 51. Loh E, Sutton MS, Wun CC, Rouleau JL, Flaker GC, Gottlieb SS, et al. Ventricular dysfunction and the risk of stroke after myocardial infarction. *N Engl J Med* 1997;336:251-7.
 52. Dries DL, Rosenberg Y, Waclawiw M, Domanski M. Ejection fraction and risk of thromboembolic events in patients with systolic dysfunction and sinus rhythm: evidence for gender differences in the studies of left ventricular dysfunction trial. *J Am Coll Cardiol* 1997;29:1074-80.
 53. Koniaris LS, Goldhaber SZ. Anticoagulation in dilated cardiomyopathy. *J Am Coll Cardiol* 1998;31:745-8.
 54. Mehta AP, Dave KM, Kinare SG. Infective endocarditis. A survey of the past 50 years. *J Postgrad Med* 1978;24:40-9.
 55. Bouza E, Menasalvas A, Muñoz P, Vasallo FJ, Moreno M, García-Fernández MA. Infective endocarditis. A prospective study at the end of the twentieth century. New predisposing conditions, new etiologic agents, and still a high mortality. *Medicine* 2001; 80:298-307.
 56. Steckelberg JM, Murphy JG, Ballard D, Bailey K, Tajik AJ, Taliencio CP, et al. Emboli in infective endocarditis: the prognostic value of echocardiography. *Ann Intern Med* 1991;114:635-40.
 57. Rohmann S, Erbel R, Gorge G, Makowski T, Mohr-Kahaly S, Nixdorff U, et al. Clinical relevance of vegetation localization by transesophageal echocardiography in infective endocarditis. *Eur Heart J* 1992;12:446-52.
 58. Pruitt AA, Rubin RH, Karchmer AW, Duncan GW. Neurological complications of bacterial endocarditis. *Medicine* 1978;57:329-43.
 59. Mügge A, Daniel WG, Frank G, Lichtlen PR. Echocardiography in infective endocarditis: reassessment of prognostic implications of vegetation size determined by transthoracic and the transesophageal approach. *J Am Coll Cardiol* 1989;39:173-8.
 60. Sanfilippo AJ, Picard MH, Newell JB, Rosas E, Davidoff R, Thomas JD, et al. Echocardiographic assessment of patients with infectious endocarditis: prediction of risk for complications. *J Am Coll Cardiol* 1991;18:1191-9.
 61. Silver MD, Dorsy JS. Aneurysms of the septum primum in adults. *Arch Pathol Lab Med* 1978;102:62-5.
 62. Awan IH, Rice R, Moodie DS. Spontaneous closure of atrial septal defect with interatrial aneurysm formation. Documentation by noninvasive studies, including digital subtraction angiography. *Pediatr Cardiol* 1982;3:143-5.
 63. Agmon Y, Khandheria BK, Meissner I, Gentile F, Whisnant JP, Sicks JD, et al. Frequency of atrial septal aneurysms in patients with cerebral ischemic events. *Circulation* 1999;99: 1942-4.
 64. Mügge A, Daniel WG, Angermann C, Spes C, Khandheria BK, Kronzon I, et al. Atrial septal aneurysm in adult patients. A multicenter study using transthoracic and transesophageal echocardiography. *Circulation* 1995;91:2785-92.
 65. Mas JL, Arquizan C, Lamy C, Zuber M, Cabanes L, Derumeaux G, et al, for the Patent Foramen Ovale and Atrial Septal Aneurysm Study Group. Recurrent cerebrovascular events associated with patent foramen ovale, atrial septal aneurysm, or both. *N Engl J Med* 2001;345:1740-6.
 66. Nishimura RA, McGoon MD, Shub C, Miller FA Jr, Ilstrup DM, Tajik AJ. Echocardiographically documented mitral-valve prolapse: long-term follow-up of 237 patients. *N Engl J Med* 1985;313: 1305-9.
 67. Predictors of thromboembolism in atrial fibrillation: II. Echocardiographic features of patients at risk. The Stroke Prevention in Atrial Fibrillation Investigators. *Ann Intern Med* 1992;116:6-12.
 68. Chen WJ, Kuan P, Lien WP, Lin FY. Detection of patent foramen ovale by contrast transesophageal echocardiography. *Chest* 1992; 101:1515-20.
 69. Hagen PT, Scholz DG, Edwards WD. Incidence and size of patent foramen ovale during the first 10 decades of life: an autopsy study of 965 normal hearts. *Mayo Clin Proc* 1984;59:17-20.
 70. Overell JR, Bone I, Lees KR. Interatrial septal ab-

- normalities and stroke: a meta-analysis of case-control studies. *Neurology* 2000; 55:1172-9.
71. Ranoux D, Cohen A, Cabanes L, Amarenco P, Bousser MG, Mas JL. Patent foramen ovale: is stroke due to paradoxical embolism? *Stroke* 1993;24:31-4.
 72. Silver MD, Dorsey JS. Aneurysms of the septum primum in adults. *Arch Pathol Lab Med* 1978;102:62-5.
 73. Berthet K, Lavergne T, Cohen A, Guize L, Bousser MG, Le Heuzey JY, et al. Significant association of atrial vulnerability with atrial septal abnormalities in young patients with ischemic stroke of unknown cause. *Stroke* 2000;31:398-403.
 74. Cabanes L, Mas JL, Cohen A, Amarenco P, Cabanes PA, Oubary P, et al. Atrial septal aneurysm and patent foramen ovale as risk factors for cryptogenic stroke in patients less than 55 years of age. A study using transesophageal echocardiography. *Stroke* 1993;24:1865-73.
 75. Mas JL, Arquizan C, Lamy C, Zuber M, Cabanes L, Derumeaux G, et al. Recurrent cerebrovascular events associated with patent foramen ovale, atrial septal aneurysm, or both. *N Engl J Med* 2001;345:1740-6.
 76. Galve E, Ordi J, Barquinero J, Evangelista A, Vilardell M, Soler-Soler J. Valvular heart disease in the primary antiphospholipid syndrome. *Ann Intern Med* 1992;116:293-8.
 77. Galve E, Cadell-Riera J, Pigrau C, Permanyer-Miralda G, García del Castillo H, Soler-Soler J. Prevalence, morphologic types, and evolution in cardiac valvular disease in systemic lupus erythematosus. *N Engl J Med* 1988;319:817-23.
 78. Galve E, Ordi J, Candell-Riera J, Permanyer-Miralda G, Vilardell M, Soler-Soler J. Valvular heart disease in systemic lupus erythematosus. *N Engl J Med* 1989;320:740-1.
 79. Khamashta MA, Cervera R, Asherson RA, Font J, Gil A, Coltart DJ, et al. Association of antibodies against phospholipids with heart valve disease in systemic lupus erythematosus. *Lancet* 1990;335:1541-4.
 80. Asherson RA, Cervera R. Antiphospholipid antibodies and the heart. Lessons and pitfalls for the cardiologist. *Circulation* 1991; 84:920-3.
 81. Demchuk AM, Burgin WS, Christou I, Felberg RA, Barber PA, Hill MD, et al. Thrombolysis in brain ischemia (TIBI) transcranial Doppler flow grades predict clinical severity, early recovery, and mortality in patients treated with intravenous tissue plasminogen activator. *Stroke* 2001;32:89-93.
 82. Serena J, Segura T, Pérez-Ayuso MJ, Bassaganyas J, Molins A, Dávalos A. The need to quantify Right-to-Left shunt in acute ischemic. *Stroke* 1998;29:1322-8.
 83. European Carotid Surgery Trialists' Collaborative Group. Randomised trial of endarterectomy for recently symptomatic carotid stenosis: final results of the MRC European Carotid Surgery Trial (ECST). *Lancet* 1998;351:1379-87.
 84. North American Symptomatic Carotid Endarterectomy Trial Collaborators. Beneficial effect of carotid endarterectomy in symptomatic patients with high grade carotid stenosis. *N Engl J Med* 1991;325:445-53.