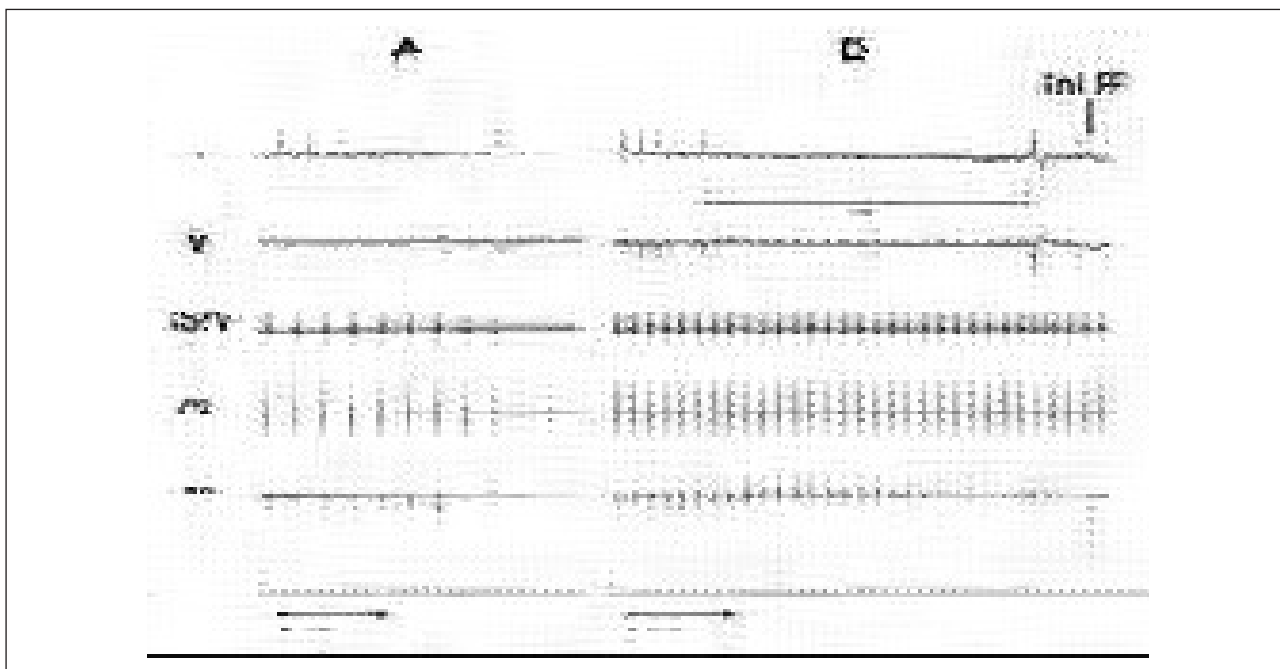


IMAGES IN CARDIOLOGY



Figure

Reflex Transient Atrioventricular Block During Atrial Fibrillation Ablation

A 55-year-old woman with a 5-year history of episodes of isolated atrial fibrillation (AF), refractory to various antiarrhythmic drugs, underwent a procedure to isolate the pulmonary veins. The 4 veins were mapped while brief episodes of AF were produced, and the suspected arrhythmogenic source was identified in the left superior pulmonary vein (LSPV). Figure 1 shows the recording in echocardiography leads I and V1, as well as the electrograms obtained in the LSPV, the coronary sinus (CS), and the ablation catheter (Abl) located in the LSPV ostium. Radiofrequency (RF) energy was applied during atrial stimulation from the CS (column A), with development of a high-grade atrioventricular (AV) block (column B), a transient reflex that caused syncope in the patient. The RF application was not interrupted until 2.7 s after the ventricular escape beat.

The mechanism of high-grade AV block is related to the production of vagal reflexes when energy is applied to some regions of the left atrium, mainly the posterior wall and the areas adjacent to the pulmonary veins, which contain numerous parasympathetic nerve endings. Elimination of parasympathetic innervation has been proposed as one of the possible mechanisms by which ablation of atrial fibrillation may be effective. In fact, the development of bradycardia and AV block has been associated with increased effectiveness of the ablation procedure in some series.

Miguel A. Arias, Rafael Peinado,
and José L. Merino

Unidad de Arritmias, Unidad Médico-Quirúrgica de Cardiología,
Hospital La Paz, Madrid, Spain.