

# Intracardiac Echocardiography and Percutaneous Closure of Atrial Septal Defects in Adults

Felipe Hernández, Julio García-Tejada, Maite Velázquez, Agustín Albarrán, Javier Andreu, and Juan Tascón

Unidad de Hemodinámica y Cardiología Intervencionista, Hospital 12 de Octubre, Madrid, Spain

**Introduction and objectives.** Today, the transcatheter treatment of atrial septal defects using an occluding device is a safe and effective therapeutic approach. Recently, intracardiac echocardiography has been developed as an alternative to transesophageal echocardiography for guiding these procedures. We describe our experience with intracardiac echocardiography during the percutaneous closure of atrial septal defects in adult patients.

**Methods.** This retrospective study involved 52 patients with atrial septal defects (77% with an ostium secundum defect and 23% with patent foramen ovale) who underwent transcatheter closure using an Amplatzer device under intracardiac echocardiographic guidance and without the need for general anesthesia or orotracheal intubation. Clinical follow-up was carried out at 24 hours, and 6 and 12 months, and with transthoracic echocardiography at 24 hours and 6 months.

**Results.** The procedure was successful in 51 (98%) of the 52 patients. No serious complication was recorded. Three patients suffered paroxysmal atrial fibrillation in the following weeks, which resolved with medical treatment. At 6 months, echocardiographic examination confirmed that there was no residual shunting across the atrial septum in any patient.

**Conclusions.** Intracardiac echocardiography provided accurate anatomical information about the atrial septum and other intracardiac structures. The technique's use during the transcatheter closure of atrial septal defects using an occluding device was straightforward. In addition, the procedure was less uncomfortable for patients than transesophageal echocardiography because there was no need for general anesthesia or orotracheal intubation.

**Key words:** Atrial septal defect. Echocardiography. Congenital heart disease. Cardiac catheterization. Imaging.

SEE EDITORIAL ON PAGES 451-3

Correspondence: Dr. F. Hernández.  
Unidad de Hemodinámica y Cardiología Intervencionista.  
Hospital 12 de Octubre.  
Avda Córdoba s/n. 28041 Madrid. España.  
E-mail: fherandezh@medynet.com

Received March 22, 2007.

Accepted for publication January 4, 2008.

## Ecocardiografía intracardiaca en el cierre percutáneo de defectos del septo interauricular en adultos

**Introducción y objetivos.** El tratamiento percutáneo de los defectos del septo interauricular mediante el implante de dispositivos oclusores es actualmente una realidad terapéutica eficaz y segura. La ecocardiografía intracardiaca como guía durante estos procedimientos es una alternativa novedosa frente a la ecocardiografía transesofágica. Se describe la experiencia con ecocardiografía intracardiaca en el cierre percutáneo de defectos del septo interauricular en pacientes adultos.

**Métodos.** Estudio retrospectivo de 52 pacientes con defectos del septo interauricular (el 77% con comunicación interauricular ostium secundum, el 23% con foramen oval permeable) tratados mediante cierre percutáneo con dispositivos Amplatzer guiado con ecocardiografía intracardiaca, sin necesidad de anestesia general ni intubación orotraqueal. Se realizó seguimiento clínico a las 24 h, a los 6 y a los 12 meses, y con ecocardiografía transthorácica a las 24 h y a los 6 meses.

**Resultados.** Se completó el procedimiento con éxito en 51 (98%) de los 52 pacientes. No hubo ninguna complicación grave; 3 pacientes presentaron crisis de fibrilación auricular paroxística en las semanas siguientes, pero se resolvieron con tratamiento médico. A los 6 meses el ecocardiograma confirmó la desaparición del cortocircuito a través del septo en todos los pacientes.

**Conclusiones.** La ecocardiografía intracardiaca proporciona excelente información anatómica del septo interauricular y otras estructuras intracardiacas. Su uso durante el implante percutáneo de dispositivos oclusores de defectos del septo interauricular es sencillo, y para el paciente resulta más confortable que el ecocardiograma transesofágico, pues se evita la anestesia general y la intubación orotraqueal.

**Palabras clave:** Comunicación interauricular. Ecocardiografía. Cardiopatías congénitas. Cateterismo cardiaco. Imagen.

## ABBREVIATIONS

AS: atrial septum  
ASD: atrial septal defect  
ASO: Amplatzer septal occluder  
ICE: intracardiac echocardiography  
PFO: patent foramen ovale  
TEE: transesophageal echocardiography

## INTRODUCTION

Transcatheter closure of atrial septal defects (ASD) is recognized as a safe, efficient alternative to medical treatment and surgical intervention.<sup>1-4</sup> Although surgery has been used for over 45 years and is considered the treatment of choice in patients with ostium secundum-type defects, nonsurgical ASD closure was first described as long ago as 1976.<sup>5</sup> Although safe and effective, surgery entails thoracotomy-associated complications such as hemorrhage, arrhythmia, and physical and psychological after-effects in relatively young patients.<sup>6,7</sup> Percutaneous occluding devices, previously of limited use for technical reasons, provide excellent alternative anatomic closure in adults today.<sup>8,9</sup>

In transcatheter ASD closure procedures, transesophageal echocardiography (TEE) is the standard imaging technique used to determine defect position and size, and guide intracardiac device implant procedures adequately.<sup>2-4,10</sup> However, in adult patients TEE involves sedation or general anesthesia with orotracheal intubation, prolonging the procedure and increasing its complexity. The recent development of intracardiac echocardiography (ICE) increases the range of imaging techniques available to the cardiologist and constitutes a further option for transcatheter closure intervention guidance.<sup>11</sup> Positioning the transducer in the right heart cavities offers excellent intracardiac anatomy definition. It has been used to guide transeptal needle puncture and in radiofrequency ablation procedures.<sup>12,13</sup> Intracardiac echocardiography is reported as useful and safe when performed in transcatheter ASD closure procedures because it eliminates the need for TEE and general anesthesia, reduces intervention time, and gives the interventional cardiologist control of imaging without needing additional echocardiographic equipment.<sup>11,14-19</sup>

The present article describes our experience and the results of occluding device implantation in adult patients with ASD, guided solely by ICE to measure the defect, select device size and confirm correct device positioning.

## METHODS

### Patients

From January 2002 to August 2006, 52 patients underwent transcatheter procedures for ASD closure (37 women and 15 men; age, mean [SD] [range], 39 [12] [22-74] years). Forty patients presented ostium secundum-type interatrial communication and 12 patent foramen ovale (PFO) with AS aneurysm. All patients had previously undergone TEE with a multiplane probe (Acuson Sequoia C-256, Siemens AG, Malvern, Pennsylvania, US) to confirm diagnosis, define the size, location, and number of ASD, and rule out other associated abnormalities (anomalous pulmonary vein drainage).

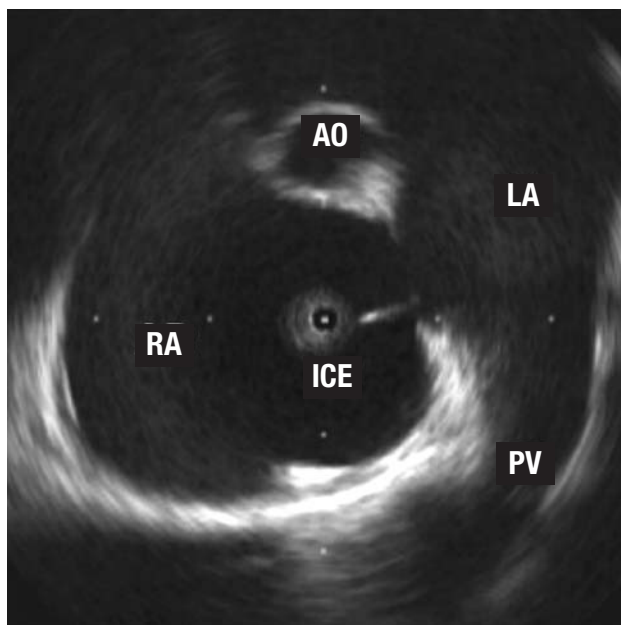
### ICE

Intracardiac echocardiography was with a single-use, 9F-9MHz Ultra ICE catheter (EP Technologies, Boston Scientific Corp, Natick, Massachusetts, US) connected to a Clear View Ultra console (Boston Scientific Corp). This consists of a 9 F catheter with a 9 MHz rotating ultrasound element mounted at the tip. This obtains 9 MHz fixed frequency images, with a 4 cm deep radial field of vision. It is limited to obtaining single plane (horizontal) images and does not have Doppler.<sup>20,21</sup>

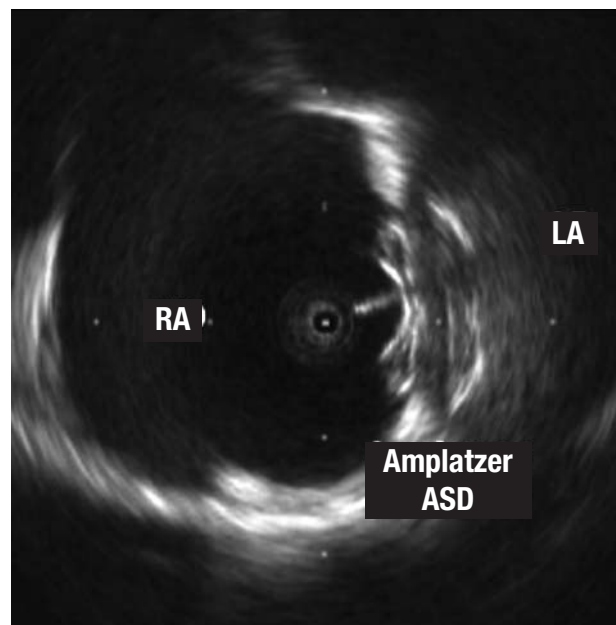
Under local anesthetic, the ICE catheter is introduced percutaneously using left femoral vein access with a 60 cm long, 55° precurved sheath (Convoy, Boston Scientific EP Technologies). The sheath tip is positioned in the right atrium (RA), and the transducer is manually maneuvered backwards and forwards with rotating movements. Standard planes are usually longitudinal, visualizing the 4 heart chambers—especially both atria and the AS—and transversal—at the level of the aortic valve plane.<sup>22</sup> Maximum defect diameter (in the ASD) is measured in both planes. Imaging confirms that correct device deployment captures the ASD rims before final release (Figures 1 and 2). We did not need stretching balloons to decide on implant device size.

### Devices

We used Amplatzer Septal Occluder (ASO) devices for ASD and Amplatzer Patent Foramen Ovale (PFO) Occluder devices for PFO (AGA Medical, Golden Valley, Minnesota, US). The self-centering device consists of a double disc of fine, Nitinol windings—one property of Nitinol is its thermal memory. The discs are connected by a 4 mm long waist, of 4-40 mm in diameter in the ASO; the left atrial disc is larger (14 mm more than the waist) than the right atrial disc (10 mm more than the waist). Both discs and waist contain polyester inserts that facilitate coagulation and defect occlusion. The device is screwed to the delivery wire transport cable and deployed thru a 6-12 F sheath positioned in the left atrium



**Figure 1.** Image of an ostium secundum-type, interatrial wall defect. The tip of the intracardiac echocardiography (ICE) catheter is in the right atrium (RA). You can also see a right superior pulmonary vein (PV) and tangential cut of the aorta (AO) in the anterior plane.



**Figure 2.** Image of the Amplatzer ASD device for atrial septal defects implanted in the septum. Note the larger size of the disc that remains in the left atrium (LA) and the echo of the cable connected to the disc in the right atrium (RA).

(LA) thru the ASD. A significant advantage of the device is that it can be recovered and repositioned as often as necessary prior to final release.

### Closure and Follow-up Protocol

Under local anesthetic, we obtained bilateral femoral vein access, left for ICE and right to advance a 0.035", 260 cm guide thru the defect to the left superior pulmonary vein, aided, when necessary, by a 6 F multiuse catheter. After examining the ASD by ICE in at least 2 orthogonal projections, we chose an ASD 1-2 mm larger than the maximum diameter measured. In PFO, all devices were 25 mm (right atrial disc diameter). After positioning the sheath in the LA and withdrawing the guide, we advanced the device selected, deploying the distal disc in the LA and the proximal disc in the RA with radioscopic and ICE control. We confirmed correct disc positioning by ICE and performed the push-pull "Minnesota wiggle" maneuver (drawing the device towards both atria without releasing it)<sup>4</sup> with a 30° left anterior oblique and 30° cranial tilt, before finally releasing the occluder.

All patients were receiving aspirin or clopidogrel; anticoagulation medication with intravenous sodium heparin at 100 U/kg was administered on initiating the procedure. We administered antibiotic prophylaxis with 1 g cephazolin on completing the procedure. We did not need TEE to visualize defects or decide on device size in any patient, so no one required general anesthesia or orotracheal intubation. Nor did we use the stretching

balloon to decide what size device to implant, in any patient.

We conducted transthoracic echocardiography in the first 24 h to confirm correct device positioning and the absence of potential complications (thrombus, pericardial bleeding). All patients were discharged without immediate complications and with a drug regimen of 100 mg aspirin or 75 mg clopidogrel (for patients in sinus rhythm), both drugs combined in patients with PFO, or aspirin plus oral anticoagulation (for patients in atrial fibrillation). We detected no vascular complications in femoral access (all venous except in 5 patients who also underwent diagnostic coronary angiography using femoral access during the procedure due to age and/or cardiovascular risk factors). At 6 months, patients underwent transthoracic echocardiography again; and at 6 and 12 months they attended clinical examination. This has since been repeated annually.

### Statistical Analysis

Quantitative variables are expressed as mean (SD) and as percentages when appropriate.

### RESULTS

Baseline and procedural data are summarized in Table. Devices were successfully implanted without immediate complications in 51 (98%) of the 52 patients. In 1 patient, ASD closure was not achieved as we were unable to

correctly position the device despite several attempts with 2 different sized ASOs. The patient was referred for elective surgery which was performed without complications. Two patients had a cribriform septum: 1 with large ASD and 2 other defects in close proximity which were covered with a single 30 mm ASO; the other, with PFO and AS aneurysm, received 2 PFO devices in separate procedures.

In 7 patients with ASD, pulmonary systolic pressure prior to closure was  $\geq 50$  mm Hg (50-88 mm Hg). Left-to-right shunt had been documented by TEE and bidirectional shunt with systemic desaturation in some of them. Neither systemic hypotension nor other complications occurred after device deployment and in some patients saturation increased immediately.

In 4 patients, the anterosuperior AS rim was minimal (<3 mm) but we managed to anchor the device with a certain amount of retroaortic support, without protruding into or denting the aortic wall. In 1 patient, the inferior rim was practically nonexistent and the defect large but a 28 mm device was successfully implanted without the LA disc interfering with anterior mitral valve movement. In these patients, we performed TEE at 6-month follow-up to rule out malpositioning or aortic erosion.

Mean follow-up was 28 (9) (10-66) months. We recorded no significant vascular complications, pericardial bleeding, systemic embolic phenomena, or device embolization during follow-up. In 3 patients, symptomatic paroxysmal atrial fibrillation was recorded in the first month after implantation. In the 3 patients, prophylactic oral anticoagulation was begun and beta-blockers added; no further incidence was recorded. At 3 months, both treatments were ended.

At 6 months, transthoracic echocardiography confirmed correct implant positioning and color Doppler indicated the absence of significant residual shunting in all patients. Antiplatelet treatment was halted in patients with ASD unless another clinical indication suggested it should be continued. In patients with PFO, 1 of the 2 antiplatelet drugs was withdrawn. Clinical follow-up at 12 months was normal.

## DISCUSSION

In the past, indication for ASD closure meant open-heart surgery was inevitable. Despite the benefits obtained, in adults, the serious complication rate is not inconsiderable (9%-13%).<sup>6,7,23,24</sup> The technological evolution of percutaneous devices, experience of interventional cardiologists dedicated to these pathologies, and innovations in imaging techniques make percutaneous treatment of these defects efficient, safe and attractive.<sup>11,14-22</sup>

Although TEE defines the AS adequately, its use during interventional procedures in the cardiac catheterization laboratory implies the participation of other professionals (anesthetists for sedation or general anesthesia of the patient, echocardiographers to manage TEE) and prolongs

## Baseline and Procedure Data<sup>a</sup>

Patients, n	52
Age, mean (SD), y	39 (12) (22-74)
Women	37 (71)
PFO	12 (23)
ASD	40 (77)
ASD + pulmonary systolic pressure $\geq 50$ mm Hg	7 (18)
ASD diameter by TEE, mm	18.1 (6-30)
ASD diameter by ICE, mm	20.2 (10.8-31.3)
Device diameter, mm	22 (12-34)
Radioscopy time, min	9.4 (6)
Procedure time, min	51 (17)
Procedure success rate	51 (98)

<sup>a</sup>ASD indicates atrial septal defects; ICE, intracardiac echocardiography; TEE, transesophageal echocardiography. PFO, patent foramen ovale. Data are expressed as n (%) or mean (SD) (range).

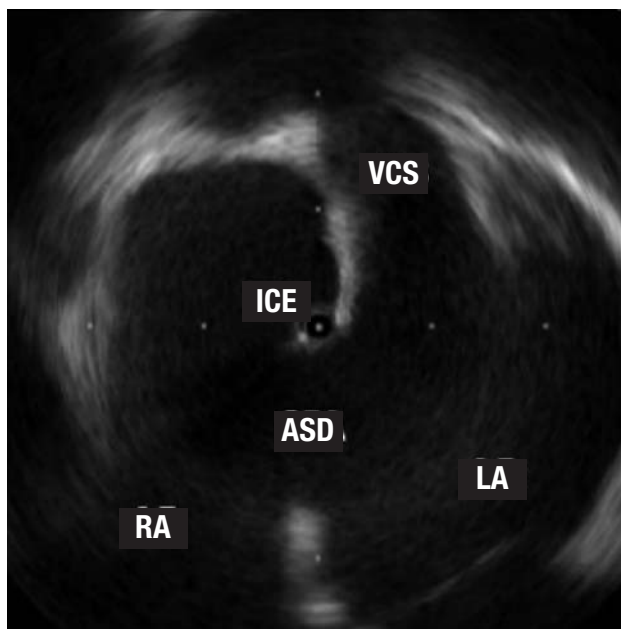
intervention times.<sup>11,17</sup> In our series, ICE use has successfully avoided the need for anesthesia and TEE in the catheterization laboratory, without diminishing the efficiency and safety of the procedure, and with the consequent comfort for patients.

The definition of intracardiac structures—especially the AS and adjacent structures—obtained by ICE is optimal (Figure 3).<sup>21</sup> The ease of use and, of course, the reliability of information obtained during the procedure mean ICE has taken the place of TEE. However, the catheters are not reusable and the increased cost this entails is a logical drawback. Furthermore, ICE use in pediatric patients is limited due to the catheter size (9 F), although series with similar but larger catheters (11 F) in patients weighing <15 kg and with mean age 3.1 years, have been reported.<sup>25</sup>

Discrepancies in ASD size on using 3 different references—TEE, ICE, and stretching balloon—are well-known.<sup>11,15</sup> Stretching balloon measurement—strongly defended by some teams—produces overstretching of the AS until a radiologic waist is visible in the balloon at the level of the defect, which is later measured to quantify its maximum diameter. It is frequently observed that ASD rims are extremely flimsy, and overstretching can magnify defect size and lead to choosing too large a device or generate complications like arrhythmias or pericardial bleeding.<sup>26,27</sup>

In our series, measures obtained by TEE provide defect diameters inferior to those obtained by ICE. Several possible justified of these findings exist:

- TEE may not always visualize rims clearly; inferior or posterior rims are better defined by ICE<sup>21,28</sup>
- ICE can be introduced into the defect and cross it towards the LA permitting the examination of defect geometry from the interior with more perspectives. Septal defects are not usually perfectly circular or symmetrical,



**Figure 3.** The tip of the intracardiac echocardiography (ICE) catheter is seen in the left atrium (LA) thru a large ostium secundum-type atrial septal defect (ASD). Note the vena cava superior (VCS) opening in the right atrium (RA).

and diameters can vary significantly according to the observation plane

Intracardiac echocardiography measures defects in 2 standard planes (longitudinal and transversal) and verification of landmark rims around defects provides enough reliable information to choose an adequately sized device, generally 1-2 mm greater than the maximum defect measurement, in order to ensure correct, firm deployment over the AS.<sup>28</sup>

Although numerous ASD closure devices are currently commercially available, Amplatzer occluders have proven more versatile and more efficient than other devices. They are easy to implant, can be retrieved in cases of malpositioning, and present a minimal complication rate: all this makes them the simplest and most efficient devices for the interventional cardiologist.<sup>28-31</sup> In our series, we found no serious complications (device embolization, erosion, systemic embolism), and in only 3 patients did we record paroxysmic atrial fibrillation in the weeks following; this responded to medical treatment. At 6 months, all patients were evaluated by transthoracic echocardiography and in selected patients (with very large devices or devices not centered in the AS) TEE was used. Although residual shunting thru the device is still documented in the first hours post-implantation (determined by color Doppler), the Amplatzer design, integrating polyester inserts on the interior, facilitates complete defect occlusion in the following weeks or months in practically all patients.<sup>31</sup>

## Limitations of the Study

This study is limited in that it deals with a single center, is retrospective, and reflects a small sample.

## CONCLUSIONS

In our experience, ICE provides excellent anatomic information on AS and nearby structures in patients with septal defects. The ease of use and added comfort for patients—avoiding sedation or general anesthesia with orotracheal intubation—make the technique an attractive, safe alternative to TEE during ASD occluding device implantation.

## REFERENCES

- Du ZD, Hijazi ZM, Kleinman CS, Silverman NH, Larntz K, for the Amplatzer Investigators. Comparison between transcatheter and surgical closure of secundum atrial septal defect in children and adults: results of a multicenter nonrandomized trial. *J Am Coll Cardiol.* 2002;39:1836-44.
- Masura J, Gavora P, Formanek A, Hijazi ZM. Transcatheter closure of secundum atrial septal defects using the new self-centering amplatzer septal occluder: initial human experience. *Cath Cardiovasc Diagn.* 1997;42:388-93.
- Fischer G, Stieh J, Uebing A, Hoffmann U, Morf G, Kramer HH. Experience with transcatheter closure of secundum atrial septal defects using the Amplatzer septal occluder: a single center study in 236 consecutive patients. *Heart.* 2003;89:199-204.
- Bialkowski J, Kusa J, Szkutnik M, Kalarus Z, Banaszak P, Bermúdez-Cañete R, et al. Cierre percutáneo de la comunicación interauricular. Resultados a corto y medio plazo. *Rev Esp Cardiol.* 2003;56:383-8.
- King TD, Mills NL. Secundum atrial septal defects: non-operative closure during cardiac catheterization. *JAMA.* 1976;235:2506-9.
- Murphy JG, Gersh BJ, McGoon MD, Mair DD, Porter CJ, Ilstrup DM, et al. Long-term outcome after surgical repair of isolated atrial septal defect. Follow-up at 27 to 32 years. *N Engl J Med.* 1990;323:1645-50.
- Attie F, Rosas M, Granados N, Zabal C, Buendía A, Calderón J. Surgical treatment for secundum atrial septal defects in patients >40 years old. A randomized clinical trial. *J Am Coll Cardiol.* 2001;38:2035-42.
- Attie F. Comunicación interauricular en pacientes mayores de 40 años. *Rev Esp Cardiol.* 2002;55 Suppl 1:33-6.
- Masura J, Gavora P, Podnar T. Long-term outcome of transcatheter secundum-type atrial septal defect closure using Amplatzer septal occluders. *J Am Coll Cardiol.* 2005;45:505-7.
- Hijazi ZM, Cao Q, Patel HT, Rhodes J, Hanlon KM. Transesophageal echocardiographic results of catheter closure of atrial septal defect in children and adults using the Amplatzer device. *Am J Cardiol.* 2000;85:1387-90.
- Hijazi ZM, Wang Z, Cao Q, Koenig P, Waight D, Lang R. Transcatheter closure of atrial septal defects and patent foramen ovale under intracardiac echocardiographic guidance: feasibility and comparison with transesophageal echocardiography. *Catheter Cardiovasc Interv.* 2001;52:194-9.
- Bruce CJ. Intracardiac echocardiography guiding successful ablation. *Eur J Echocardiography.* 2003;4:4-5.
- Villacastín J, Pérez-Castellano N, Moreno J, Álvarez L, Morales R, Rodríguez A. Resultados de la curva de aprendizaje de la punción transeptal guiada mediante ecografía intracardiaca. *Rev Esp Cardiol.* 2004;57:359-62.

14. Zanchetta M, Onorato E, Rigatelli G, Pedon L, Zennaro M, Carrozza A, et al. Intracardiac echocardiography-guided transcatheter closure of secundum atrial septal defect: a new efficient device selection method. *J Am Coll Cardiol*. 2003;42:1677-82.
15. Mullen MJ, Dias BF, Walker F, Siu SC, Benson LN, McLaughlin PR. Intracardiac echocardiography guided device closure of atrial septal defects. *J Am Coll Cardiol*. 2003;41:285-92.
16. Earing MG, Cabalka AK, Seward JB, Bruce CJ, Reeder GS, Hagler DJ. Intracardiac echocardiographic guidance during transcatheter device closure of atrial septal defect and patent foramen ovale. *Mayo Clin Proc*. 2004;79:24-34.
17. Bartel T, Konorza T, Arjuman J, Ebralize T, Eggebrecht H, Caspari G, et al. Intracardiac echocardiography is superior to conventional monitoring for guiding device closure of interatrial communications. *Circulation*. 2003;107:795-7.
18. Bartel T, Konorza T, Neudorf U, Ebralize T, Eggebrecht H, Gutersohn A, et al. Intracardiac echocardiography: an ideal guiding tool for device closure of interatrial communications. *Eur J Echocardiography*. 2005;6:92-6.
19. Hernández F, Albarrán A, García J, Sánchez I, Velázquez MT, Andreu J, et al. Eficacia y seguridad de la ecocardiografía intracardiaca en el cierre percutáneo de defectos del tabique interauricular en adultos. *Rev Esp Cardiol*. 2005;58 Suppl 1:69.
20. Laraudogoitia E. Ecocardiografía. Impacto de las nuevas tecnologías. *Rev Esp Cardiol*. 2005;5:45-54.
21. Silvestry FE, Wieggers SE. *Intracardiac echocardiography*. London: Taylor & Francis; 2006.
22. Zanchetta M, Rigatelli G, Pedon L, Zennaro M, Onorato E, Maiolino P. Intracardiac echocardiography during catheter-based procedures: ultrasound system, examination technique and image presentation. *Echocardiography*. 2002;19:501-7.
23. Konstantinides S, Geibel A, Olschewski M, Gornandt L, Roskamm H, Spillner G, et al. A comparison of surgical and medical therapy for atrial septal defects in adults. *N Engl J Med* 1995;333:469-473.
24. Galal MO, Wobst A, Halees Z, Hatle L, Schmaltz AA, Khougeer F, et al. Peri-operative complications following surgical closure of atrial septal defect type II in 232 patients: a baseline study. *Eur Heart J*. 1994;15:1381-4.
25. Patel A, Cao QL, Koenig PR, Hijazi ZM. Intracardiac echocardiography to guide closure of atrial septal defects in children less than 15 kilograms. *Catheter Cardiovasc Interv*. 2006;68:287-91.
26. Carlson KM, Justino H, O'Brien RE, Dimas VV, Leonard GT, Pignatelli RH, et al. Transcatheter atrial septal defect closure: modified balloon sizing technique to avoid overstretching the defect and oversizing the Amplatzer septal occluder. *Catheter Cardiovasc Interv*. 2005;65:390-6.
27. Meier B. Percutaneous atrial septal defect closure: pushing the envelope but pushing it gently. *Catheter Cardiovasc Interv*. 2005;65:397-9.
28. Amin Z. Transcatheter closure of secundum atrial septal defects. *Catheter Cardiovasc Interv*. 2006;68:778-87.
29. Post MC, Suttorp MJ, Jaarsma W, Thijs Plokker HW. Comparison of outcome and complications using different types of devices for percutaneous closure of a secundum atrial septal defect in adults: a single-center experience. *Catheter Cardiovasc Interv*. 2006;67:438-43.
30. Hijazi ZM. Efficacy and safety of device closure of ASDs in adult patients: does the type of device influence outcome? *Catheter Cardiovasc Interv*. 2006;67:444.
31. Krumsdorf U, Ostermayer S, Billinger K, Trepels T, Zadan E, Horvath K, et al. Incidence and clinical course of thrombus formation on atrial septal defect and patent foramen ovale closure devices in 1000 consecutive patients. *J Am Coll Cardiol* 2004;43:302-309.