

Correction of the Perpendicular Positioning of the Amplatzer Device During Closure of an Ostium Secundum Atrial Septal Defect

Ramón A. Flores,^a Antonio Salgado,^a Sandra P. Antúnez,^b Humberto García,^a and José L. Aceves^a

^aLaboratorio de Intervencionismo en Cardiopatías Congénitas, Centro Médico Nacional 20 de Noviembre, ISSSTE, México DF, Mexico

^bServicio de Ecocardiografía, Centro Médico Nacional 20 de Noviembre, ISSSTE, México DF, Mexico

Introduction and objectives. Ostium secundum atrial septal defects require closure. Echocardiographic studies have reported that, in 7% of cases, the Amplatzer occluder is orientated perpendicular to the rim of the defect. This article describes the use of an ancillary technique involving a balloon catheter that enables the Amplatzer device to be positioned transversely.

Methods. We report 6 patients with an ostium secundum atrial septal defect in whom echocardiographic imaging showed that the Amplatzer device was positioned perpendicular to the rim of the defect. To correct the device's orientation, we used an ancillary maneuver that involved placing a balloon catheter at the device's lower edge, thereby inducing it to adopt a transverse position and undergo successful implantation.

Results. In all cases, the ancillary balloon catheter technique enabled the device to adopt the correct transverse orientation, thereby facilitating successful implantation.

Conclusions. The ancillary balloon catheter technique is useful for ensuring that Amplatzer devices adopt a transverse orientation when echocardiography shows the device to be persistently orientated perpendicular to the rim of the septal defect.

Key words: Amplatzer. Atrial septal defect. Intracardiac device.

Corrección de la posición perpendicular del ocluser Amplatzer en el cierre percutáneo de la comunicación interauricular ostium secundum

Introducción y objetivos. La comunicación interauricular ostium secundum (CIAOS) es una afección que requiere cierre del defecto. Se han publicado imágenes ecocardiográficas con la posición perpendicular del ocluser Amplatzer en el 7% de los casos. En este documento describimos una técnica de apoyo con balón que permite la presentación transversa del dispositivo.

Métodos. En 6 pacientes con diagnóstico de CIAOS se observó mediante imágenes ecocardiográficas la posición perpendicular del dispositivo sobre los bordes del defecto. Para corregir esta posición, aplicamos una maniobra de apoyo con balón sobre el borde inferior del dispositivo para favorecer la posición transversa y su implantación.

Resultados. En todos los casos, la maniobra de apoyo con balón permitió la correcta presentación transversa del dispositivo, favoreciendo su implantación.

Conclusiones. La técnica de apoyo con balón es una alternativa útil que permite la posición transversa del dispositivo Amplatzer cuando en imágenes ecocardiográficas el dispositivo mantiene una posición persistentemente perpendicular sobre los bordes del defecto.

Palabras clave: Amplatzer. Comunicación interauricular. Dispositivos intracardiacos.

INTRODUCTION

The ostium secundum atrial septal defect (OSASD) is an abnormal opening that requires early closure because of the anatomical and hemodynamic changes it produces in right ventricle and the pulmonary arterial bed.¹ Percutaneous closure using the Amplatzer occluder has

proved to be an effective therapeutic alternative since 1997.²⁻⁵ For the proper implantation of the device, the echocardiographic image must show that it is positioned transversely to the rim of the defect. The perpendicular positioning of the Amplatzer occluder over the rim of the defect, reported as far back as the earliest studies, impedes its self-centering capacity and correct implantation.^{2,3} This complication has been recorded in 7% of the cases and can lead to excessive manipulation of catheters, embolization and the failure of the procedure.³⁻⁸ Here, we describe an ancillary technique involving a balloon catheter that prevents the failure of defect closure resulting from the perpendicular positioning of the occluder device.

Correspondence: Dr. J.L. Aceves Chimal.
Laboratorio de Intervencionismo en Cardiopatías Congénitas.
Avda. Félix Cuevas, 540. Col del Valle CP 03100, México.
E-mail: aceves996@hotmail.com

Received July 25, 2007.
Accepted for publication March 6, 2008.

ABBREVIATIONS

OSASD: ostium secundum atrial septal defect
TEE: transesophageal echocardiography
TTE: transthoracic echocardiography

METHODS

Echocardiographic images corresponding to six patients revealed that the occluder device (Amplatzer AGA Medical Corporation, Golden Valley, Minnesota) was persistently positioned perpendicular to the rim of the defect, complicating the procedure and, thus, its implantation. The patients were accepted for percutaneous closure of the defect, during a session involving medical and surgical personnel from the cardiology and cardiac surgery departments, in accordance with the guidelines established in the medical literature.²⁻⁸ We recorded their age, sex and weight, as well as the diameter and rim of the defect, determined by transthoracic echocardiography (TTE) and transesophageal echocardiography (TEE).

The hemodynamic study carried out prior to closure of the septal defect provided information on blood oxygen saturation and superior vena cava, inferior vena cava, right atrial, left atrial, pulmonary vein, right ventricular and main pulmonary artery pressures, the pulmonary to systemic flow ratio (Qp:Qs) and pulmonary vascular resistance.

Conventional Technique

The continuous electrocardiographic recording was performed using 1 bipolar lead (II) and 1 unipolar lead (V₅) and arterial blood pressure was recorded with a wrist sphygmomanometer. The patients were sedated with fentanyl citrate (1 µg/kg body weight [BW]) and midazolam hydrochloride (100 µg/kg BW). Heparin (100 IU/kg BW) and cephalothin (100 mg/kg BW) were administered. The diagnosis was verified and the OSASD rim assessed by means of TEE. The Seldinger technique

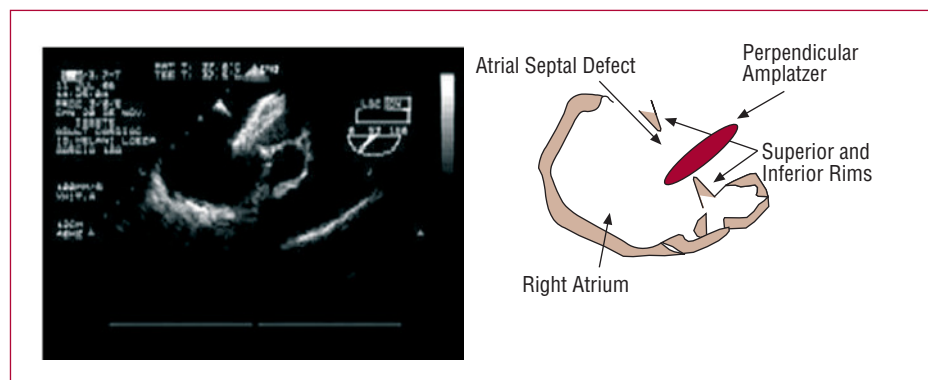
was employed for femoral vein access, and a multipurpose catheter was advanced to left upper pulmonary vein. The four-chamber view of the heart was obtained by means of contrast echocardiography using Optiray 350 (1 mL/kg BW), which was injected into right upper pulmonary vein to enable the determination of the diameter of the OSASD and assessment of the arteriovenous shunt flow. The size of the device to be employed was determined on the basis of the stretched diameter of the defect using a Meditech balloon (Boston Scientific, Watertown, Massachusetts), in agreement with the sizing plate of the device (AGA Medical) and with the size of the defect estimated by means of echocardiography.

The release system was advanced until it crossed the OSASD into the left atrium; once the occluder was loaded, a conventional technique was employed to advance the device through the release system toward the heart. During fluoroscopy, the expansion of the left disc and part of the waist was initiated within the left atrium, after which the device was pulled towards the right atrium. The transverse position was ensured under TEE guidance, as were the attachment and self-centering of the device over the rim of the defect. However, in the six cases reported here, the position was persistently perpendicular, and the left disc was located on the posteroinferior margin of the septal defect, without achieving self-centering (Figure 1). After three attempts to rotate and free the device, we employed the balloon-assisted technique.

Alternative Balloon-Assisted Technique

A 24-mm sizing balloon catheter (AGA Medical Corporation) was introduced through a contralateral femoral vein access. It was drawn across the OSASD and its distal end was advanced to the orifice of left upper pulmonary vein. The balloon was then inflated with a mixture of 1 mL of saline solution and 3 mL of contrast medium, and was positioned at the lower rim of the defect. The inflated balloon provided transient support to the lower edge of the Amplatzer occluder and the deployment of the device was initiated. The transverse position and self-centering of the occluder were achieved (Figure 2)

Figure 1. Transesophageal echocardiographic (TEE) image showing the Amplatzer device located on the inferior rim of the atrial septal defect. The diagram to the right represents the TEE image.



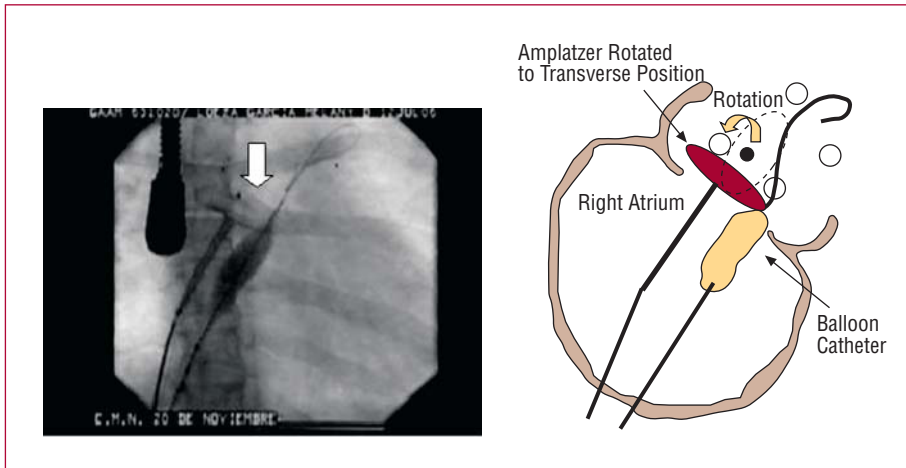


Figure 2. Fluoroscopic image showing the maneuver in which the balloon lends support to the lower edge of the Amplatzer device to correct the perpendicular position to a transverse position. The diagram to the right represents the fluoroscopic image.

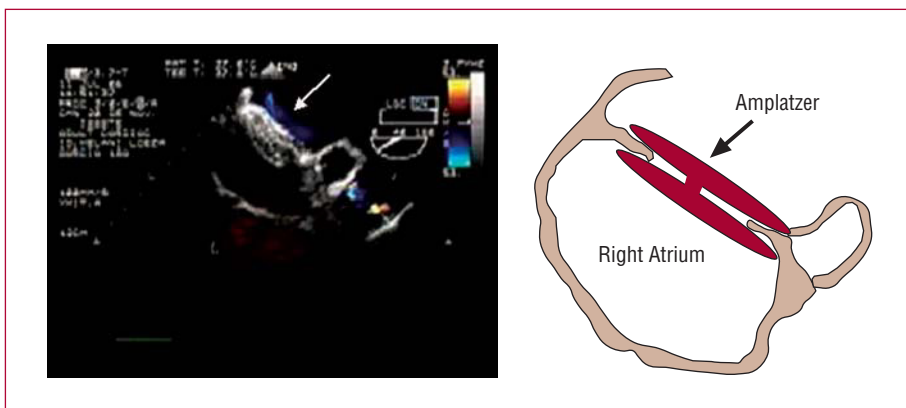


Figure 3. Transesophageal echocardiographic (TEE) image showing the discs of the Amplatzer device attached to either side of the septal defect rim. The arrow indicates the device closing the atrial septal defect. The diagram to the right represents the TEE image.

and its discs were correctly attached on either side of the septal rim, ensuring the successful closure of the OSASD (Figure 3).

RESULTS

Of 58 patients who underwent percutaneous closure of an OSASD, the procedure had to be suspended in five cases due to a posteroinferior margin of less than 5 mm, as determined by TEE during the procedure. In eight cases, echocardiographic images revealed that the device had remained perpendicular to the rim of the defect; in the first 2 cases, defect closure was unsuccessful, whereas in the remaining 6, the balloon-assisted technique was performed and closure was achieved.

The ages and weights of the patients ranged between 2 and 26 years and 11 and 72 kg, respectively. The sizes of the OSASD ranged from 16 to 28 mm according to TTE and from 16 to 26 mm according to TEE. The measurements of the rims of the defects ranged as follows: posterior, 4-11 mm; aortic, 2-5 mm; inferior vena cava, 5-7 mm; and superior vena cava, 5-14 mm. The diameters of the devices implanted ranged between 18 and 32 mm (Table 1).

The hemodynamic study demonstrated that all the patients presented normal blood oxygen saturation and

right heart chamber and pulmonary pressures. The pulmonary to systemic flow ratio ($Q_p:Q_s$) and pulmonary vascular resistance were adequate for closure of the defect (Table 2).

DISCUSSION

Percutaneous closure of OSASD in humans was initially performed with rigid, difficult to manage devices.⁹⁻¹¹ Technological advances and medical creativity led to the development of occluders, introducing improvements in the design and materials of which they are made. The Amplatzer device consists of a single component with 2 retention discs, joined by a waist that makes it possible to expand and retrieve the discs as many times as necessary until proper self-centering and implantation is achieved.¹²⁻²⁰

At this point, the technique for the implantation of the Amplatzer device for OSASD closure has been standardized, and its practice is safe and effective in most tertiary care hospitals; however, in some cases, the incorrect position of the device over the rim of the defect impedes its successful implantation. In some series, the perpendicular position of the device over the margins of the defect is reported in 7% of the cases,^{2,3} making it necessary to repeat the attempted implantation several times. This leads to excessive manipulation of catheters and maneuvers that

TABLE 1. Demographic Variables, Diameters, and Rims of the Atrial Septal Defect, Determined by Transthoracic and Transesophageal Echocardiography, and Diameters of the Amplatzer Device Implanted

Patient	Sex	Age, Years	Weight, kg	TEE, mm	TEE, mm	Stretched, mm	Rims, mm				Amplatzer Device, mm
							P	Ao	IVC	SVC	
1	Female	19	49	26	25	26	8	2	7	6	28
2	Male	4	14	18	21	17	8	4	6	5	20
3	Female	4	15	18	18	18	7	3	6	6	20
4	Female	17	45	22	28	28	5	5	5	5	32
5	Male	26	72	16	20	18	11	3	7	14	22
6	Male	2	11	16	16	17	4	5	5	5	18

Ao indicates aorta; IVC, inferior vena cava; P, pulmonary; stretched, stretched, diameter of the ostium secundum atrial septal defect; SVC, superior vena cava; TEE, transesophageal echocardiography; TTE, transthoracic echocardiography.

TABLE 2. Cardiac Output Ratio and the Pulmonary and Systemic Resistances Prior to Implantation of the Amplatzer Device

Patient	Qp:Qs	Resistances, Wood Units	
		Pulmonary	Systemic
1	3.1:1	3.57	20
2	2.27:1	2	22.56
3	2.13:1	1.15	11.4
4	3.14:1	1.49	17.3
5	2.81:1	2.57	25.23
6	2.1:1	2	16

Qp:Qs indicates pulmonary to systemic flow ratio.

increase the risks of perforating cardiac chambers, tearing the septal margins, embolization and failure of the procedure.¹²⁻²⁰ In our series, we observed an incidence of 13%, although we should consider the number of patients to be low with respect to other published series.

During the maneuver to release the first disc of the device, the disc must attach to the inferolateral margin of the defect to favor the transverse position of the device over the rim of the defect, as observed in TEE images, and thus enable its self-centering, an indispensable condition for its implantation. A number of authors mention the incorrect position of the device over the septal rim, and they correct it by means of rotational maneuvers during the sequence in which the device is expanded. However, these maneuvers involve risks of embolization and perforation of the cardiac tissue.²¹⁻²⁹ Kannan et al²⁶ and Wahab et al²⁷ indicate that cutting the Mullins sheath makes it possible to achieve the proper angulation of the device and the perpendicular position is corrected, although, during the implantation process, it increases the risk of air embolism and of vascular lesion upon introduction of the cut sheath. It is remarkable that, despite there being over 100 published cases, this correction technique has not produced either of these complications.²⁹

Certain factors contribute to the anomalous position of the device over the OSASD, one of the most common of which is the presence of an inadequate posteroinferior rim.³⁰ Varma et al³¹ reported that the failure of the implantation of the device due to incorrect positioning occurs when the inferior rim is unable to support the device, especially if it is combined with a small anterior rim. In four of our cases, the aortic rim measured 3 mm or less and, although the inferior rims were of adequate size, reduced tension in the tissue may have resulted in a lack of sufficient support for the device, increasing the likelihood of it adopting a perpendicular position over the septal defect.²⁷⁻³⁰ In addition, Dalvi et al³⁰ pointed out that the presence of a small left atrium can lead to the poor position of the device since it does not permit the rotation of the disc within the posterior curvature of the atrium at the level of the pulmonary veins or anteriorly because of the atrial appendage. This may have been the cause of the persistent perpendicular position of the device in some of our cases (in patients 1, 4, and 5), as they presented small septal defects and rims.

In the Catheterization Laboratory for Congenital Heart Diseases at Centro Médico Nacional 20 de Noviembre of the Instituto de Seguridad y Servicios Sociales de los Trabajadores del Estado (ISSSTE; Government Workers' Social Security and Services Institute, Mexico), in the first 2 cases of perpendicular positioning of the Amplatzer occluder, observed in sagittal plane TEE images, we carried out the maneuvers described by other authors, with excessive manipulation of the catheters and of the occluder,²⁵⁻²⁹ but the incorrect position of the device persisted and, consequently, the OSASD closure was unsuccessful. In the remaining 6 cases, we employed the balloon-assisted technique, which proved to be useful and enabled us to achieve the transverse position, with self-centering of the device and successful closure of the OSASD.

The technique, in which a balloon is employed to support the inferolateral edge of the device, described by Masura et al,² Dalvi et al,³⁰ and Varma et al³¹ adds the

inconvenience of having to employ another femoral access, with the risk of complications in the process of puncture and the introduction of the balloon catheter. Fortunately, these authors reported no complications, nor did we observe them in our experience. We consider these risks to be minor when compared with the risks of thromboembolism, perforation of cardiac structures and tearing of the septal margins secondary to the excessive manipulation of the catheters that is required with other techniques utilized to correct the improper position of the device over the OSASD rim.^{12,19-22}

The balloon-assisted technique is useful for correcting the poor positioning of the Amplatzer device, but we do not know if it could be applied to other types of devices. The number of patients in whom this technique has been applied is small and it can not be compared with other techniques described in the literature. Nonetheless, it may represent a better alternative since, in the published series and in our experience, no complications have been observed.

CONCLUSIONS

The balloon-assisted technique is a useful and feasible alternative for the percutaneous closure of OSASD when echographic images demonstrate the Amplatzer device to be persistently orientated perpendicular to the rim of the septal defect.

REFERENCES

- Clark EB. Epidemiology of congenital cardiovascular malformations. In: Emmaouilides GC, Allen HD, Riemenschneider TA, Allen HD, Gutgesel HP, editors. Heart disease in infants, children and adolescents, including the fetus and young adults. Baltimore: Williams & Wilkins; 1995. p. 60-9.
- Masura J, Gavora P, Holan M. Initial clinical results with the Amplatzer atrial septal occluder. *Eur Heart J*. 1997;18 Suppl:78.
- Masura J, Gavora P, Formanek A. Transcatheter closure of secundum atrial septal defects using the new self-centering Amplatzer septal occluder: initial human experience. *Cathet Cardiovasc Diagn*. 1997;42:388-93.
- Berger F, Ewert P, Stiller B. Initial clinical results with the Amplatzer septal occluder —A self-centering double disc for occlusion of atrial septal defects. *Z Kardiol*. 1998;87:185-90.
- Fischer G, Kramer HH, Stieh J. Transcatheter closure of secundum atrial septal defects with the new self-centering Amplatzer septal occluder. *Eur Heart J*. 1999;20:541-9.
- Zabal C, Chio F, Amplatz K, Martínez Ríos MA. Cierre percutáneo de comunicación inter atrial con el dispositivo Amplatzer®. Primer caso en México. *Arch Inst Cardiol Mex*. 1998;68:147-52.
- Bialkowski J, Kusa J, Szkutnik M, Kalarus Z, Banaszka P, Bermúdez-Cañete R. Cierre percutáneo de la comunicación interauricular. Resultados a corto y medio plazo. *Rev Esp Cardiol*. 2003;56:383-8.
- Salas A, Stanford S, Islas E, de la Cruz R, Alarcón V. Un procedimiento seguro y eficaz para el cierre de comunicación inter atrial sin cirugía. Experiencia preliminar. *Bol Med Hosp Infantil Mexico*. 2004;61:180-8.
- Raskind W. Experimental transvenous closure of atrial and ventricular defects. *Circulation*. 1975;52:1-8.
- Raskind W, Tait M, Gibson R. Interventional cardiac catheterization in congenital heart disease. *Int J Cardiol*. 1985;7:1-11.
- Schlesinger A, Folz S, Beekman R. Transcatheter atrial septal occlusion devices: normal radiographic appearances and complication. *J Vasc Intervent Radiol*. 1992;3:527-33.
- Chessa M, Carminati M, Butera G, Bini RM, Drago M. Early and late complications associated with transcatheter occlusion of secundum atrial septal defect. *J Am Coll Cardiol*. 2002;39:1061-5.
- Fischer G, Stieh J, Uebing A, Hoffmann U, Morf G, Kramer HH. Experience with transcatheter closure of secundum atrial septal defects using the Amplatzer septal occluder: a single centre study in 236 consecutive patients. *Heart*. 2003;89:199-204.
- Wang JK, Tsai SK, Wu MH, Lin MT, Lue HC. Short- and intermediate-term results of transcatheter closure of atrial septal defect with the Amplatzer Septal Occluder. *Am Heart J*. 2004;148:511-7.
- Zabal C. Tratamiento con oclusores Amplatzer de los defectos septales. *Arch Cardiol Mexico*. 2003;73:S158-62.
- Fernández RA, del Cerro MJ, Rubio VG, Castro GM, Moreno GF. Cierre percutáneo de la comunicación interauricular mediante dispositivo de Amplatzer: resultado inicial y seguimiento a medio plazo. *Rev Esp Cardiol*. 2001;54:1190-6.
- Masura J, Gavora P, Podnar T. Long-term outcome of transcatheter secundum-type atrial septal defect closure using amplatzer septal occluders. *J Am Coll Cardiol*. 2005;45:505-7.
- Rodríguez M, Suárez de Lezo J, Pan M, Romero M, Segura J, Pavlovic D. Cierre percutáneo de comunicaciones interauriculares grandes. *Rev Esp Cardiol*. 2003;56:888-93.
- Divekar A, Gaamangwe T, Shaikh N, Raabe M, Ducas J. Cardiac perforation after device closure of atrial septal defects with the Amplatzer septal occluder. *J Am Coll Cardiol*. 2005;45:1213-8.
- James WM, Bichell D, Rothman A. Absent posteroinferior and anterosuperior atrial septal defect rims: factors affecting nonsurgical closure of large secundum defects using the Amplatzer occluder. *J Am Soc Echocardiogr*. 2004;17:62-9.
- Zhong-Dong D, Ziyad M, Hijazi CS, Kleinman NH, Silverman KL. Comparison between transcatheter and surgical closure of secundum atrial septal defect in children and adults results of a multicenter nonrandomized trial. *J Am Coll Cardiol*. 2002;39:1836-44.
- Ourania P, Sridhar SK, Wasnick J, Gold JP. Late cardiac perforation following transcatheter atrial septal defect closure. *Ann Thorac Surg*. 2004;77:1435-7.
- Amin Z, Hijazi ZM, Bass JL, Cheatham JP, Hellenbrand WE, Kleinmann CS. Erosion of Amplatzer septal occluder device after closure of secundum atrial defects: review of registry of complications and recommendations to minimize future risk. *Catheter Cardiovasc Interv*. 2004;63:496-502.
- Spies C, Boosfeld C, Schra R. A modified cook sheath for closure of a large secundum atrial septal defect. *Cathet Cardiovasc Interv*. 2007;70:286-9.
- Shelby K, Asnes JD, Srinath G, Preminger TJ, Prieto L, Latson LA. Use of a straight, side-hole delivery sheath for improved delivery of Amplatzer ASD occluder. *Cathet Cardiovasc Interv*. 2007;69:15-20.
- Kannan J, Francis E, Sivakumar K, Radha Anil, Kumar RK. Transcatheter closure of very large (≥ 25 mm) atrial septal defects using the amplatzer septal occluder. *Cathet Cardiovasc Interv*. 2003;59:522-7.
- Wahab HA, Bairam AR, Cao Q, Hijazi ZM. Novel technique to prevent prolapse of the Amplatzer septal occluder through large atrial septal defect. *Cathet Cardiovasc Interv*. 2003;60:543-5.
- Hoyer MH. Delivery sheath tear after modification for ASD closure. *Cathet Cardiovasc Interv*. 2006;68:162-4.
- Meier B. Catheter-based atrial shunt occlusion, when the going gets ven tougher: Editorial comment to use of a straight, side-hole (SSH), delivery sheath for improved delivery of Amplatzer ASD occluder. *Cathet Cardiovasc Interv*. 2007;69:21-2.
- Dalvi B, Pinto RJ, Gupta A. New technique for device closure of large atrial septal defects. *Cathet Cardiovasc Interv*. 2005;64:102-7.
- Varma C, Benson LN, Silversides C, Yip J, Warr MR, Siu SC, et al. Outcomes and alternative techniques for device closure of the large secundum atrial septal defect. *Cathet Cardiovasc Interv*. 2004;61:131-9.