

REVIEW ARTICLE

Three-Dimensional Echocardiography. New Possibilities in Mitral Valve Assessment

Jorge Solis,^a Marta Sitges,^b Robert A. Levine,^a and Judy Hung^a

^aCardiology Division, Massachusetts General Hospital, Harvard Medical School, Boston, Massachusetts, USA

^bServicio de Cardiología, Institut Clínic del Torax, Hospital Clínic, Institut d'Investigacions Biomediques August Pi i Sunyer, Universitat de Barcelona, Barcelona, Spain

Recent developments in 3-dimensional echocardiography have made it possible to obtain images in real time, without the need for off-line reconstruction. These developments have enabled the technique to become an important tool for both research and daily clinical practice. A substantial proportion of the studies carried out using 3-dimensional echocardiography have focused on the mitral valve, the pathophysiology of mitral valve disease and, in particular, functional mitral regurgitation. This article will review the contribution of 3-dimensional echocardiography to the understanding of the functional anatomy of the mitral valve and to summarize its resulting clinical applications and therapeutic implications.

Key words: *Three-dimensional echocardiography. Real-time 3-dimensional echocardiography. Mitral regurgitation.*

Ecocardiografía tridimensional. Nuevas perspectivas sobre la caracterización de la válvula mitral

Recientes avances en la ecocardiografía tridimensional han permitido obtener imágenes en tiempo real, sin necesidad de realizar una reconstrucción off-line. Estos avances la han convertido en una importante herramienta tanto para la investigación como para la práctica clínica diaria. Gran parte de los trabajos realizados mediante ecocardiografía tridimensional se centran en el análisis de la válvula mitral, la fisiopatología de las lesiones mitrales y, en especial, la insuficiencia mitral funcional. El objetivo de este artículo es revisar la aportación de la ecocardiografía tridimensional en

el conocimiento de la anatomía funcional de la válvula mitral, sus aplicaciones clínicas y sus implicaciones terapéuticas.

Palabras clave: *Ecocardiografía tridimensional. Ecocardiografía tridimensional en tiempo real. Insuficiencia mitral.*

INTRODUCTION

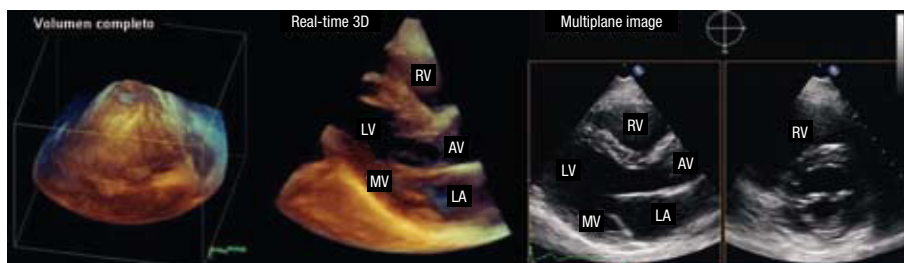
Real-time 3-dimensional echocardiography (RT3DE) has been in continuous development for approximately 10 years. Advances in the acquisition, storage and analysis of RT3DE images have made its use increasingly common in echocardiography laboratories, not only for research purposes but also in daily clinical practice. Many three-dimensional echocardiographic (3DE) studies focus on the analysis of the mitral valve (MV). 3DE has enabled us to understand the functional anatomy of the MV, the pathophysiology of MV disease, and especially that of functional mitral regurgitation (FMR). The recent development of transesophageal RT3DE (TERT3DE) has led to important advances in the diagnosis of mitral valve disease and in the monitoring of cardiac surgery and percutaneous, interventional MV procedures. The objective of this article is to review the contribution of 3DE to our knowledge of MV functional anatomy, the clinical applications of 3DE and its therapeutic implications.

DEVELOPMENT OF 3-DIMENSIONAL ECHOCARDIOGRAPHY

The first 3DE images of the heart were obtained by Dekker et al¹ in 1974. Since then, different 3D systems have been developed based on a laborious reconstruction of acquired 2-dimensional images (2DE) that have been synchronized to the electrocardiogram and respiratory motion. This

Correspondence: Dr J. Solis Martin, Cardiology Division, Massachusetts General Hospital, Blake 2, 55 Fruit Street, Boston, MA 02114 USA
E-mail: jsolis-martin@partners.org.

Figure 1. RT3DE imaging: full-volume, obtaining a pyramid of information; real-time 3D, showing a parasternal slice on the long axis; multiplane with the simultaneous image of two 2-dimensional planes (longitudinal parasternal and transverse parasternal planes at the level of the mitral valve). AV indicates aortic valve; LA, left atrium; LV, left ventricle; MV, mitral valve; RV, right ventricle.



technique has contributed valuable information on cardiac anatomy and function. However, due to the lengthy image-processing time required, its use was limited clinically to a few echocardiography laboratories and to the research arena.

The development of matrix transducers with more than 3000 crystals, together with new processors, has enabled the acquisition of real-time images without the need for off-line reconstruction. These new advances have allowed the application of 3DE to daily clinical practice.

Three types of images can be acquired with RT3DE: Near-real-time full-volume images, real-time (“live”) 3D images, and Multi-plane images (2 or 3 planes obtained simultaneously) (Figure 1). The selection of one type of imaging mode depends on the cardiac structures being examined and the objective of the study. In order to obtain images of the left ventricle and determine its dimensions and systolic function, full-volume images in the apical view are recommended as they can capture the left ventricle in its entirety. This requires 4-7 heart beats and requires synchronization with the electrocardiogram and, ideally, with respiratory motion. Images of smaller, faster moving, structures (e.g. pulmonary or aortic valves) can be acquired with real-time 3D and we can even zoom in to obtain larger images (3D-zoom). Real-time imaging makes synchronization with the electrocardiogram unnecessary, but the acquired volume is narrower.

Finally, multiplane imaging, specifically biplane acquisition, is extremely useful as it enables the visualization of longitudinal and transverse planes of the structure of interest simultaneously, and allowing plane-angle correction to obtain the desired view. Furthermore, the application of multiplane RT3DE to stress echocardiography is important as it reduces image acquisition time significantly (REF).

Once images have been obtained, they can be visualized in two ways: a 3-dimensional, volumetric structure enabling the visualization of each cardiac chamber and the spatial relationship of contiguous structures (Figure 2), or three simultaneous 2D planes (coronal, sagittal and transverse slices) (Figure 3). With the latter, the slice plane through the volume of data can be manipulated in any

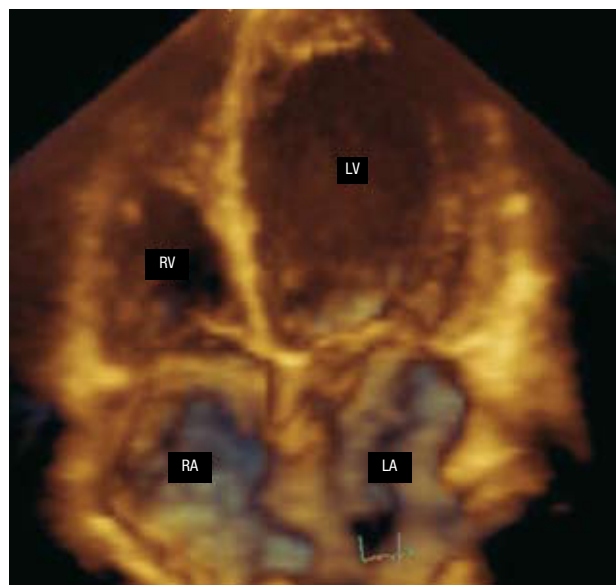


Figure 2. Three-dimensional image of cardiac cavities taken by full-volume imaging from the apical plane. LA indicates left atrium; LV, left ventricle; RA, right atrium; RV, right ventricle.

direction to obtain adequate visualization of the area of interest. For example, obliquely-acquired planes or 2D images with inadequate visualization of the apex may easily be corrected using this method. Thus, 3DE has demonstrated superiority over 2DE in measuring left ventricular volumes, especially in patients with dilated cavities and distorted ventricular geometry.²⁻⁵ Moreover, unlike 2DE, 3DE makes no geometric assumptions in order to calculate volumes.

Early 3D color Doppler echocardiography systems also required laborious reconstruction but full volume imaging has eliminated that need. Seven heart beats are needed to acquire a full-volume image which is able to demonstrate the entire flow of interest. This method is especially useful in complex mitral regurgitant flows (e.g. with the Coanda effect), the severity of which is usually underestimated by 2DE.^{6,7} Studying the precise direction of eccentric flow patterns is also possible by 3D color Doppler with the concomitant use of multi-plane image acquisition.

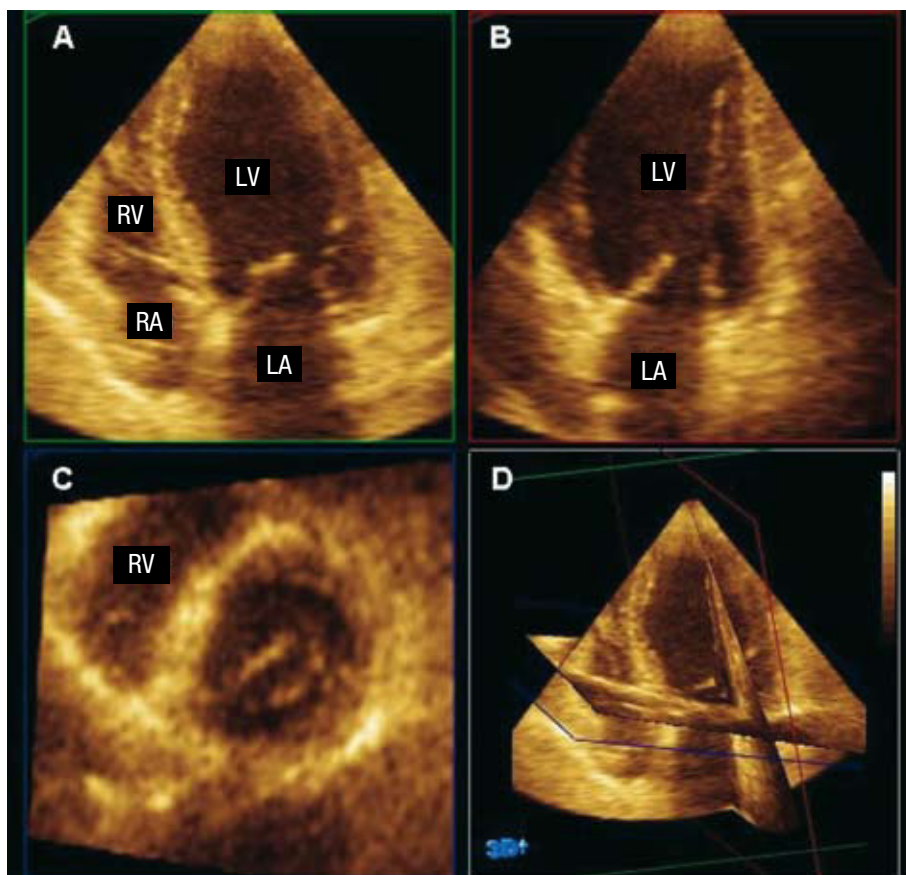


Figure 3. Full-volume image showing three simultaneous, two-dimensional planes (A indicates coronal slice; B, sagittal slice; C, transverse slice; D, the 3 planes superimposed). By reorienting these planes we can study each of the cardiac structures. LA indicates left atrium; LV, left ventricle; RA, right atrium; RV, right ventricle..

TABLE 1. Dimensional Electrocardiography Protocol

Parasternal view	Full-volume imaging 3D color Doppler at the level of the mitral and aortic valves
Apical view	3D color Doppler at the level of the tricuspid and pulmonary valves Full-volume imaging. Includes the 2 ventricles and the 2 atria
Subcostal view	3D color Doppler at the level of the mitral, aortic, tricuspid, and pulmonary valves Full-volume imaging
Suprasternal view	3D color Doppler at the level of the interatrial and interventricular septa Full-volume imaging 3D color Doppler at the level of the descending aorta

TERT3DE has been introduced within the last two years. The principal advantage of TERT3DE over 2D transesophageal echocardiography is that it enables the visualization of specific structures from various angles. Complete imaging of the mitral valve has benefited from TERT3DE – the whole structure may be imaged and subsequently mapped from one single image without the need for off-line reconstruction. Consequently, surgeons and interventional cardiologists specializing in the MV increasingly request TERT3DE studies prior to any procedure.

The American Society of Echocardiography has proposed a full clinical practice protocol for RT3DE

use (Table 1). Alternatively, RT3DE could complement conventional 2D studies with a specific focus on the structures of interest.

Although RT3DE has succeeded in eliminating some of the limitations that prevented the application of other 3D techniques in clinical practice, significant limitations remain. The technique relies on image quality and there is a long learning curve to optimal image acquisition. Compared with conventional 2DE, RT3DE suffers from low spatial resolution which, for example, prevents automatic endocardial border detection for volume quantification.

The lower frame rate can also be a significant limitation when quantifying regurgitant flow. Full

volume imaging acquires the data over 4-7 heartbeats and thus is prone to ECG-related and respiratory motion artifacts. Finally, real-time (“live”) imaging, although it requires no reconstruction, is limited by the small volume acquired.

THREE-DIMENSIONAL ECHOCARDIOGRAPHY IN THE EVALUATION OF MITRAL VALVE FUNCTIONAL ANATOMY

Three-dimensional echocardiography is the diagnostic technique that has contributed most to our knowledge of MV anatomy and function. Through in vitro studies and 3DE studies conducted in animal models, changes that occur in mitral and ventricular geometry following myocardial infarction, thereby giving rise to mitral regurgitation (MR), have been demonstrated.⁸ Later studies in patients confirmed these results and most have focused on FMR due to its complex underlying mechanism (Figure 4).

In FMR, the MV is apparently structurally normal. There is an imbalance between the closing forces on the mitral valve during systole.⁹ On one hand, due to ventricular dysfunction and diminished contractility, there is a consequent reduction in closing force on the mitral valve. On the other hand, apical and lateral papillary muscle (PM) displacement, secondary to adverse left ventricular remodeling, causes apically-directed traction of the mitral leaflets, reduces the degree of MV coaptation, and results in MR. Moreover, the mitral annulus usually dilates to a greater degree.^{8,10}

Using 3DE, we can analyze the components of the mitral apparatus in detail, thereby understanding normal functional anatomy and the changes that occur in FMR.

Mitral Annulus Geometry

Three-dimensional echocardiography has demonstrated that the mitral annulus is saddle-shaped.^{11,12} The highest points of the saddle, i.e. those furthest from the cardiac apex, are the anterior region closest to the aortic root and the posterior region closest to the left ventricular posterior wall.¹³ The lowest points are the two mitral commissures (Figure 5A). In healthy individuals, this shape is most marked during mid-systole when the mitral annulus attains its smallest area.¹⁴ At end-systole and end-diastole, the annulus acquires a more flattened shape.¹⁵

In patients with FMR, dilatation and flattening of the mitral annulus occur simultaneously (Figure 5B). Although the annulus dilates as a whole, the anteroposterior diameter dilates relatively more and thus the principal advantage of TERT3DE over 2D

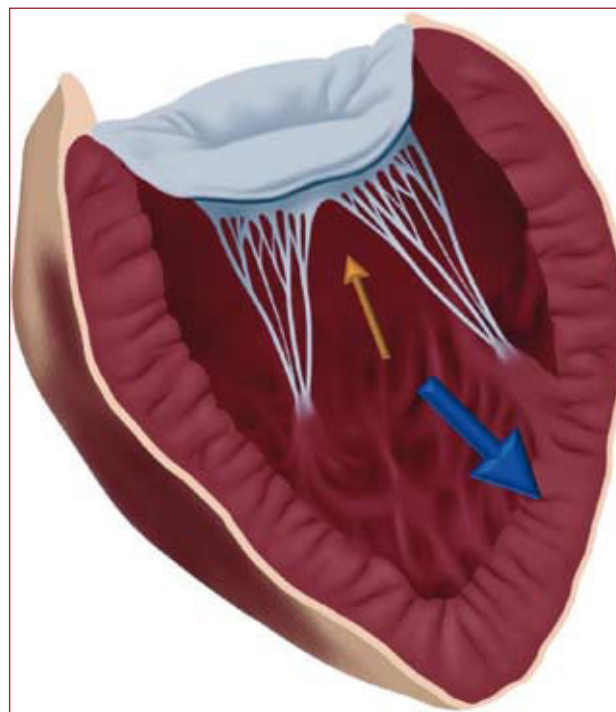


Figure 4. Mechanism of functional mitral regurgitation. Reduction of the force of closure of mitral valve during systole (orange arrow). Increase in the distance of tethering due to the apical displacement of the papillary muscles (blue arrow).

transesophageal echocardiography is that it enables us to see the MV from any angle and map the mitral valves from a single image without the need for mentally reconstruction. Consequently, surgeons and interventional cardiologists specializing in MV increasingly request TERT3DE studies prior to any procedure. The American Society of Echocardiography proposes a full clinical practice protocol for RT3DE use (Table 1). Alternatively, RT3DE could the shape of the annulus becomes more circular.¹⁶ These changes in annulus geometry are associated with the severity of MR.¹⁷ The mitral annular dilatation secondary to ischemic dilated cardiomyopathy is usually less severe than that seen with idiopathic dilated cardiomyopathy. This is most likely caused by the asymmetric remodeling seen in the ischemic variant. Similarly, mitral annular remodeling seems to differ depending on infarct location. In infarctions prior to dilatation and mitral annulus flattening, remodeling is greater than in inferior infarctions.¹³

3DE has enabled us to demonstrate mitral annular displacement by calculating displacement area.¹⁸ In healthy individuals, caudal displacement occurs, which is more accentuated in the posterior region. In patients with FMR, this displacement is reduced, most notably in the posterior region.

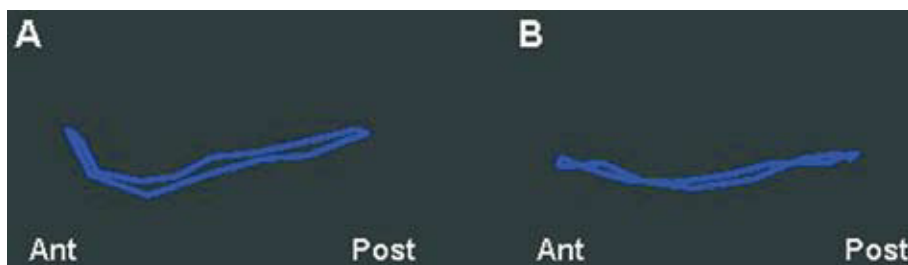


Figure 5. Three-dimensional image of the mitral annulus. A: normal, saddle-shaped, mitral annulus; the more cranial regions correspond to the anterior and posterior regions of the annulus. B: flattened mitral annulus in patient with functional mitral regurgitation.

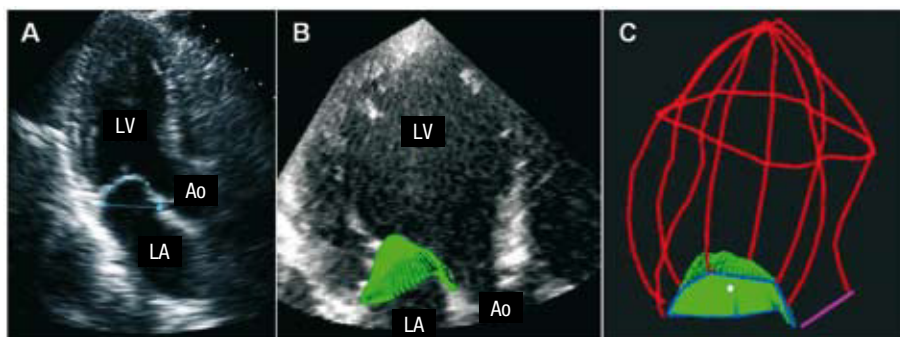


Figure 6. A: 2-dimensional image in apical plane, measuring the area of tenting. B: 2-dimensional view of a plane using OMNI4D software (designed by the Massachusetts General Hospital), from the acquisition of a full-volume image. A 3-dimensional reconstruction of the mitral valvules (in green) can be made using manual tracing with a minimum of 6 2-dimensional planes. Once traced, the volume comprendido between the annulus and the mitral valvules (volume of tenting) is calculated automatically. C: 3-dimensional reconstruction of the volume of tenting (green) together with the left ventricle (red) and mitral annulus (blue).

Mitral Leaflets

Salgo et al¹⁹ confirmed that the MV's saddle shape reduces the tension that its leaflets are subject to, as compared to a mitral valve with a more flattened annulus. The curvature contributes to the mechanism that avoids the appearance of MI and reflects the annulus' capacity to contract during systole.

With 3DE, the capability to trace the mitral leaflets and measure their area using specialized computer software exists. In addition, the tenting volume (the volume in the space between the mitral annulus and the "tented" mitral leaflets) can easily be measured thus giving an idea of the amount of tethering on the leaflets. In normal individuals, during mitral valve closure, the leaflets coapt at the level of the mitral annulus and the portion of the anterior leaflet closest to the aortic root protrudes slightly towards the left atrium. In FMR, the coaptation area is displaced apically due to leaflet traction by the papillary muscles. To date, 2DE has been used exclusively to calculate the mitral valve tenting area as an estimate of how left ventricular remodeling and geometrical changes have affected mitral annular geometry²⁰ (Figure 6A). However, recent studies have shown the asymmetry of this tenting area²¹ and the existence of patterns that differ with the etiology of FMR,²² making single plane studies less than optimal. In contrast, 3DE enables the measurement of tenting volume, the maximal diameter between the mitral

annulus and mitral leaflet surface, and the visualization of leaflet deformation from any angle (Figures 6B and C).

Subvalvular Apparatus and the Left Ventricle

Mitral leaflet traction due to papillary muscle displacement appears to be the principal causal mechanism of FMR. The amount of left ventricular remodeling differs depending on the insult and so too does the degree of PM displacement. In patients with idiopathic dilated cardiomyopathy, global ventricular remodeling occurs with resultant displacement of both PMs. Similar remodeling may occur in patients with anterior myocardial infarction and chronic MR. In both examples, the ventricle progressively dilates and takes on a more spherical shape. In contrast, in patients with FMR due to inferior infarction, localized ventricular remodeling is more common with resultant posteromedial PM displacement, producing MR through isolateral hemi-valvule traction.²³

Changes in the geometry of the mitral annulus and left ventricle are also accompanied by changes in the spatial relation between the components of the MV. To date, the principal parameter measured by 3DE has been tethering distance, ie the distance between the trigones and the head of the papillary muscles. Most studies have measured the distance between the medial trigone and the head of the posteromedial

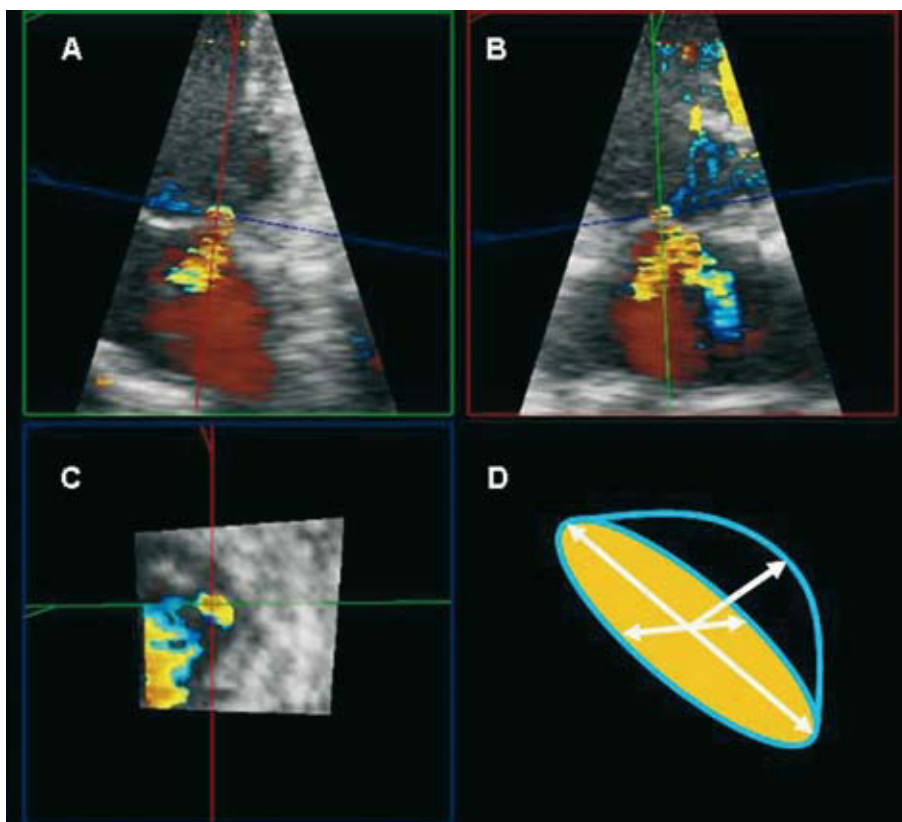


Figure 7. Simultaneous view of 3 electrocardiographic slices obtained from a full-volume image. The planes need to be reoriented to find the one that includes the regurgitation flow in its entirety. The coronal (A) and sagittal (B) slices enable us to measure the height of the semi-ellipse to calculate the regurgitant volume by the PISA method. In the transverse slice (C), we can see the base of the semi-ellipse with one larger and one smaller diameter. D: representation of the shape of the proximal isovelocity surface area.

PM, and have found good correlation with the degree of distortion of MV geometry.^{8,10,24,25}

Regurgitant Orifice Geometry

Currently, quantification of MR based on the proximal isovelocity surface area (PISA) is one of the more frequently used and validated methods.^{26,27} To calculate this, a symmetrical acceleration of flow towards the regurgitant orifice is assumed and this, in turn, creates hemispherical layers of equal velocity seen by color Doppler. With 3D color Doppler, it has been proven that this geometric assumption is not always fulfilled,^{28,29} and that the measure regurgitant orifice may be underestimated. Matsumura et al³⁰ compared regurgitant orifice geometry in patients with mitral valve prolapse (MVP) and patients with FMR. Patients with MVP demonstrated a spherical regurgitant orifice, whereas in those with FMR it was elliptical. Consequently, 3D color Doppler seems an appropriate technique to decide whether to use the conventional PISA method or assume a semi-elliptical shape for the mathematical calculation of regurgitant orifice area (Figure 7).

Clinical Applications of 3-Dimensional Echocardiography of the Mitral Valve

Since RT3DE was incorporated into clinical practice, one of its principle applications has been mitral valve pathology, in particular the quantification of valvular area and analysis of functional MV anatomy, both in Carpentier type II lesions (e.g. MVP) and FMR.

Evaluation of Mitral Stenosis

The diagnosis and determination of the severity of mitral stenosis is based on 2DE and Doppler techniques.^{31,32} The determination of valvular area with Doppler (pressure half-time or continuity method or proximal convergence flow) is the most commonly used technique. However, it is accepted that these methods are influenced by hemodynamic status (heart rate, cardiac rhythm, cardiac output), the compliance of the ventricle, and the presence of other associated valvular lesions.³³⁻³⁵

Planimeted mitral area methods are not affected by hemodynamic changes so they are widely used today.³⁶⁻³⁸ However, planimetry requires the correct orientation of the plane to obtain the smallest area

traced from the leaflets' free edge, and oblique slices can overestimate mitral area.

RT3DE is a rapid, precise technique for determining the valvular orifice area, as it facilitates the orientation of any slice plane to locate the minimal MV area. Thus, it eliminates one of the principle limitations of 2DE in determining mitral valve area by planimetry. Several studies have compared 3DE with traditional methods of calculating MV area.³⁹⁻⁴¹ The mitral area measured using RT3DE planimetry correlates better with Gorlin's formula than do traditional 2D echocardiographic methods. Moreover, with RT3DE there is less inter- and intra-observer variation when calculating mitral valve area. Inter-observer variation in calculating Wilkins' score to predict success in percutaneous valvuloplasty is also less with RT3DE. Currently, traditional methods together with RT3DE could probably be considered the best option when studying mitral stenosis.

Analysis of Mitral Prolapse

In one of the first 3DE studies, Levine et al¹⁴ confirmed that due to the saddle-shape of the mitral annulus, diagnosis of MVP by 2DE may be erroneous because apparent leaflet displacement toward the left atrium does not occur. This study led to a review of the diagnosis of this condition and in some laboratories its diagnosis fell by 50%. Using 3DE, the prolapsed segment appears convex in shape when seen from the left atrium and concave when seen from the left ventricle. Using the 2D plane view (sagittal, coronal, transverse) we can choose the most appropriate plane in which to study the motion of each scallop.

Sugeng et al⁴² studied the use of transthoracic 3DE in the identification of MVP. The group achieved adequate MV reconstruction in 70% of cases. Probably due to its greater size, the anterior leaflet was more easily seen, both in the parasternal and apical views. The posterior leaflet was better identified from the parasternal view. One more recent study⁴³ compared the diagnostic efficacy of transthoracic 3DE for MVP with that of transesophageal 2D echocardiography and proved both methods correlated well when image quality was adequate (89% of cases). TE3DE (versus other echocardiographic methods) performs best when compared with anatomic examination by the surgeon during the intervention, with correct localization of the prolapsed segment in 96% of cases.⁴⁴⁻⁴⁶

Rapid, single-image acquisition with a 3D transesophageal probe enables the evaluation of each mitral scallop from any angle without the necessity of mental reconstruction of different echocardiographic slices.⁴⁷ Using commercially-available computer software, detailed leaflet analysis

and regurgitant area measurements can be achieved and communicated to the surgeon.

Therapeutic Implications of the Analysis of Functional Mitral Regurgitation Using 3DE

Implications for Heart Surgery

Reductive mitral annuloplasty continues to be the surgical treatment of choice in patients with FMR.^{48,49} However, it is known that up to 30% of patients suffer recurrent FMR during follow-up^{50,51} and, moreover, 3DE has shown that the principal mechanism of FMR is due to adverse ventricular remodeling. Prior to valve surgery a detailed study of the anatomy and function of the mitral valve should be conducted. Conventional 2DE is severely limited in studying the 3-dimensional structure of the MV with precision, especially in the context of FMR. Real-time 3DE permits its visualization from any angle, including that of the surgeon's at the operating table (Figure 8). With these clear advantages, TERT3DE is becoming one of the principle tools for the surgeon both in planning and monitoring these types of surgical interventions.

New prosthetic mitral annuloplasty devices are being designed to attempt to recover the original shape of the mitral annulus and permit annular contraction and displacement as far as possible.⁴⁸ Yamaura et al⁵²⁻⁵⁴ have shown that a flexible annulus provides better results than a rigid one. In this new context, 3DE may be used for a detailed evaluation of the geometry of the annulus and possibly help select the most appropriate prosthesis. In addition, similar studies can be conducted post-implantation to evaluate the changes in annular geometry.

Due to the complex pathogenic mechanism of FMR, it is important to conduct a detailed study of mitral and ventricular geometry. To achieve reproducible measures, it is necessary to identify the imaging plane that defines each of the cardiac structures. 2DE is limited in that all points of interest cannot be localized in one plane. This limitation is overcome with 3DE (Figure 9). With the development of new, user-friendly, 3D-images analysis software, the time needed to measure mitral geometry is no more than 5 minutes. The precise mechanism of MR can now be elucidated using novel 3DE imaging techniques. The above-mentioned parameters that can now be measured with 3DE will surely help improve results of mitral repair (Table 2).

So, visualization of the annulus and mitral valves in their totality, together with analysis of subvalvular apparatus, would reveal the precise MI mechanism to the surgeon together with the degree of mitral and ventricular geometry distortion in each patient. This

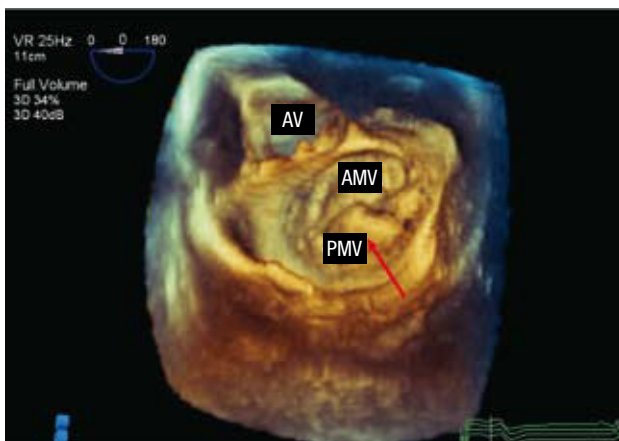


Figure 8. Three-dimensional TERT3DE image. The mitral valve is viewed from the atrium with the aorta at 11 o'clock (the surgeon's view). The posterior mitral valve (PMV) presents a prolapse at the level of the medial scallop (red arrow). AV indicates aortic valve; AMV, anterior mitral valve.

would facilitate individualized repair surgery planning and improve results.

Contribution of 3DE to the Development of New Therapeutic Alternatives

In recent years, various devices and techniques used in experimental and clinical trials have

demonstrated MR reduction and reverse left ventricular remodeling. Using 3DE, Levine et al have shown that repositioning the posteroinferior PM with an epicardial patch reduces MR and tethering distance.⁵⁵ Messas et al⁵⁶⁻⁵⁸ proposed a technique that consisted of cutting the chordae tendinae that cause mitral leaflet tethering and displacement and thereby achieved similar results, although the clinical application has been more controversial.^{59,60} More studies are needed to demonstrate the efficacy of these new therapies.

Cardiac resynchronization therapy (CRT) is a therapeutic alternative in patients with advanced heart failure that is refractory to medical treatment^{61,62} and has been shown to reduce the degree of FMR.⁶³ However, its effects on mitral and ventricular geometry have not been demonstrated despite being a decisive factor in the development of MR. Preliminary results show that, in patients treated with CRT, a significant reduction in ventricular volumes occurs together with favorable changes in the spatial relation between the MV components and thereby a significant reduction in tenting volume.⁶⁴ Three-dimensional echocardiography could help improve the understanding the which mechanisms that lead to FMR reduction in patients receiving CRT and perhaps optimize the selection of patients that benefit most from this therapy.

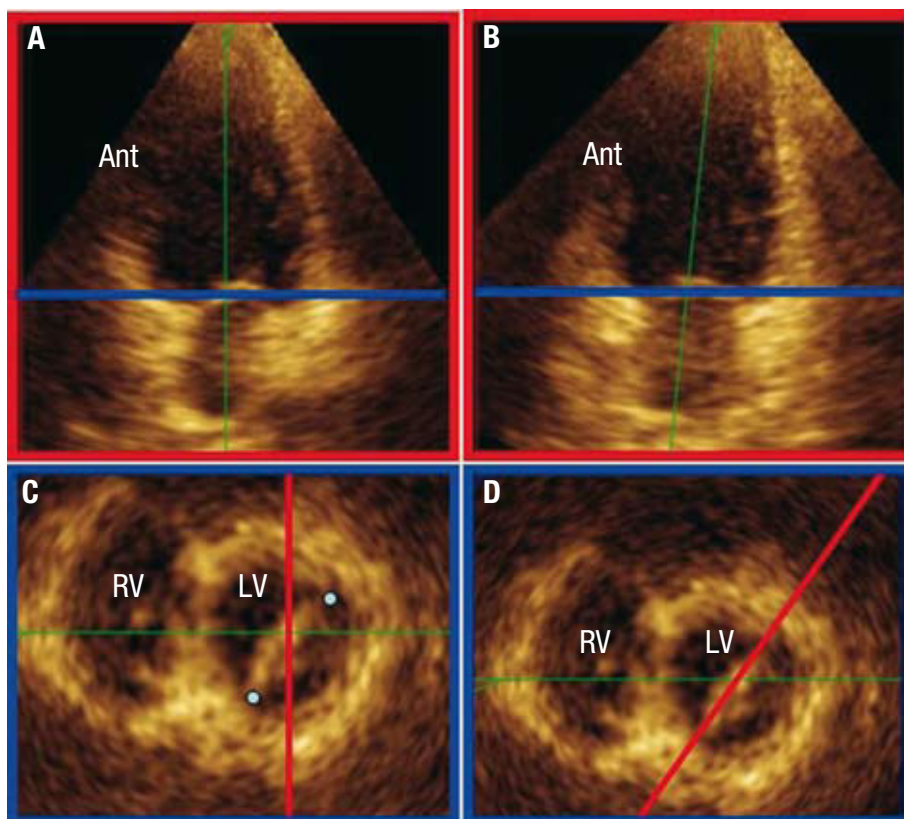


Figure 9. Using 3DE, we obtain more exact, reproducible measurements of the mitral geometry. The visualization of two simultaneous slices, A (sagittal) and C (transverse), enables us to see the error we make when we try to measure the intercommissure diameter of the mitral annulus (points). Reorienting these two planes, we obtain a sagittal slice (B) that runs through both mitral commissures (D). Ant indicates anterior; LV, left ventricle; RV, right ventricle.

TABLE 2. Parameters Measured With 3DE

Mitral annulus area in 3D
Tenting volume: between mitral annulus and mitral valvules
Mitral valvule surface
Tethering distance. From any point on the mitral annulus to the PM
Interpapillary distance
Ventricular volume in 3D
Sphericity index in 3D
Angle between the mitral valve and aortic valve
Angle between the different mitral valve components

PM indicates papillary muscles.

Implications of RT3DE in Percutaneous Treatment of Mitral Disease

The application of echocardiography in the cardiac catheterization laboratory has facilitated certain interventions and has allowed the timely detection of procedural complications. In recent years we have witnessed the incorporation of transesophageal and intracardiac 2DE in the catheterization laboratory for guidance of percutaneous procedures. Given the additional advantages of TERT3DE over existing echocardiographic modalities, the time is right for its use in the guidance of similar procedures. As mentioned earlier, RT3DE can also be especially useful in determining mitral valve area in patients with mitral stenosis and it could reliably be applied in percutaneous mitral valvuloplasty procedures. This is especially interesting if we consider how imprecise immediate, conventional non-invasive post-procedural techniques are.^{65,66} Similarly, TERT3DE could be of use in guiding the inter-atrial wall puncture needed in mitral device implantation. Three-dimensional visualization of the entire mitral annulus prosthesis in patients with periprosthetic leaks obviates the mental reconstruction necessary to localize their origin and, consequently, improves diagnostic precision. Although there is minimal scientific evidence to support it, the application of RT3DE may provide a great advance in the guidance of percutaneous closure procedures for periprosthetic leaks. Moreover, it will be able to guide MV procedures such as the Alfieri percutaneous repair technique⁶⁷ or mitral annuloplasty ring implantation via the coronary sinus.

CONCLUSIONS

The application of 3DE to the study of the MV contributes unique information about its functional anatomy that can be of great use in improving the knowledge and treatment of MV pathologies. Specifically, its application in the field of mitral

repair and in percutaneous interventions can contribute a substantial therapeutic advance in the coming years.

REFERENCES

- Dekker DL, Piziali RL, Dong E Jr. A system for ultrasonically imaging the human heart in three dimensions. *Comput Biomed Res.* 1974;7:544-53.
- Buck T, Hunold P, Wentz KU, Tkalec W, Nesser HJ, Erbel R. Tomographic three-dimensional echocardiographic determination of chamber size and systolic function in patients with left ventricular aneurysm: comparison to magnetic resonance imaging, cineventriculography, and two-dimensional echocardiography. *Circulation.* 1997;96:4286-97.
- Jacobs LD, Salgo IS, Goonewardena S, Weinert L, Coon P, Bardo D, et al. Rapid online quantification of left ventricular volume from real-time three-dimensional echocardiographic data. *Eur Heart J.* 2006;27:460-8.
- Vogel M, Gutberlet M, Dittrich S, Hosten N, Lange PE. Comparison of transthoracic three-dimensional echocardiography with magnetic resonance imaging in the assessment of right ventricular volume and mass. *Heart.* 1997;78:127-30.
- Ota T, Fleishman CE, Strub M, Stetten G, Ohazama CJ, von Ramm OT, et al. Real-time, three-dimensional echocardiography: feasibility of dynamic right ventricular volume measurement with saline contrast. *Am Heart J.* 1999;137:958-66.
- de Simone R, Glombitza G, Vahl CF, Albers J, Meinzer HP, Hagl S. Three-dimensional color Doppler: a clinical study in patients with mitral regurgitation. *J Am Coll Cardiol.* 1999;33:1646-54.
- de Simone R, Glombitza G, Vahl CF, Albers J, Meinzer HP, Hagl S. Three-dimensional color Doppler: a new approach for quantitative assessment of mitral regurgitant jets. *J Am Soc Echocardiogr.* 1999;12:173-85.
- Otsuji Y, Handschumacher MD, Schwammenthal E, Jiang L, Song JK, Guerrero JL, et al. Insights from three-dimensional echocardiography into the mechanism of functional mitral regurgitation: direct in vivo demonstration of altered leaflet tethering geometry. *Circulation.* 1997;96:1999-2008.
- Levine RA, Schwammenthal E. Ischemic mitral regurgitation on the threshold of a solution: from paradoxes to unifying concepts. *Circulation.* 2005;112:745-58.
- Otsuji Y, Handschumacher MD, Liel-Cohen N, Tanabe H, Jiang L, Schwammenthal E, et al. Mechanism of ischemic mitral regurgitation with segmental left ventricular dysfunction: three-dimensional echocardiographic studies in models of acute and chronic progressive regurgitation. *J Am Coll Cardiol.* 2001;37:641-8.
- Levine RA, Weyman AE, Handschumacher MD. Three-dimensional echocardiography: techniques and applications. *Am J Cardiol.* 1992;69:H121-30.
- Pai RG, Tanimoto M, Jintapakorn W, Azevedo J, Pandian NG, Shah PM. Volume-rendered three-dimensional dynamic anatomy of the mitral annulus using a transesophageal echocardiographic technique. *J Heart Valve Dis.* 1995;4:623-7.
- Watanabe N, Ogasawara Y, Yamaura Y, Wada N, Kawamoto T, Toyota E, et al. Mitral annulus flattens in ischemic mitral regurgitation: geometric differences between inferior and anterior myocardial infarction: a real-time 3-dimensional echocardiographic study. *Circulation.* 2005;112:1458-62.
- Levine RA, Handschumacher MD, Sanfilippo AJ, Hagege AA, Harrigan P, Marshall JE, et al. Three-dimensional echocardiographic reconstruction of the mitral valve, with implications for the diagnosis of mitral valve prolapse. *Circulation.* 1989;80:589-98.

15. Kaplan SR, Bashein G, Sheehan FH, Legget ME, Munt B, Li XN, et al. Three-dimensional echocardiographic assessment of annular shape changes in the normal and regurgitant mitral valve. *Am Heart J.* 2000;139:378-87.
16. Kwan J, Shiota T, Agler DA, Popovic ZB, Qin JX, Gillinov MA, et al. Geometric differences of the mitral apparatus between ischemic and dilated cardiomyopathy with significant mitral regurgitation: real-time three-dimensional echocardiography study. *Circulation.* 2003;107:1135-40.
17. Glasson JR, Komeda M, Daughters GT 2nd, Bolger AF, MacIsaac A, Oesterle SN, et al. Three-dimensional dynamics of the canine mitral annulus during ischemic mitral regurgitation. *Ann Thorac Surg.* 1996;62:1059-67.
18. Ahmad RM, Gillinov AM, McCarthy PM, Blackstone EH, Apperson-Hansen C, Qin JX, et al. Annular geometry and motion in human ischemic mitral regurgitation: novel assessment with three-dimensional echocardiography and computer reconstruction. *Ann Thorac Surg.* 2004;78:2063-8.
19. Salgo IS, Gorman JH 3rd, Gorman RC, Jackson BM, Bowen FW, Plappert T, et al. Effect of annular shape on leaflet curvature in reducing mitral leaflet stress. *Circulation.* 2002;106:711-7.
20. Calafiore AM, di Mauro M, Gallina S, di Giammarco G, Iaco AL, Teodori G, et al. Mitral valve surgery for chronic ischemic mitral regurgitation. *Ann Thorac Surg.* 2004;77:1989-97.
21. Daimon M, Shiota T, Gillinov AM, Hayase M, Ruel M, Cohn WE, et al. Percutaneous mitral valve repair for chronic ischemic mitral regurgitation: a real-time three-dimensional echocardiographic study in an ovine model. *Circulation.* 2005;111:2183-9.
22. Watanabe N, Ogasawara Y, Yamaura Y, Yamamoto K, Wada N, Kawamoto T, et al. Geometric differences of the mitral valve tenting between anterior and inferior myocardial infarction with significant ischemic mitral regurgitation: quantitation by novel software system with transthoracic real-time three-dimensional echocardiography. *J Am Soc Echocardiogr.* 2006;19:71-5.
23. Kumar N, Kumar M, Duran CM. A revised terminology for recording surgical findings of the mitral valve. *J Heart Valve Dis.* 1995;4:70-5.
24. Hung J, Guerrero JL, Handschumacher MD, Supple G, Sullivan S, Levine RA. Reverse ventricular remodeling reduces ischemic mitral regurgitation: echo-guided device application in the beating heart. *Circulation.* 2002;106:2594-600.
25. Kumanohoso T, Otsuji Y, Yoshifuku S, Matsukida K, Koriyama C, Kisanuki A, et al. Mechanism of higher incidence of ischemic mitral regurgitation in patients with inferior myocardial infarction: quantitative analysis of left ventricular and mitral valve geometry in 103 patients with prior myocardial infarction. *J Thorac Cardiovasc Surg.* 2003;125:135-43.
26. Vandervoort PM, Rivera JM, Mele D, Palacios IF, Dinsmore RE, Weyman AE, et al. Application of color Doppler flow mapping to calculate effective regurgitant orifice area. An in vitro study and initial clinical observations. *Circulation.* 1993;88:1150-6.
27. Enriquez-Sarano M, Miller FA Jr, Hayes SN, Bailey KR, Tajik AJ, Seward JB. Effective mitral regurgitant orifice area: clinical use and pitfalls of the proximal isovelocity surface area method. *J Am Coll Cardiol.* 1995;25:703-9.
28. Sitges M, Jones M, Shiota T, Qin JX, Tsujino H, Bauer F, et al. Real-time three-dimensional color doppler evaluation of the flow convergence zone for quantification of mitral regurgitation: Validation experimental animal study and initial clinical experience. *J Am Soc Echocardiogr.* 2003;16:38-45.
29. Yosefy C, Levine RA, Solis J, Vaturi M, Handschumacher MD, Hung J. Proximal flow convergence region as assessed by real-time 3-dimensional echocardiography: challenging the hemispheric assumption. *J Am Soc Echocardiogr.* 2007;20:389-96.
30. Matsumura Y, Fukuda S, Tran H, Greenberg NL, Agler DA, Wada N, et al. Geometry of the proximal isovelocity surface area in mitral regurgitation by 3-dimensional color Doppler echocardiography: difference between functional mitral regurgitation and prolapse regurgitation. *Am Heart J.* 2008;155:231-8.
31. Hatle L, Brubakk A, Tromsdal A, Angelsen B. Noninvasive assessment of pressure drop in mitral stenosis by Doppler ultrasound. *Br Heart J.* 1978;40:131-40.
32. Brubakk AO, Angelsen BA, Hatle L. Diagnosis of valvular heart disease using transcutaneous Doppler ultrasound. *Cardiovasc Res.* 1977;11:461-9.
33. Nakatani S, Masuyama T, Kodama K, Kitabatake A, Fujii K, Kamada T. Value and limitations of Doppler echocardiography in the quantification of stenotic mitral valve area: comparison of the pressure half-time and the continuity equation methods. *Circulation.* 1988;77:78-85.
34. Fredman CS, Pearson AC, Labovitz AJ, Kern MJ. Comparison of hemodynamic pressure half-time method and Gorlin formula with Doppler and echocardiographic determinations of mitral valve area in patients with combined mitral stenosis and regurgitation. *Am Heart J.* 1990;119:121-9.
35. Smith MD, Wisenbaugh T, Grayburn PA, Gurley JC, Spain MG, DeMaria AN. Value and limitations of Doppler pressure half-time in quantifying mitral stenosis: a comparison with micromanometer catheter recordings. *Am Heart J.* 1991;121:480-8.
36. Nichol PM, Gilbert BW, Kisslo JA. Two-dimensional echocardiographic assessment of mitral stenosis. *Circulation.* 1977;55:120-8.
37. Wann LS, Weyman AE, Feigenbaum H, Dillon JC, Johnston KW, Eggleton RC. Determination of mitral valve area by cross-sectional echocardiography. *Ann Intern Med.* 1978;88:337-41.
38. Faletra F, Pezzano A Jr, Fusco R, Mantero A, Corno R, Crivellaro W, et al. Measurement of mitral valve area in mitral stenosis: four echocardiographic methods compared with direct measurement of anatomic orifices. *J Am Coll Cardiol.* 1996;28:1190-7.
39. Binder TM, Rosenhek R, Porenta G, Maurer G, Baumgartner H. Improved assessment of mitral valve stenosis by volumetric real-time three-dimensional echocardiography. *J Am Coll Cardiol.* 2000;36:1355-61.
40. Sebag IA, Morgan JG, Handschumacher MD, Marshall JE, Nesta F, Hung J, et al. Usefulness of three-dimensionally guided assessment of mitral stenosis using matrix-array ultrasound. *Am J Cardiol.* 2005;96:1151-6.
41. de Agustin JA, Nanda NC, Gill EA, De Isla LP, Zamorano JL. The use of three-dimensional echocardiography for the evaluation of and treatment of mitral stenosis. *Cardiol Clin.* 2007;25:311-8.
42. Sugeng L, Coon P, Weinert L, Jolly N, Lammertin G, Bednarsz JE, et al. Use of real-time 3-dimensional transthoracic echocardiography in the evaluation of mitral valve disease. *J Am Soc Echocardiogr.* 2006;19:413-21.
43. Sharma R, Mann J, Drummond L, Livesey SA, Simpson IA. The evaluation of real-time 3-dimensional transthoracic echocardiography for the preoperative functional assessment of patients with mitral valve prolapse: a comparison with 2-dimensional transesophageal echocardiography. *J Am Soc Echocardiogr.* 2007;20:934-40.
44. Pepi M, Tamborini G, Maltagliati A, Galli CA, Sisillo E, Salvi L, et al. Head-to-head comparison of two- and three-dimensional transthoracic and transesophageal echocardiography in the localization of mitral valve prolapse. *J Am Coll Cardiol.* 2006;48:2524-30.
45. Macnab A, Jenkins NP, Bridgewater BJ, Hooper TL, Greenhalgh DL, Patrick MR, et al. Three-dimensional echocardiography is superior to multiplane transoesophageal echo in the assessment of regurgitant mitral valve morphology. *Eur J Echocardiogr.* 2004;5:212-22.

46. Fabricius AM, Walther T, Falk V, Mohr FW. Three-dimensional echocardiography for planning of mitral valve surgery: current applicability? *Ann Thorac Surg.* 2004;78:575-8.
47. Foster GP, Isselbacher EM, Rose GA, Torchiana DF, Akins CW, Picard MH. Accurate localization of mitral regurgitant defects using multiplane transesophageal echocardiography. *Ann Thorac Surg.* 1998;65:1025-31.
48. Gillinov AM, Cosgrove DM 3rd, Shiota T, Qin J, Tsujino H, Stewart WJ, et al. Cosgrove-Edwards Annuloplasty System: midterm results. *Ann Thorac Surg.* 2000;69:717-21.
49. Calafiore AM, Gallina S, Di Mauro M, Gaeta F, Iaco AL, D'Alessandro S, et al. Mitral valve procedure in dilated cardiomyopathy: repair or replacement? *Ann Thorac Surg.* 2001;71:1146-52.
50. Tahta SA, Oury JH, Maxwell JM, Hiro SP, Duran CM. Outcome after mitral valve repair for functional ischemic mitral regurgitation. *J Heart Valve Dis.* 2002;11:11-8.
51. Hung J, Papakostas L, Tahta SA, Hardy BG, Bollen BA, Duran CM, et al. Mechanism of recurrent ischemic mitral regurgitation after annuloplasty: continued LV remodeling as a moving target. *Circulation.* 2004;110:II85-90.
52. Yamaura Y, Yoshikawa J, Yoshida K, Hozumi T, Akasaka T, Okada Y. Three-dimensional analysis of configuration and dynamics in patients with an annuloplasty ring by multiplane transesophageal echocardiography: comparison between flexible and rigid annuloplasty rings. *J Heart Valve Dis.* 1995;4:618-22.
53. Yamaura Y, Hozumi T, Akasaka T, Okada Y, Yoshikawa J. Three-dimensional echocardiographic evaluation of configuration and dynamics of the mitral annulus in patients fitted with an annuloplasty ring. *J Heart Valve Dis.* 1997;6:43-7.
54. Yamaura Y, Yoshida K, Hozumi T, Akasaka T, Morioka S, Yoshikawa J. Evaluation of the mitral annulus by extracted three-dimensional images in patients with an annuloplasty ring. *Am J Cardiol.* 1998;82:534-6.
55. Hung J, Chaput M, Guerrero JL, Handschumacher MD, Papakostas L, Sullivan S, et al. Persistent reduction of ischemic mitral regurgitation by papillary muscle repositioning: structural stabilization of the papillary muscle-ventricular wall complex. *Circulation.* 2007;116:I259-63.
56. Messas E, Yosefy C, Chaput M, Guerrero JL, Sullivan S, Menasche P, et al. Chordal cutting does not adversely affect left ventricle contractile function. *Circulation.* 2006;114:I524-8.
57. Messas E, Pouzet B, Touchot B, Guerrero JL, Vlahakes GJ, Desnos M, et al. Efficacy of chordal cutting to relieve chronic persistent ischemic mitral regurgitation. *Circulation.* 2003;108 Suppl 1:111-5.
58. Messas E, Guerrero JL, Handschumacher MD, Conrad C, Chow CM, Sullivan S, et al. Chordal cutting: a new therapeutic approach for ischemic mitral regurgitation. *Circulation.* 2001;104:1958-63.
59. Rodriguez F, Langer F, Harrington KB, Tibayan FA, Zasio MK, Liang D, et al. Effect of cutting second-order chordae on in-vivo anterior mitral leaflet compound curvature. *J Heart Valve Dis.* 2005;14:592-601.
60. Rodriguez F, Langer F, Harrington KB, Tibayan FA, Zasio MK, Liang D, et al. Cutting second-order chords does not prevent acute ischemic mitral regurgitation. *Circulation.* 2004;110:II91-7.
61. Cleland JG, Daubert JC, Erdmann E, Freemantle N, Gras D, Kappenberger L, et al. The effect of cardiac resynchronization on morbidity and mortality in heart failure. *N Engl J Med.* 2005;352:1539-49.
62. Breithardt OA, Sinha AM, Schwammenthal E, Bidaoui N, Markus KU, Franke A, et al. Acute effects of cardiac resynchronization therapy on functional mitral regurgitation in advanced systolic heart failure. *J Am Coll Cardiol.* 2003;41:765-70.
63. Lancellotti P, Melon P, Sakalihan N, Waleffe A, Dubois C, Bertholet M, et al. Effect of cardiac resynchronization therapy on functional mitral regurgitation in heart failure. *Am J Cardiol.* 2004;94:1462-5.
64. Vidal B MS, Delgado V, Mont L, Tolosana JM, Pérez-Villa F, Azqueta M, et al. Impact of cardiac resynchronisation therapy on mitral valve geometry: implications for mitral regurgitation reduction in patients with heart failure. *Eur Heart J Suppl.* 2007;27:869.
65. Reid CL, Rahimtoola SH. The role of echocardiography/Doppler in catheter balloon treatment of adults with aortic and mitral stenosis. *Circulation.* 1991;84:I240-9.
66. Thomas JD, Wilkins GT, Choong CY, Abascal VM, Palacios IF, Block PC, et al. Inaccuracy of mitral pressure half-time immediately after percutaneous mitral valvotomy. Dependence on transmitral gradient and left atrial and ventricular compliance. *Circulation.* 1988;78:980-93.
67. Agrawal R, Rangasetty UC, Kollar A, Tuero E, Ahmad M. Live three-dimensional echocardiography in evaluation of Alfieri mitral valve repair a case report. *Echocardiography.* 2008;25:214-6.