

# Chronic Prosthetic Valve Endocarditis Due to *Propionibacterium acnes*: An Unexpected Cause of Prosthetic Valve Dysfunction

Laura Guío,<sup>a</sup> Cristina Sarriá,<sup>a</sup> Carmen de las Cuevas,<sup>b</sup> Carlos Gamallo,<sup>c</sup> and Juan Duarte<sup>d</sup>

<sup>a</sup>Servicio de Medicina Interna, Enfermedades Infecciosas, Hospital de La Princesa, Madrid, Spain

<sup>b</sup>Servicio de Microbiología, Hospital de La Princesa, Madrid, Spain

<sup>c</sup>Servicio de Anatomía Patológica, Hospital de La Princesa, Madrid, Spain

<sup>d</sup>Servicio de Cirugía Cardíaca, Hospital de La Princesa, Madrid, Spain

**Introduction and objectives.** To determine the characteristics of *Propionibacterium acnes* prosthetic valve endocarditis (PAPVE).

**Methods.** Prospective descriptive study of 16 consecutive cases of PAPVE.

**Results.** Seven patients developed PAPVE early and 9 developed it late. In all those who developed PAPVE late, there was a history of mucocutaneous barrier manipulation. The delay in diagnosis was >3 months in 75%. The clinical presentation was asymptomatic prosthetic valve dysfunction in 31%, heart failure in 19%, coronary syndrome in 12.5%, fever in 25%, and neurological deficits in 19%. At diagnosis, 62.5% had heart failure and 44% had fever. The predominant echocardiographic finding was prosthesis dysfunction due to dehiscence of metallic aortic valves (6 out of 7) or stenosis of metallic mitral valves (4 out of 7). In 2 of the 3 biological aortic prostheses, dysfunction was due to leaflet distortion. Blood cultures and surgical specimens tested positive after a mean of 11.6 and 12.2 days, respectively. In 2 cases, the diagnosis was confirmed by PCR. The principle intraoperative finding was the presence of abundant grayish pannus. Histology demonstrated the absence of acute inflammatory features. Twelve patients received antibiotic treatment with valve replacement: 7 were cured, 4 experienced early prosthesis dehiscence and 1 relapsed. All 3 patients who were initially treated with antibiotics alone suffered relapses.

**Conclusions.** Generally, PAPVE presents as prosthetic valve dysfunction with few symptoms of infection. Prolonged incubation of cultures is essential for diagnosis. Antibiotic treatment provides clinical control but does not eradicate the infection, and valve replacement is necessary for a cure. The postoperative course can be complicated by prosthesis dehiscence.

**Key words:** Biofilm. Prosthetic valve endocarditis. *Propionibacterium acnes*.

Correspondence: Dra. L. Guío Carrión.  
Servicio de Medicina Interna-Infecciosas. Hospital de La Princesa.  
Diego de León, 62. 28006 Madrid. España.  
E-mail: lauraguio@hotmail.com

Received February 12, 2008.

Accepted for publication November 6, 2008.

## Endocarditis crónica sobre válvula protésica por *Propionibacterium acnes*: una causa insospechada de disfunción protésica

**Introducción y objetivos.** Describir las características de la endocarditis infecciosa sobre válvula protésica por *Propionibacterium acnes* (EIVPPA)

**Métodos.** Descripción prospectiva y consecutiva de 16 casos de EIVPPA.

**Resultados.** Siete pacientes presentaron EIVPPA precoz y 9 tardías. Las tardías siempre tenían el antecedente de algún tipo de manipulación de la barrera mucocutánea. El retraso diagnóstico fue > 3 meses en el 75%. La presentación clínica fue fundamentalmente disfunción protésica asintomática (31%), insuficiencia cardíaca (19%), síndrome coronario (12,5%), fiebre (25%) y déficits neurológicos (19%). Al ingreso diagnóstico el 62,5% presentaba insuficiencia cardíaca y el 44% fiebre. Eco-cardiográficamente, predominó la disfunción protésica por dehiscencia en las metálicas aórticas (6 de 7), o por estenosis en las metálicas mitrales (4 de 7). Las biológicas presentaron disfunción por distorsión de velos (2 de 3). Los cultivos de sangre y muestras quirúrgicas fueron positivos tras 11,6 y 12,2 días de media, respectivamente. En 2 casos la PCR confirmó el diagnóstico. El hallazgo intraoperatorio principal fue la presencia de abundante pannus grisáceo. La histología mostró ausencia de datos de actividad aguda. Doce pacientes recibieron antibioterapia más recambio valvular, 7 curaron, 4 presentaron dehiscencia precoz y 1, recaída; 3 pacientes fueron inicialmente tratados sólo con antibióticos, y los 3 recayeron.

**Conclusiones.** La EIVPPA se presenta generalmente con disfunción valvular y escasos síntomas infecciosos. Es imprescindible la larga incubación de los cultivos para su diagnóstico. La antibioterapia controla la clínica, pero no elimina la infección, y es necesaria la sustitución valvular para la curación. La evolución posquirúrgica puede verse complicada por la presencia de dehiscencia protésica.

**Palabras clave:** Endocarditis protésica. *Propionibacterium acnes*. Biocapa.

## ABBREVIATIONS

IE: infective endocarditis

PAPVE: *Propionibacterium acnes* prosthetic valve endocarditis

PCR: polymerase chain reaction

SOT: suppressive oral therapy

## INTRODUCTION

*Propionibacterium acnes* is a gram-positive anaerobic bacillus that is part of the normal flora of several mucous membranes, including oral and intestinal. It also colonizes the skin, where it predominates in pilosebaceous follicles, especially in the face, scalp, and upper trunk. It is a microorganism of low virulence, and has previously been classified as a contaminant of microbiological specimens. However, it has been demonstrated that it is involved in serious infections of prosthetic material, such as prosthetic cardiac valves and other intracardiac devices.<sup>1-23</sup>

Given this is a slow-growing bacterium, if blood cultures or surgical specimens are not incubated over a long period, it may fail to be isolated<sup>6,10,11,13,25</sup>; sometimes its presence in tissues can only be confirmed by molecular biology techniques (polymerase chain reaction [PCR]).<sup>11,12</sup>

Only 36 cases of prosthetic valve infective endocarditis due to *P acnes* (PAPVE) have been described in the literature. Most of these were isolated cases or mostly retrospective series and did not address all the aspects of the disease.

This article presents a prospective study of 16 consecutive cases of PAPVE. The majority of the patients had similar clinical, echocardiographic, microbiologic, and anatomic characteristics unlike those normally encountered.

## METHODS

A total of 16 definite cases of PAPVE (14 diagnosed in our hospital) were collected prospectively, consecutively, and concurrently between 1991 and 2006, using a questionnaire with defined variables. They represented 4.3% of the cases of endocarditis diagnosed at our hospital during this period. Surgical endocarditis acquired during intervention was suspected in 9, and in all patients histology was compatible with endocarditis and culture was positive for *P acnes*. In order to describe the aspects

of the disease course, the data are grouped into 3 periods: from symptom onset to diagnosis; during diagnostic admission; and until the end of follow-up (until 5 years; median, 3 years).

## Procedures

**Echocardiographic:** at least 1 echocardiographic exploration was conducted in all patients.

**Microbiologic and anatomicopathologic:** at least 3 blood cultures were obtained at admission if infective endocarditis (IE) was suspected. The macroscopic aspect of the valves was described by the surgeon at the time of valve replacement. Surgical specimens, prostheses, and periprosthetic tissue underwent microbiologic analysis in aseptic conditions and were assessed by the pathologist. The prostheses, and part of the vegetations and periprosthetic tissue, were prepared for culture; the tissues were triturated in a mortar prior to incubation. Part of the periprosthetic tissue, vegetations and pannus underwent histological analysis. All cultures were incubated for an extended period (30 days).

**Real-time PCR:** *P acnes* DNA was detected by real-time PCR in 11 episodes: in 9 cases, DNA was extracted from periprosthetic tissue specimens preserved in paraffin, and in 3 cases DNA was extracted from fresh tissue.

## Definitions

**Diagnostic delay:** time from onset of the first symptom until diagnosis.

**Form of presentation:** first symptoms or signs which the patient presented at first consultation, whether or not this corresponded to admission.

## RESULTS

### Epidemiology

The mean age was 59.4 years (range, 41-78 years); 13 patients were men; 13 had received mechanical prostheses and 3 had received biological prostheses. The time between prosthesis implantation and symptom onset ranged between 1 week and 27 years: in 7 patients this period was  $\leq 1$  year and in 9 patients it was  $> 8$  years. In the first group, a possible entry point for *P acnes* that differed from valve replacement surgery was detected in only 1 patient. However, in the second group there was always a possible risk factor associated with mucocutaneous barrier manipulation (Table 1). Three patients had previous IE: 1 case was due to *Streptococcus pneumoniae*, 1 was due to *Staphylococcus epidermidis*, and in the third case the culture was negative.

**TABLE 1. Epidemiology, Clinical Characteristics, and Course of 16 Cases of Prosthetic Infective Endocarditis Due to *Propionibacterium acnes***

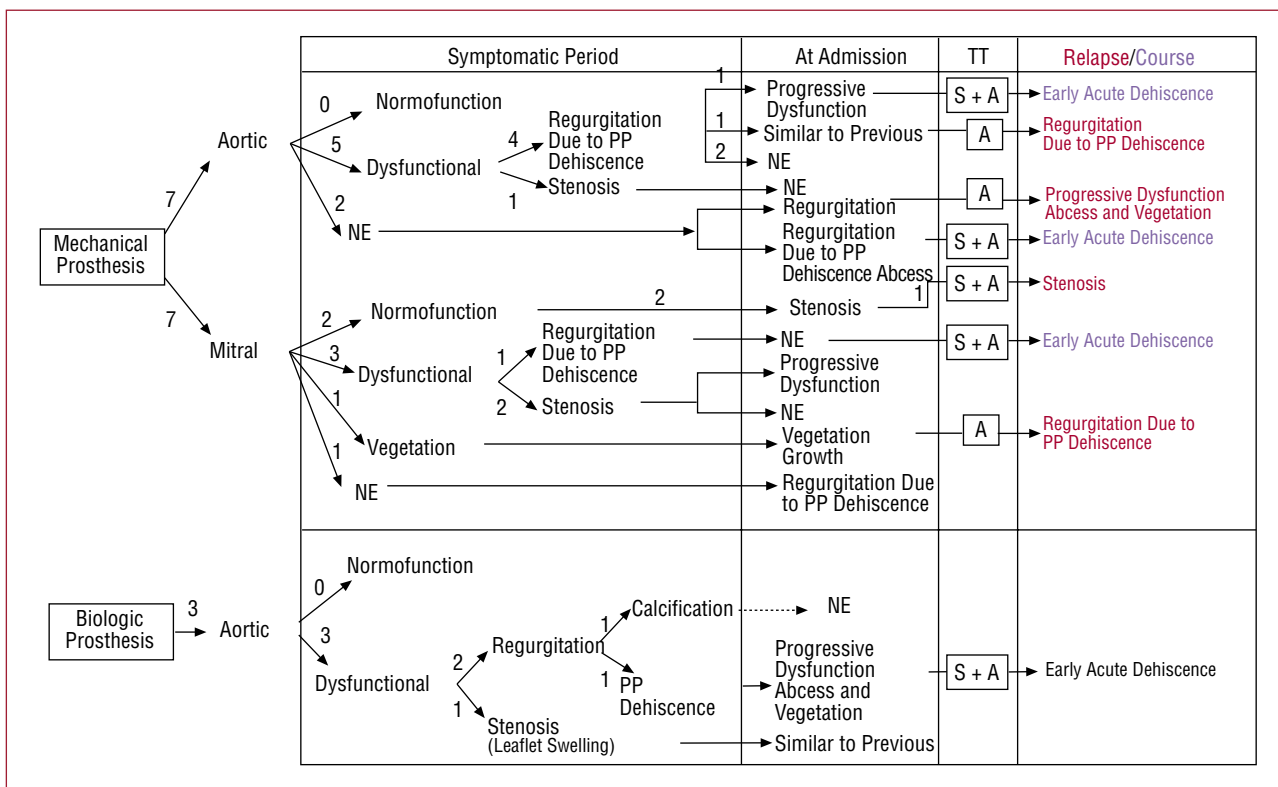
Case	Underlying Disease	Type of Prosthesis	Time From Implantation to Symptom Onset	Risk Factor (Time From Event to Symptom Onset)	Clinical Presentation	Diagnostic Delay	Symptoms and Signs at Diagnostic Admission	Time to Relapse	Relapses		Course
									Diagnostic Delay	Symptoms and Signs	
1	Hepatopathy due to HCV, hypothyroidism	St Jude mechanical aortic + aortic valve conduit	1 y	Dental cleaning (5 mo)	Fever. Neurological	3 d	Fever, TIA, new murmur	24 mo	4 mo	Fever, shivering, myositis, acute hemorrhagic stroke	Death during second relapse (in the operating room)
2	-	Carpentier biologic aortic	11 mo	-	Asymptomatic severe prosthetic dysfunction	22 mo	Fever, shivering, pleuritic pain, new murmur	2 mo	17 mo	Recurrent polyarthritis, peripheral neuropathy, peripheral embolisms, mycotic aneurysms, splenic infarctions, myositis	Death (severe prosthetic dehiscence, death in operating room) Asymptomatic
3	-	Carbomedics mechanical mitral	8 y	Polypectomy (1 y)	Neurological	5 y	CHF, TIA, splenomegaly, reduced prosthetic noise	-	-	-	Acute carotid stroke 2 y later
4	-	Mechanical mitral + aortic (both Omnicarbon)	9 y and 3 mo	Rose thorn puncture, indolent course (5 mo)	Constitutional syndrome, fever	12 mo	CHF, fever, asthenia, new murmur	-	-	-	Asymptomatic
5	Bladder cancer, obstructive CRF	Donald-Ros biologic aortic	8 y and 9 mo	Ureteroileal anastomosis (9 y)	Cardiologic (angina due to AoR)	3 mo	CHF, angina, new murmur	-	-	-	Asymptomatic
6	CRF Chronic anemia	Carbomedics mechanical aortic	1 wk	-	Cutaneous	7 mo	Fever, shivering, CHF, new murmur, painful necrotic lesions with livedo reticularis in pads of the fingers	10 mo	2 mo	Fever, necrotic lesions, CHF, abdominal pain, nephrotic proteinuria, progressive kidney failure, antiphospholipid syndrome	Death 2 y later (sudden death at home)
7	CRF	Mechanical mitral + aortic (both Sorin)	4 mo	-	Asymptomatic severe prosthetic dysfunction	2 y	CHF, fever, new murmur, syncope	-	-	-	CHF New IE (reinfection)
8	-	St Jude mechanical aortic	13 y	Discectomy C5-C6 (6 mo). Mesotherapy (1 mo). Recurrent anal fissure	Constitutional syndrome, fever	7 mo	Fever, sweating, asthenia, new murmur	1 mo	5 mo	Asthenia, fever, sweating, constitutional syndrome	Asymptomatic

Continues on Following Page

**TABLE 1. Epidemiology, Clinical Characteristics, and Course of 16 Cases of Prosthetic Infective Endocarditis Due to *Propionibacterium acnes* (Continued)**

Case	Underlying Disease	Type of Prosthesis	Time From Implantation to Symptom Onset	Risk Factor (Time From Event to Symptom Onset)	Clinical Presentation	Diagnostic Delay	Symptoms and Signs at Diagnostic Admission	Time to Relapse	Relapses		Course
									Diagnostic Delay	Symptoms and Signs	
9	COPD CRF	Carbomedics mechanical aortic	5 wk	–	Asymptomatic severe prosthetic dysfunction	5 wk	CHF, new murmur	–	–	–	Acute prosthetic dehiscence (at 8 mo), negative culture Acute prosthetic dehiscence (at 4 mo), CHF Cardiac transplant Asymptomatic
10	CRF	Carpentier biologic aortic	4 mo	–	Cardiologic (cardioembolic AMI) Asymptomatic severe prosthetic dysfunction	1 mo	Angina, new murmur	–	–	–	Asymptomatic
11	–	Carbomedics mechanical mitral	11 y	Acute cholecystitis (12 mo) Osteosynthesis in leg (6 y)	Asymptomatic severe prosthetic dysfunction	6 mo	Palpitations, new murmur	–	–	–	Asymptomatic
12	Type 2 DM	Björk mechanical aortic	19 y	Hyperpigmented lesion resection in leg (2 y)	Cardiologic (CHF)	12 mo	CHF	–	–	–	Asymptomatic
13	Psoriatic arthritis	Mechanical mitral + aortic (both Sorin)	4 y	Psoriatic onychopathy Recurrent infiltrations due to tenosynovitis (for 7 y)	Neurological, fever, rheumatic manifestations	15 y	Acute stroke, fever, asthenia, CHF, arthralgia, myalgia, new murmur	2 y	3 wk	Acute stroke, fever	Asymptomatic
14	COPD Endometrial adenocarcinoma	Sorin mechanical mitral	3 mo	–	Asymptomatic severe prosthetic dysfunction	3 mo	New murmur	–	–	–	Asymptomatic
15	Type 2 DM	Omnicarbon mechanical mitral	11 y	Pacemaker implantation (5 y)	Cardiologic (CHF)	2 wk	New murmur, CHF	–	–	–	Death due to postsurgical repeat acute stroke
16	–	Mechanical mitral and aortic (Björk)	27 y	Varicose vein surgery (1 mo)	Cardiologic (CHF)	5 mo	New murmur, CHF	–	–	–	Prosthetic dehiscence, severe mitral regurgitation

AMI indicates acute myocardial infarction; AoR, aortic regurgitation; CHF, congestive heart failure; COPD, chronic obstructive pulmonary disease; CRF, chronic renal failure; DM, diabetes mellitus; TIA, transient ischemic accident.



**Figure 1.** Echocardiographic findings of 16 cases of prosthetic valve infective endocarditis due to *Propionibacterium acnes* during its clinical course. The main echocardiographic findings are shown for the symptomatic period, at the time of diagnosis, and during relapse, if this occurred (shown in red). Similarly, cases that presented early prosthetic dehiscence during follow-up are indicated (shown in blue). In all cases, the type of treatment is specified. In the other patients valves were replaced and echocardiographic exploration after treatment was normal. A indicates antibiotic treatment; NE, echocardiogram not obtained; PP, periprosthetic; S, surgical treatment; TT, treatment.

### Clinical Characteristics

The clinical characteristics of the patients (Table 1) included the following: asymptomatic severe prosthetic dysfunction (31%), heart failure (19%), coronary syndrome (12.5%), fever (25%), fever associated with constitutional syndrome (12.5%), fever associated with neurological symptoms (12.5%), recurrent ischemic neurological events without fever (6.2%), cutaneous manifestations (6.2%) (livedo reticularis and necrotic lesions on the pads of the fingers), and rheumatic manifestations (6.2%) (arthromyalgia and repeat tenosynovitis).

In 8 patients, the clinical symptoms had led to hospital admission without reaching a diagnosis of IE (median of previous admissions, 1 [1-6]). In 2 patients, the affected valve was replaced due to suspected IE, and although this diagnosis was ruled out the surgical specimens did not undergo prolonged incubation. Both patients presented periprosthetic valve dehiscence very shortly after replacement.

At diagnostic admission, heart failure was present in 62.5% of patients, fever in 43.7% (2 had presented as asymptomatic prosthetic dysfunction), new murmur in 81.2%, reduction of prosthetic noise in 6.2%, and splenomegaly in 6.2%. Diagnostic delay was <1 month in 3 patients, between 1 and 12 months in 9, and >12 months in 4.

If relapse occurred the clinical manifestations were usually similar to those of their first episode, except in patient 1, who initially developed very typical rheumatic symptomatology and, subsequently, other peripheral manifestations before a diagnosis was reached during the first and second relapse.

### Echocardiography

During the period prior to diagnosis, 14 transthoracic echocardiograms and 4 transesophageal echocardiograms were performed in 13 patients (Figure 1). A total of 71.4% of the mechanical aortic prostheses were dysfunctional: 57% due to dehiscence and 14.2% due to stenosis. A total of 42.8% of the

**TABLE 2. Microbiology and Real-Time Polymerase Chain Reaction in 16 Cases of Prosthetic Valve Infective Endocarditis Due to *Propionibacterium acnes* During Their Clinical Course**

Case	Symptomatic Period		Diagnostic Admission			Relapse		
	BC	Prosthesis Culture	BC (No. D)	Prosthesis Culture (No. D)	PCR	BC (No. D)	Prosthesis Culture (No. D)	PCR
				Type of Sample (No. S)	Result			Sample Result
1			6/6+ (9th)			1 6/6 – 2 6/6 –	+ <i>P acnes</i> (28th)	
2	Negative		6/6 –	+ <i>P acnes</i> PFN	PFN	Negative	–	
3				+ <i>P acnes</i>	PFN	Negative	–	
4					+ <i>P acnes</i> (6th)	PFN	Negative	–
5				1/6 + (12th)	+ <i>P acnes</i> (12th)	PFN	Negative	–
6			2/3 + (12th)				6/6 –	+ <i>Staphylococcus auricularis</i> + 1 other <sup>a</sup> (21st)
7				+ <i>P acnes</i>	PFN	Negative	–	
8	1/6+		3/3+				5/6 + (12th)	Negative
9			6/6–	+ <i>P acnes</i>	PFN	Negative	–	
10					+ <i>P acnes</i>	PFN	Negative	–
11					+ <i>P acnes</i> (14th)	PFN	Negative	–
12					+ <i>P acnes</i> (5th)	PFN	Negative	–
13					+ <i>P acnes</i> (7th)	PFN	Negative	1/3 + (5th)
14					Prosthesis: negative	FT (1)	Negative	–
						FT (2)	+ <i>P acnes</i>	
15			3/3 –	Thrombus: + <i>P acnes</i>	FT	+ <i>P acnes</i>	–	
16				+ <i>P acnes</i> (30th)	FT	+ <i>P acnes</i>	–	
				+ <i>P acnes</i> (7th)			–	

BC+ indicates blood culture positive for *P acnes*; BC–, sterile blood culture; FT, fresh tissue; No. D, day on which culture specimens (blood or valve) proved positive when data were available; No. S, number of specimens; PFN, sample in paraffin.

<sup>a</sup>A microorganism morphologically similar to *P acnes* which finally could not be identified.

mechanical mitral prostheses were dysfunctional: 28.5% due to stenosis and 14.2% due to failure; in 14.2% vegetations were detected without prosthetic dysfunction. All the biological aortic prostheses were dysfunctional. This was due to dehiscence in 33.3%, and distorted leaflets in 66.6%: 33.3% due to calcification leading to failure, and 33.3% due to thickening with stenotic-like behavior.

At diagnostic admission, echocardiograms were repeated in 8 patients, and a first echocardiogram in 3. In the first group, there was prosthetic dysfunction progression in 37.5% (1 with vegetations and abscesses), vegetation growth (12.5%), new prosthetic dysfunction (25%), and no change (25%). In all of the first echocardiograms, failure was identified by periprosthetic dehiscence, which was associated with abscess in 1 patient.

At relapse, 66.6% of the patients who had not undergone surgery presented progression of the previous prosthetic dehiscence and 33.3%, a new dehiscence. The patient who underwent relapse after valve replacement presented the same prosthetic dysfunction as in the first episode (stenosis).

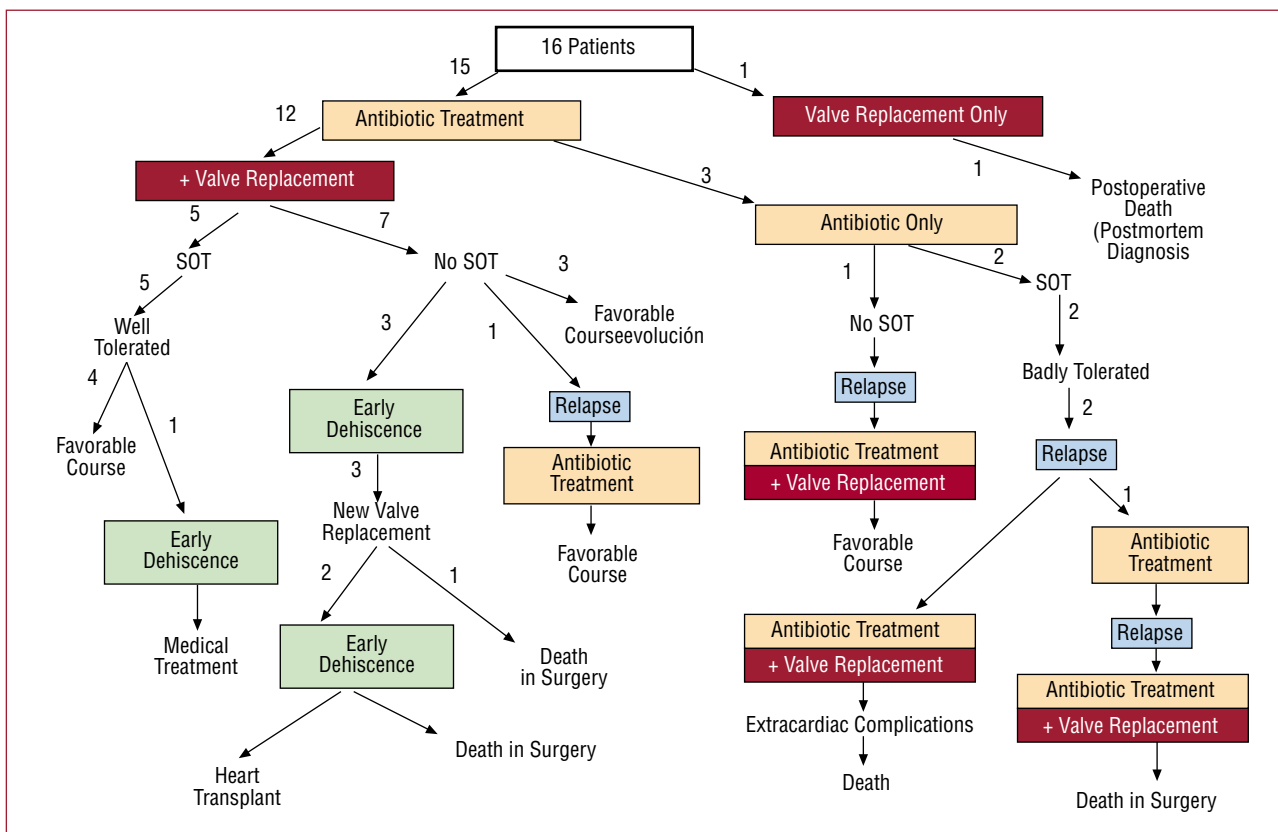
## Microbiology

During the symptomatic period prior to diagnosis, blood samples were taken from 2 patients and cultured. In 1 patient *P acnes* was objectified in 1 of 6 blood cultures (Table 2).

At diagnostic admission, blood cultures were taken from 7 patients and cultured; 4 were positive for *P acnes*, with a mean growth time of 11.6 (5-21) days. These were sterile in 3 patients who were all receiving antibiotic treatment. Surgical specimens were obtained from 13 patients. In all 13, *P acnes* was isolated, with a mean average growth time of 12.2 (5-30) days. In 1 case, *P acnes* only grew in the prosthetic valve thrombus and that underwent cultivation at the same time as the prosthesis.

The 4 relapses were microbiologically documented. In 2 cases, blood cultures were positive for *P acnes* and in 2 the surgical specimens were positive for *P acnes*.

Real-time PCR failed to detect the presence of *P acnes* DNA in any of the specimens preserved in paraffin. However, it was successful in the 2 cases



**Figure 2.** Treatment and course in 16 cases of prosthetic valve infective endocarditis due to *Propionibacterium acnes*. SOT indicates suppressive oral therapy.

where fresh specimens were used, although it was not detected in all the fragments.

### Treatment and Course

Initially, 18.7% of the patients received antibiotic therapy only and 75%, antibiotic therapy and surgery. One patient only underwent surgery, since diagnosis was performed postmortem (Figure 2).

The antibiotics used were penicillin (40%), third-generation cephalosporins (26.6%), vancomycin in monotherapy (6.6%) or in combination with aminoglycosides (20%), or other antibiotics (6.6%). The duration of parenteral treatment was  $\geq 6$  weeks. Suppressive oral therapy (SOT) with amoxicillin was also administered to 2 patients who had not undergone surgery, and to 5 in whom surgical cleaning was incomplete or antibiotic treatment had not begun immediately after valve replacement (Figure 3).

A total of 58.3% of patients who received combination treatment had a favorable course, 8.3% underwent relapse and 33.3% presented early dehiscence (one finally required cardiac transplant). All the patients who had initially received antibiotic treatment only underwent intervention due to relapse

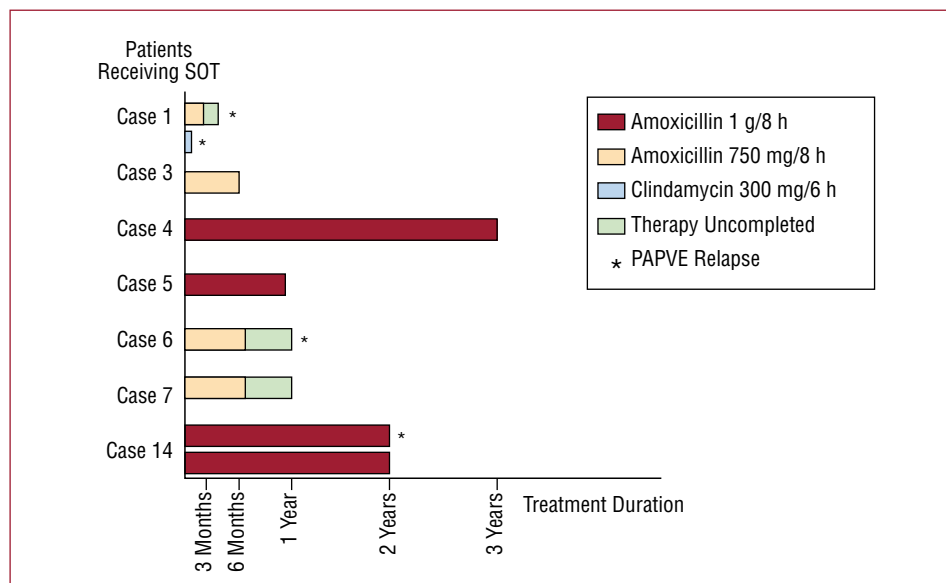
(Figure 2). Dialysis was required in 1 patient who developed progressive kidney failure with positive anticardiolipinic antibodies and nonspecific biopsy findings.

Endocarditis-related mortality was 18.7%.

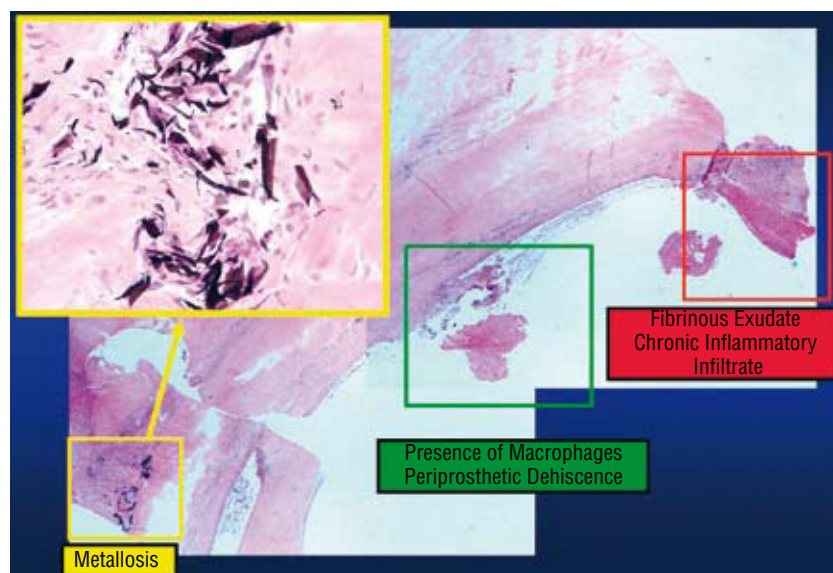
### Pathological Anatomy

Macroscopically, the most frequent findings were abundant friable grayish pannus (43.7%) and prosthesis loosening or suture dehiscence (31.2%). Other findings included the following: partial pseudoendothelialization of the prosthesis, inflammatory signs, and thrombus which appeared to be old. Vegetations (7%) and abscesses (7%) were infrequent.

The following were objectified in histological samples: foreign body granuloma (71.4%), fibrinous exudate (57.1%), thrombi in different stages of organization (42.8%), chronic inflammatory signs (35.7%), signs of acute activity (14.3%), disorganized suture (21.4%), calcium deposits (21.4%), and neoangiogenesis (14.3%). No bacterial colonies were observed in any of the specimens. Metalosis was observed in 2 cases (Figure 4).



**Figure 3.** Duration and compliance with suppressive oral therapy (SOT) in 16 cases of prosthetic valve infective endocarditis due to *Propionibacterium acnes*.



**Figure 4.** Histological detail of periprosthetic tissue section of PAPVE using hematoxylin-eosin stain.

## DISCUSSION

In the literature, previous heart surgery has been considered a risk factor for PAPVE,<sup>2,5,6,22</sup> and only 3 independent reports associate it with a cutaneous entry point.<sup>9,10,23</sup> Our study indicates that in early endocarditis (<1 year after surgery) the risk factor is previous heart surgery, whereas in late endocarditis the risk factor is mucocutaneous manipulation. In addition, we show that the time between manipulation and symptom onset can be very long, and thus it can escape unidentified.

The delay in diagnosing prosthetic endocarditis was longer than normal, which has been reported in

other publications,<sup>1,5,20,,23,24</sup> although in our series it was even longer. Fever was also less frequent, both in this study and in published cases, although it was even less common in our study. The most frequent manifestation was progressive prosthetic dysfunction (93%), in combination with heart failure (62%), with percentages greater than those reported (82% vs 36%, respectively<sup>1,2,4-6,8,10-13,16,23,25</sup>). The percentage of neurological symptoms reported was higher than in this series (38% vs 26%), but in both cases this was higher than the general incidence of neurological complications in prosthetic endocarditis (20%). The mismatch between the clinical data obtained in our series and the literature seems to be because our



methodology enabled endocarditis to be identified with less infective symptomatology being present. Suspicions on behalf of the cardiac surgeon during valve replacement played a key role. Other authors have also made this assessment.<sup>16,23</sup>

Another important characteristic was the presence of symptoms relating to circulating immune complexes, such as local myalgia, aseptic arthritis, tenosynovitis, necrotic cutaneous lesions, reticularis livedo, or progressive kidney failure. Three articles on endocarditis due to *P acnes* have described immunological manifestations, such as glomerulonephritis that required high-dose corticoids for cure.<sup>20,21,24</sup> Part of the pathophysiology of the disease is probably related to inflammatory immunological events, as already described in other infections produced by *P acnes*, such as acne<sup>26</sup> or endophthalmitis, which always require corticosteroids for cure.<sup>27</sup> The inflammatory syndrome SAPHO (synovitis, acne, periostitis, hyperostosis, osteitis) has also been associated with infection due to *P acnes*.<sup>28</sup>

Late relapse was another characteristic reported, and thus strict follow-up for no less than 2 years is recommended, especially in patients who do not undergo surgery. Data are limited in the literature in this regard, but in 1 case the patient had 4 episodes in 4 years.<sup>2,10,17</sup>

The most frequent echocardiographic finding was prosthetic dysfunction due to periprosthetic dehiscence, almost always without abscesses or pseudoaneurysms. Prosthetic dysfunction is also the predominant datum reported in PAPVE,<sup>1,2,4-6,8,10-14,23,25</sup> although the frequency of vegetations or abscesses was greater than in the present work, which is explained by methodological differences. In addition, our study shows that the initial echocardiographic study may be normal, and dysfunction may develop slowly. Thus, if there are clinical data that indicate this, such as recurrent neurological embolisms within a suitable anticoagulation range or blood cultures positive for *P acnes*, clinical and echocardiographic follow-up should be done to rule out the disease.

Our data and other published data<sup>4,13,18</sup> show that blood cultures should be incubated for at least 3 weeks and surgical specimens for up to 30 days to avoid underdiagnosing PAPVE. Better yields were obtained using surgical specimen cultures than with blood cultures. Processing the cultures by triturating the tissue in mortars, as done in our hospital, or by the sonication of prostheses increases culture yield in prosthetic infections and should be recommended.<sup>29</sup> The use of anaerobic culture processing in intravascular catheters increases the detection of *P acnes*.<sup>30</sup> The presence of *P acnes* can be underestimated if these processing techniques are not used.

Antibiotic treatment followed by valve replacement surgery led to most patients being cured. However, although isolated antibiotic treatment controlled the symptoms, it almost never succeeded in eliminating the infection. The fact that correct antibiotic treatment is not sufficient to obtain a cure indicates the involvement of biofilm. Nevertheless, SOT could be useful in patients in whom surgery is contraindicated or in whom the prosthetic material has not completely been removed, although the duration of treatment is not well established. Two cases have been reported that evolved favorably with SOT, but follow-up was only 12 months and 18 months, respectively.<sup>14,19</sup> The high rate of early prosthetic dehiscence encountered is unusual in our center. The cause could not be identified, since the cultures were negative and the histology was nonspecific. The suspicion cannot be avoided that all or at least some of them were PAPVE with low inoculum. A case of acute prosthetic dehiscence has recently been described as a clinical manifestation of PAPVE.<sup>13</sup> Similarly, prosthesis loosening (in orthopedics) in association with subclinical infections due to *P acnes* has been widely described in the literature.<sup>31</sup>

Mortality was within the range described in the literature (13%-27%).<sup>11,17</sup>

The macroscopic appearance of cardiac prostheses infected by *P acnes* has not been described in detail in the literature.<sup>16,23</sup> Our data indicate that the presence of friable grayish pannus, with or without partial pseudoendothelialization of the prosthesis, should definitely rule out PAPVE, especially in cases of valvular dysfunction.

The histological findings of PAPVE, not previously described in the literature, demonstrated data compatible with chronic infection. Of especial note was the presence of granulation tissue, also described in native IE due to *P acnes*<sup>32</sup> and prosthetic hip infections<sup>33</sup>; it should be mentioned that, in recent years, numerous works have been published that associate sarcoidosis with the presence of *P acnes*.<sup>34</sup> Metallosis in periprosthetic tissue, present in 2 of our cases, has been associated with loosening of orthopedic prostheses due to immunological mechanisms<sup>35</sup> or in response to underlying infection.<sup>36</sup> Furthermore, the release of propionic acid by *P acnes* could play a role, since this can have a corrosive effect on metals.

The clinical behavior of PAPVE may be the result of the different properties of *P acnes*, such as its low virulence or ability to produce biofilm. Sessile bacteria, imbedded in the biofilm, would activate macrophages which, although incapable of phagocytosing them, release enzymes that could injure the host tissue, causing periprosthetic dehiscence. On the other hand, this would explain the low frequency of infective symptoms, only present

when groups of planktonic bacteria are released into the circulation. Furthermore, the presence of biofilm can also explain why standard cardiac prosthesis cultures do not confirm the presence of *P acnes*, due to the lack of growth of the sessile bacteria imbedded in it, unless the tissues are triturated or the prostheses are sonicated, and in both cases undergo prolonged incubation. The capacity of *P acnes* to form biofilm on different biological materials has been demonstrated (joint prostheses<sup>33</sup> or catheters<sup>37</sup>) and also on valve prostheses in vitro,<sup>38</sup> but to date there are no references in the literature demonstrating biofilm in cardiac valve prostheses infected in vivo by this microorganism.

## CONCLUSIONS

*P acnes* prosthetic valve endocarditis is a disease that is acquired during heart surgery or as a consequence of bacteremia of mucocutaneous origin. It has a slow progressive clinical course, with few signs of infection, among which cardiac signs predominate, secondary to valvular dysfunction, and neurological signs. This means that many PAPVE escape notice and that the real incidence is underestimated. Echocardiographic study rarely demonstrates vegetations or abscesses, and it basically manifests as prosthetic dehiscence or thrombosis. Prolonged culture incubation may be needed to detect it. Real-time PCR may be a useful diagnostic tool, with promising results when fresh tissue specimens are used. Its histological appearance is compatible with chronic infection. Antibiotic treatment easily suppresses the microorganism, but does not eliminate it, and thus withdrawal of the prosthetic material is necessary to achieve cure. The course may become more complicated in noninfective prosthetic dehiscence, despite correct treatment. Close collaboration between the clinician, microbiologist, surgeon, and pathologist is required to correctly interpret all the data according to the clinical context and to avoid underdiagnosing PAPVE.

## ACKNOWLEDGMENTS

We would like to thank Dr R. Velayos, Dr I. Mate, Dr Pintado, and Dr Cereizo for allowing us to publish patient data.

## REFERENCES

1. Chakour M, Revel F, Godreuil C, Ploton C, Aubry, Koeck JL. Infectious endocarditis due to *Propionibacterium acnes* on a mechanical valve and cardiac stimulator electrode. *Presse Med.* 2002;31:1414.
2. Durupt S, Boibieux A, Ballet-Mechain M, Chaumentin G, Tremeau G, Roure C, et al. *Propionibacterium acnes* infectious endocarditis. *Presse Med.* 1998;27:1839-41.
3. Huynh TT, Walling AD, Miller MA, Leung TK, Leclerc Y, Dragtakakis L. *Propionibacterium acnes* endocarditis. *Can J Cardiol.* 1995;11:785-7.
4. Gunthard H, Hany A, Turina M, Wust J. *Propionibacterium acnes* as a cause of aggressive aortic valve endocarditis and importance of tissue Grinding: case report and review. *J Clin Microbiol.* 1994;32:3043-5.
5. Lee PY, Martin MJ, Treasure T. *Propionibacterium acnes* causing perivalve abscess. *Br Heart J.* 1993;69:470.
6. Horner SM, Sturridge MF, Swanton RH. *Propionibacterium acnes* causing an aortic root abscess. *Br Heart J.* 1992;68:218-20.
7. Abramczuk E, Rawczynska-Englert I, Meszaros J. *Propionibacterium acnes* in the etiology of endocarditis. *Pol Tyg Lek.* 1992;47:496-7.
8. Lazar JM, Schulman DS. *Propionibacterium acnes* prosthetic valve endocarditis: a case of severe aortic insufficiency. *Clin Cardiol.* 1992;15:299-300.
9. Scheel O, Sundsfjord A, Lunde P, Andersen BM. Endocarditis after acupuncture and injection-treatment by a natural healer. *JAMA.* 1992;267:56.
10. O'Neill TM, Hone R, Blake S. Prosthetic valve endocarditis caused by *Propionibacterium acnes*. *Br Med J (Clin Res Ed).* 1988;296:1444.
11. Delahaye F, Fols S, Celard M, Vandenesch F, Beaune J, Bozio A, et al. [*Propionibacterium acnes* infective endocarditis. Study of 11 cases and review of literature]. *Arch Mal Coeur Vaiss.* 2005;98:1212-8.
12. Pan SC, Wang JT, Hsueh PR, Chang SC. Endocarditis caused by *Propionibacterium acnes*: an easily ignored pathogen. *J Infect.* 2005;51:e229-31.
13. Van Leeuwen WJ, Kappetein AP, Bogers AJ. Acute dehiscence of a valve prosthesis 5 years after implantation. *Int J Cardiol.* 2007;117:e79-81.
14. Hinestrosa F, Djurkovic S, Bourbeau PP, Foltzer M. *Propionibacterium acnes* as a cause of prosthetic valve aortic root abscess. *J Clin Microbiol.* 2007;45:259-61.
15. Harris KM, Ang E, Lesser JR, Sonnesyn SW. Cardiac magnetic resonance imaging for detection of an abscess associated with prosthetic valve endocarditis: a case report. *Heart surg forum.* 2007;10:e186-7.
16. Clayton JJ, Baig W, Reynolds GW, Sandoe JA. Endocarditis caused by *Propionibacterium* species: a report of three cases and a review of clinical features and diagnostic difficulties. *J Med Microbiol.* 2006;55:981-7.
17. Lalani T, Person AK, Hedayati SS, Moore L, Murdoch DR, Hoen B, et al. *Propionibacterium* endocarditis: A case series from the International Collaboration on Endocarditis Merged Database and Prospective Cohort Study. *Scand J Infect Dis.* 2007;39:840-8.
18. Kanjanathai S, Kanlue T. *Propionibacterium acnes*: A rare cause of late prosthetic valve endocarditis and aortic root abscess. *Int J Cardiol.* 2008;130:e66-8. Epub 2008 Jan 15.
19. Zedtwitz-Liebenstein K, Gabriel H, Graninger W. Pacemaker endocarditis due to *Propionibacterium acnes*. *Infection.* 2003;3:184-5.
20. Chua AG, Ding J, Schoch PE, Cunha BA. Pacemaker-induced endocarditis due to *Propionibacterium acnes*. *Clin Infect Dis.* 1998;27:1541-2.
21. Kimmel M, Kuhlmann U, Alschner DM. Pacemaker infection with *propionibacterium* and nephritic sediment. *Clin Nephrol.* 2008;69:127-9.
22. Vandebos F, Roger PM, Mondain-Miton V, Dunais B, Fouché R, Kreitmann P, et al. Ventricular patch endocarditis caused by *Propionibacterium acnes*: advantages of gallium scanning. *J Infect.* 2001;43:249-51.

23. Vanagt WY, Daenen WJ, Delhaas T. *Propionibacterium acnes* endocarditis on an annuloplasty ring in an adolescent boy. *Heart*. 2004;90:e56.
24. Koya D, Shibuya K, Kikkawa R, Haneda M. Successful recovery of infective endocarditis-induced rapidly progressive glomerulonephritis by steroid therapy combined with antibiotics: a case report. *BMC Nephrol*. 2004;5:18.
25. Caballero Gueto J, Arana R, Calle G, Caballero Gueto FJ, García de Sancho M, Pinero C. [Acute endocarditis of the native aortic valve caused by *Propionibacterium acnes*]. *Rev Esp Cardiol*. 1997;50:908.
26. Burkhart CN, Burkhart CG. Microbiology's principle of biofilms as a major factor in the pathogenesis of acne vulgaris. *Int J Dermatol*. 2003;42:925-7.
27. Sunaric-Megevand G, Pournaras CJ. Current approach to postoperative endophthalmitis. *Br J Ophthalmol*. 1997;81:1006-15.
28. Kotilainen P, Merilähti-Palo R, Lehtonen OP, Manner I, Helander I, Mottonen T, et al. *Propionibacterium acnes* isolated from sternal osteitis in a patient with SAPHO syndrome. *J Rheumatol*. 1996;23:1302-4.
29. Esteban J, Gomez-Barrena E, Cordero J, Martín-de-Hijas NZ, Kinnari TJ, Fernandez-Roblas R. Evaluation of quantitative cultures from sonicated retrieved orthopaedic implants in the diagnosis of orthopaedic infection. *J Clin Microbiol*. 2008;46:488-92.
30. Martín-Rabadán P, Gijón P, Alcalá L, Rodríguez-Créixems M, Alvarado N, Bouza E. *Propionibacterium acnes* is a common colonizer of intravascular catheters. *J Infect*. 2008;56:257-60.
31. Trampuz A, Zimmerli W. Prosthetic joint infections: update in diagnosis and treatment. *Swiss Med Wkly*. 2005;135:243-51.
32. Moreira AL, Haslett PA, Symmans W. *Propionibacterium acnes* as the cause of endocarditis in a liver transplant recipient. *Clin Infect Dis*. 2000;30:224-6.
33. Tunney MM, Patrick S, Curran MD, Ramage G, Hanna D, Nixon JR, et al. Detection of prosthetic hip infection at revision arthroplasty by immunofluorescence microscopy and PCR amplification of the bacterial 16S rRNA gene. *J Clin Microbiol*. 1999;37:3281-90.
34. Eishi Y. Sarcoidosis and *Propionibacterium acnes*. *Nippon Naika Gakkai Zasshi*. 2003;92:1182-9.
35. Salvati EA, Betts F, Doty SB. Particulate metallic debris in cemented total hip arthroplasty. *Clin Orthop Relat Res*. 1993;293:160-73.
36. Shapiro SE, Spurling DC, Cavaliere R. Infections following implant arthroplasties of the forefoot. *Clin Podiatr Med Surg*. 1996;13:767-91.
37. Passerini L, Phang PT, Jackson FL, Lam K, Costerton JW, King EG. Biofilms on right heart flow-directed catheters. *Chest*. 1987;92:440-6.
38. Guío L, Sarriá C, Sala M, Sánchez Madrid F, Mc Dowell A, de Las Cuevas C, et al. Demonstration of biofilm in vitro *Propionibacterium acnes* prosthetic valve endocarditis. In: Abstracts of the 9th International Symposium of Modern Concepts in Endocarditis and Cardiovascular Infections. *Clin Res Cardiol*. 2007;96:446.