

IMAGE IN CARDIOLOGY

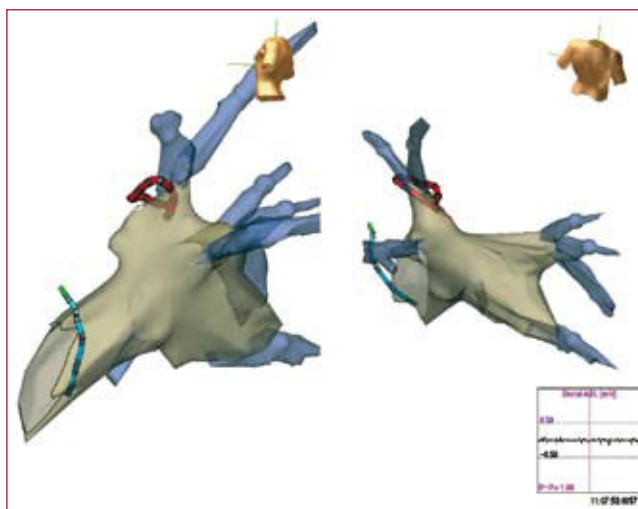


Figure 1

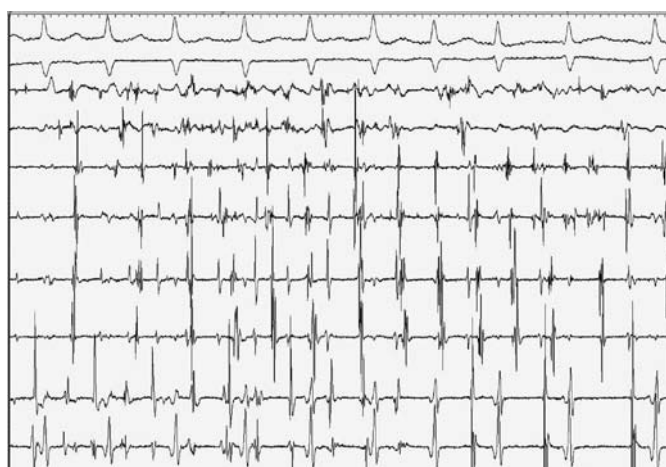

Figure 2

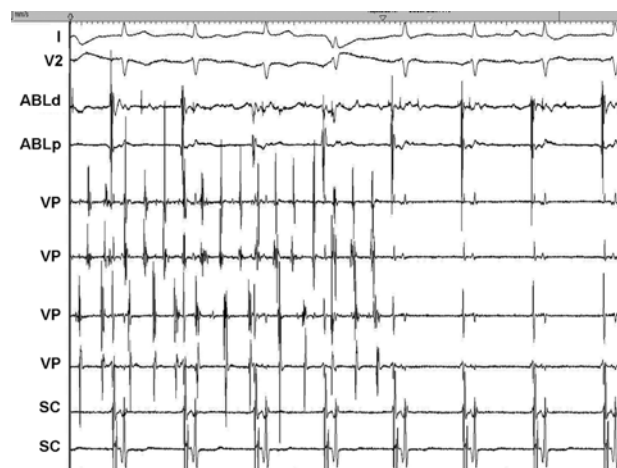

Figure 3

## Pulmonary Vein Isolation and Sinus Rhythm

A 53-year-old man with hypertension was diagnosed with paroxysmal atrial fibrillation (AF) refractory to antiarrhythmic therapy, first with amiodarone and later with flecainide and beta-blockers. Therefore, catheter ablation of AF was indicated.

Using trans-septal catheterization, a spiral catheter was placed in the ostium of the pulmonary veins (Figure 1, in red). A nonfluoroscopic 3-dimensional intracardiac navigation system (NavX<sup>®</sup>) was used to guide the movements of the catheters and create a representation of the left atrium (LA) in 3 dimensions (Figure 1). Atrial fibrillation was induced by stimulation from the catheter placed in the coronary sinus (CS) (Figure 1, in blue). Radiofrequency was applied with an irrigated-tip ablation catheter in the ostium of the left pulmonary vein (PV). Isolation was achieved,

and the patient converted to sinus rhythm, as is seen in the CS electrograms (Figure 2). The PV maintained a fibrillatory rhythm that later regulated to atrial tachycardia, and ultimately disappeared spontaneously (Figure 3). Pulmonary vein ablation is currently the treatment of choice for paroxysmal AF resistant to medical treatment. Conversion to sinus rhythm during radiofrequency application is observed when a main pulmonary trunk (the most common) or a single pulmonary vein, as in this case, is electrically isolated, because it is the arrhythmia located in these structures (usually atrial tachycardia) that maintains the AF

Miguel Álvarez, Luis Tercedor,  
and Isabel Almansa

Unidad de Arritmias, Servicio de Cardiología, Hospital  
Universitario Virgen de las Nieves, Granada, Spain