

IMAGE IN CARDIOLOGY

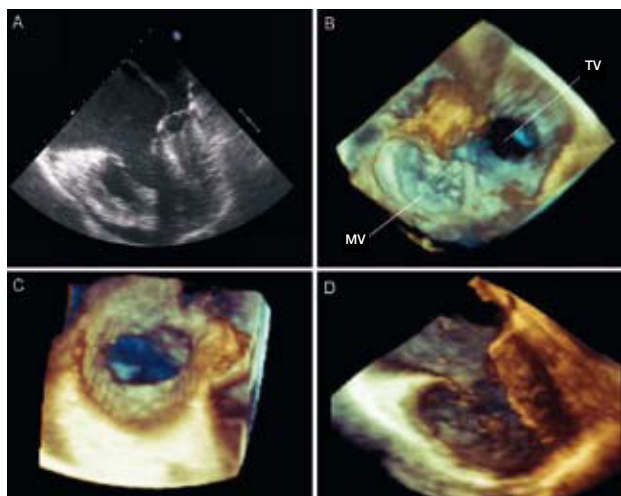


Figure 1.

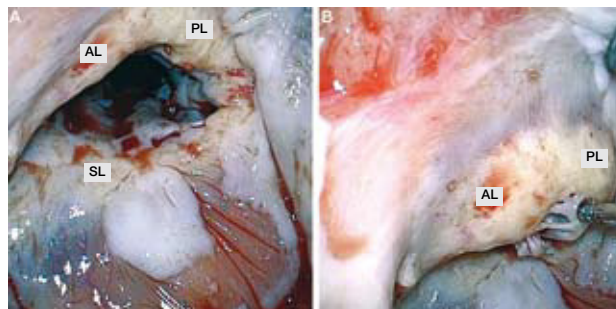


Figure 2.

Absence of the Tricuspid Valve Due to Severe Carcinoid Heart Disease

A 55-year-old man, diagnosed with carcinoid syndrome 12 years previously, experienced generalized hepatic metastasis and subsequent carcinoid heart disease, with a grade VI/VI systolic ejection murmur at the tricuspid valve. In addition, the patient had dyspnea on moderate exertion and evident peripheral symptoms of right heart failure. Following a preoperative evaluation, the patient was referred for surgery to correct the valve involvement and avoid greater deterioration of ventricular function. On intraoperative transesophageal echocardiography (TEE), he showed dilation of the right chambers and a severely affected tricuspid valve (Figure 1A). The tricuspid had a diseased appearance with marked echolucency, and thickening, retraction, and immobility of the leaflets, which were fixed in the diastolic position, resulting in a complete “absence” of the valve structure. Real-time 3-dimensional TEE (3D TEE) confirmed the “absence” of tricuspid leaflets due to fibrosis and fusion with the ventricular tissue. The capability of 3D TEE to orient the sections in any plane enabled a complete, fast, and precise evaluation of the valvular orifice:

from the right atrium (Figure 1B: MV, mitral valve; TV, tricuspid valve), from the right ventricle (Figure 1C), and lastly, a lateral view after off-line subtraction of the anterolateral wall of the right ventricle (Figure 1D). The surgical analysis confirmed the 3D echocardiographic findings and additionally disclosed severe involvement of the subvalvular apparatus and endocardial deposit of pearly fibrous plaques, a characteristic of carcinoid heart disease (figure 2A and 2B: AL, anterior leaflet; PL: posterior leaflet; SL: septal leaflet). The patient underwent multivalvular surgery, with mitral repair, tricuspid valve and pulmonary valve replacement, and reconstruction of the right ventricular outflow tract.

Funding: project funded by the Department of Cardiothoracic Surgery.

Javier G. Castillo,^a David H. Adams,^a
and Gregory W. Fischer^b

^aDepartment of Cardiothoracic Surgery, Mount Sinai Medical Center, New York, United States

^bDepartment of Anesthesiology, Mount Sinai Medical Center, New York, United States