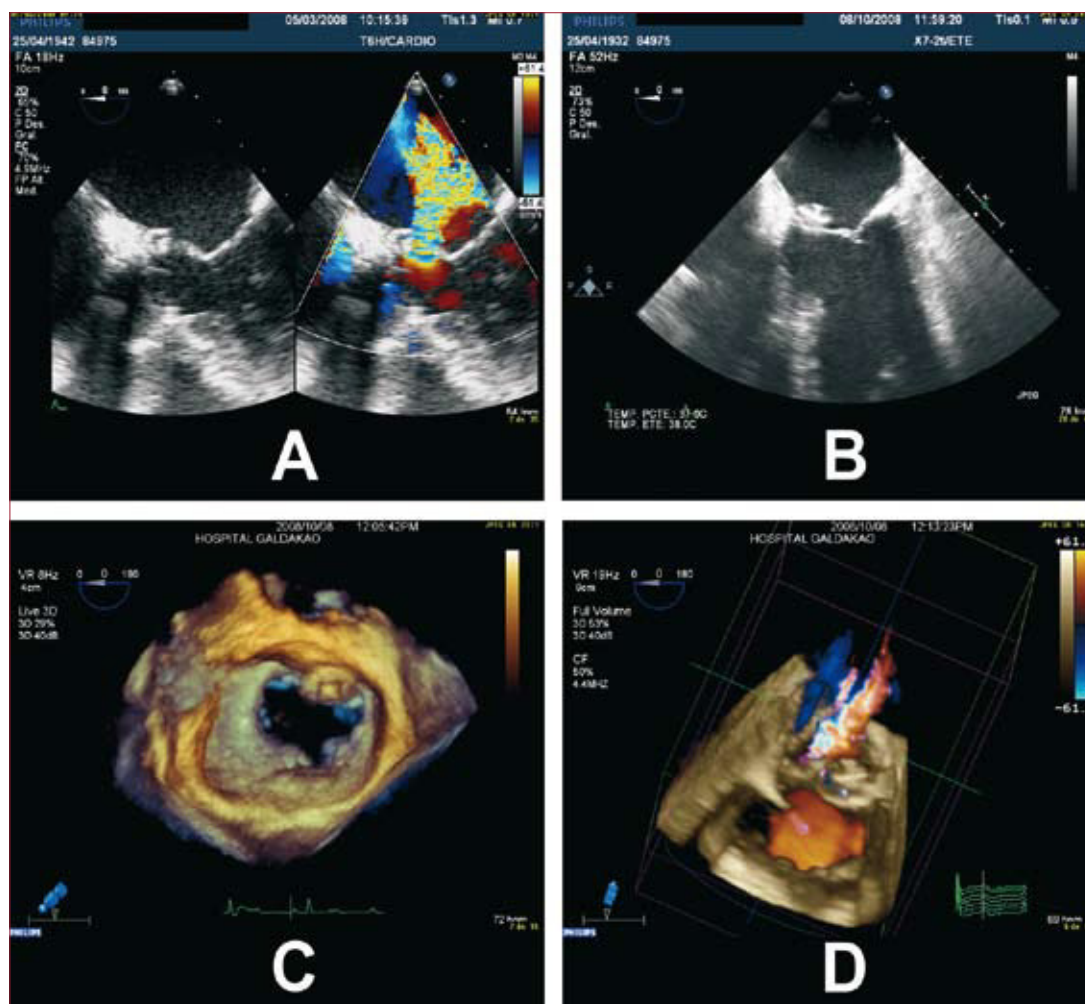


IMAGE IN CARDIOLOGY



Figure

## Percutaneous Closure of a Native Mitral Valve Perforation

A 65-year-old woman was consulted for dyspnea 1 month after aortic valve replacement (21-mm Bicarbon Fitline mechanical prosthesis), implanted to treat severe symptomatic aortic stenosis.

Transthoracic and transesophageal echocardiography confirmed correct functioning of the aortic prosthesis with no periprosthetic leaks. However, severe mitral regurgitation was detected, secondary to perforation of the anterior mitral leaflet. This was not present before the procedure and was considered an unusual complication of cardiac surgery (Figure, A).

Because of the severity of mitral regurgitation and the presence of symptoms in a patient who had undergone recent surgery, percutaneous closure of the anterior mitral leaflet perforation was decided. The patient was intubated and the procedure was performed through a right femoral access with 2-dimensional transesophageal echocardiography guidance. An 8×4-mm Amplatzer Vascular Plug III

was positioned in the mitral valve perforation, with an optimal outcome (Figure, B).

A few days after the procedure, a real-time 3-dimensional transesophageal echocardiography study was carried out, which provided precise images of the status of the occluding device in the anterior mitral leaflet (Figure, C). Some residual central mitral regurgitation was detected, but there was no regurgitation through the occluded perforation (Figure, D).

The patient's clinical course following this procedure was excellent, and at the time of writing, she is asymptomatic.

Sonia Velasco,<sup>a</sup> Mariano Larman,<sup>b</sup>  
and Marian Eneriz<sup>a</sup>

<sup>a</sup>Servicio de Cardiología, Hospital de Galdakao, Galdácano, Vizcaya, Spain

<sup>b</sup>Servicio de Cardiología, Policlínica de Gipuzkoa, San Sebastián, Guipúzcoa, Spain.