

Image in cardiology

Giant Aortic Pseudoaneurysm With Subcutaneous Protrusion

Seudoaneurisma aórtico gigante con protrusión hasta el plano subcutáneo

Ana M. Bel,* Manuel Perez, and Jose A. Montero

Servicio de Cirugía Cardíaca, Hospital Universitario La Fe, Valencia, Spain

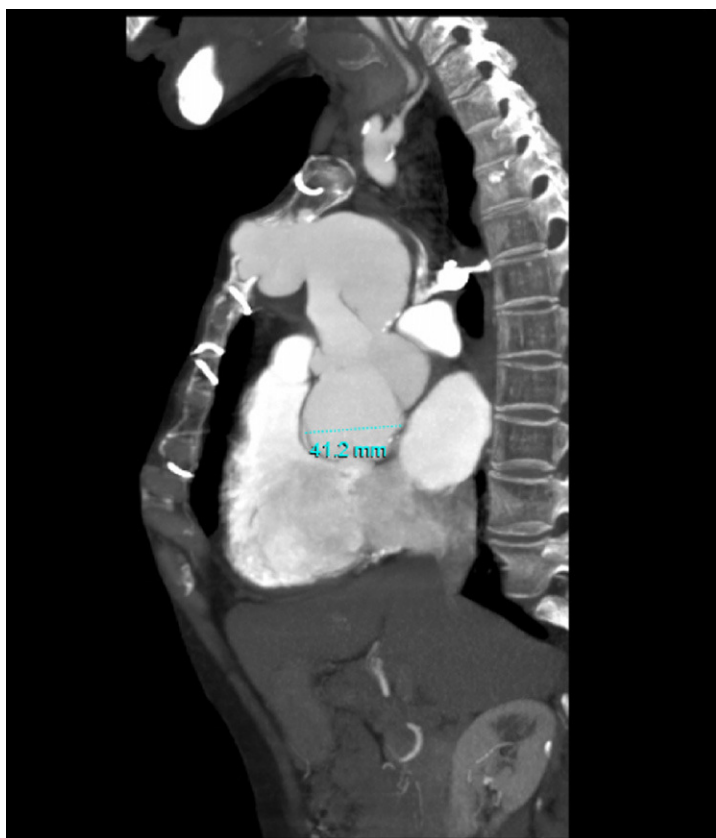


Figure 1.

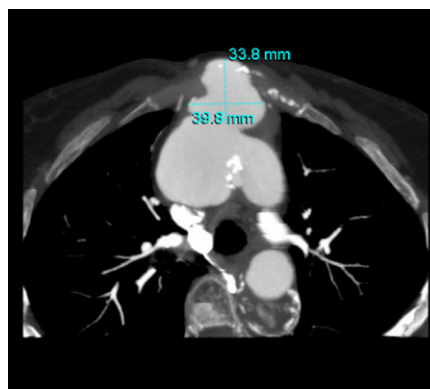


Figure 2.

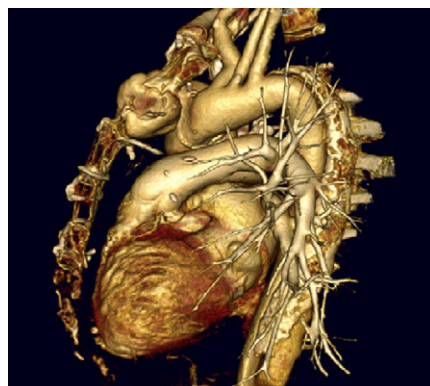


Figure 3.

A 59-year-old woman with Marfan syndrome underwent surgery in 1999 to treat an acute aortic dissection. The ascending aorta was replaced with a 30 mm diameter Dacron tube. The postoperative clinical course was uneventful and the patient was discharged at 15 days following surgery.

She did not attend her yearly medical visits and was lost to follow-up until 9 years after surgery. She came to the emergency room because of an increase in her usual dyspnea, and was found to be in NYHA functional class III/IV at that time. Echocardiography disclosed severe aortic insufficiency with moderately depressed ventricular function, and the patient was admitted to our unit for preoperative study.

On physical examination, a pulsatile mass was seen at midline, at the level of the sternal manubrium. Computed tomography angiography (Figs. 1 and 2) showed a pseudoaneurysm, arising from the distal suture of the aortic graft. In the imaging reconstruction (Fig. 3), the aneurysmal sac is seen to extend into the body of the sternum and continue to the skin plane.

The patient underwent surgery with a bilateral thoracotomy because it was impossible to perform a midline sternotomy. The aortic valve was replaced, and a supracoronary Dacron tube was implanted up to the aortic arch, at which point the aorta recovered its normal diameter.

The patient had an unfavorable postoperative course, requiring prolonged intubation for severe respiratory failure, and died 45 days after surgery.

* Corresponding author:

E-mail address: abelmin@hotmail.com (A.M. Bel).

Available online 21 April 2011