

Image in cardiology

Failed Percutaneous Closure of a Mitral Prosthesis Paravalvular Leak

Cierre percutáneo fallido de fuga periprotésica mitral

Manuel Carnero Alcázar,* Luis Carlos Maroto Castellanos, and José Enrique Rodríguez Hernández

Servicio de Cirugía Cardíaca, Instituto Cardiovascular, Hospital Clínico San Carlos, Madrid, Spain

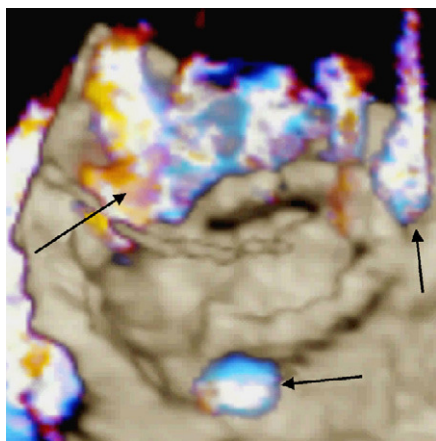


Figure 1.

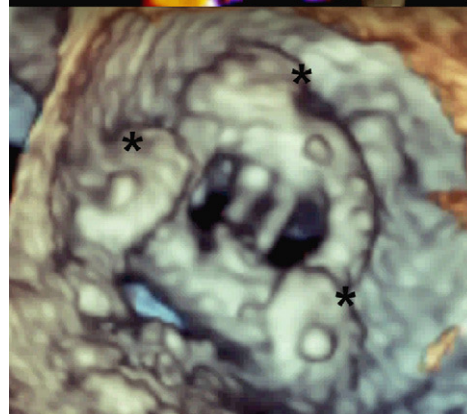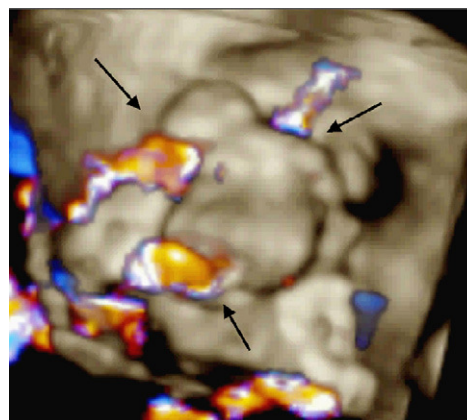


Figure 2.

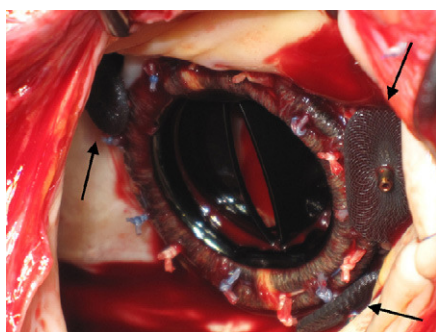


Figure 3.

A 77-year-old man who had a mechanical prosthetic mitral valve and aortic valve implanted in 1993 presented dyspnea and anemia, and was diagnosed of mitral prosthesis paravalvular leak. The patient was considered at high operative risk owing to his age, severe pulmonary hypertension, chronic renal failure, and previous cardiac surgery. Surgical treatment in his reference hospital was therefore excluded, and he was referred to the cardiology service of our hospital to evaluate percutaneous closure.

Echocardiography in 3D mode showed severe prosthetic paravalvular mitral regurgitation (Fig. 1, arrows). Three Amplatzer devices for percutaneous closure were implanted (Fig. 2, asterisks), which reduced the regurgitation to a moderate grade (Fig. 2, arrows). Two months later, the patient was readmitted for heart failure and hemolytic anemia. A new case of severe regurgitation had occurred due to an increase in the residual paravalvular leaks following percutaneous closure. The patient's clinical status progressively deteriorated (pulmonary edema, low cardiac output, anuria), and emergency surgery was decided to remove the percutaneous devices (Fig. 3, arrows) and replace the mitral prosthesis. Although the immediate postoperative period was uneventful (normal function of the prosthesis on transesophageal echocardiography), the patient died on the eighth day due to acute intestinal ischemia.

The treatment of choice for paravalvular leak of a cardiac valve prosthesis is surgical replacement of the prosthesis. Percutaneous closure is not free from associated morbidity and mortality, and the results are often suboptimal. Thus, this option should only be contemplated in patients with a prohibitive surgical risk, as determined by joint assessment on the part of surgeons and cardiologists.

* Corresponding author:

E-mail address: manuelcarneroalcazar@hotmail.es (M. Carnero Alcázar).

Available online 8 June 2011