

Image in cardiology

An Intracardiac Foreign Body, and a Few More

Cuerpo extraño intracardiaco y algo más

Francisco Toledano,\* Martín Ruiz-Ortiz, and Dolores Mesa

Servicio de Cardiología, Hospital Universitario Reina Sofía, Córdoba, Spain

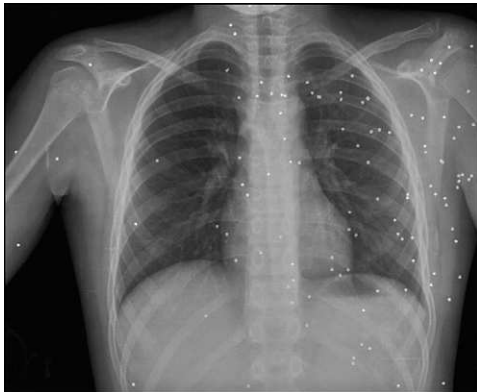

Figure 1.

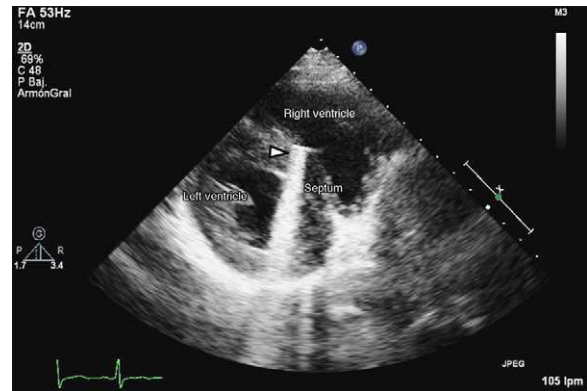


Figure 2.

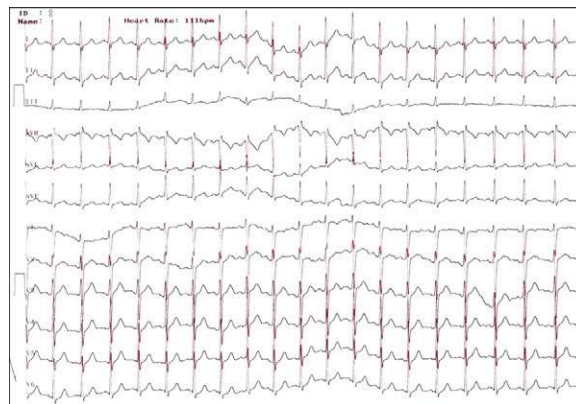

Figure 3.

A 14-year-old boy was taken to the emergency department following a firearm accident, in which he sustained multiple BB shot wounds to the neck, face, and chest. Surprisingly, he did not present signs of hemodynamic instability during hospitalization and only required drainage of a bilateral hemothorax. The chest X-ray performed just before hospital discharge showed multiple BB (Fig. 1). Figure 2 and the video provide a short-axis parasternal view of the follow-up echocardiography, in which a BB can be seen lodged in the interventricular septum (arrowhead), with the corresponding acoustic shadow. The initial electrocardiogram (Fig. 3) showed no alterations in interventricular conduction, as might have occurred considering the location of the BB. Conservative management was decided for the intracardiac foreign body, with the first follow-up visit at 1 month after hospital discharge.

SUPPLEMENTARY MATERIAL



Supplementary material associated with this article can be found in the online version available at doi:10.1016/j.rec.2011.02.007.

\* Corresponding author:  
E-mail address: franciscotoledan@hotmail.com (F. Toledano).  
Available online 8 June 2011