

Image in cardiology

Biventricular Implantable Cardioverter-defibrillator Post-implant Radiology: A Unique Image

Radiología tras implante de desfibrilador biventricular: una imagen singular

Miguel A. Arias,* Blanca Rodríguez-Picón, and Marta Pachón

Unidad de Arritmias y Electrofisiología Cardíaca, Servicio de Cardiología, Hospital Virgen de la Salud, Toledo, Spain

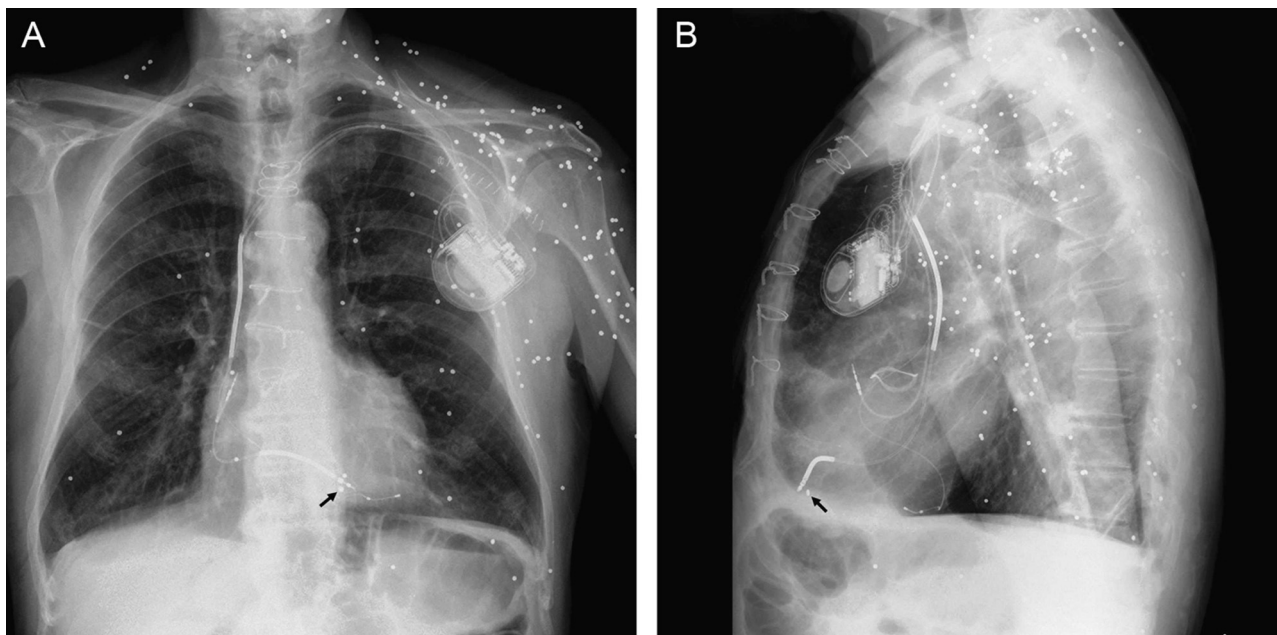


Figure 1.

A 72-year-old man was hospitalized for congestive heart failure and had a favorable response to the intensive medical treatment received. The patient had a history of ischemic heart disease with chronic anterior infarction of several years' duration and three-vessel disease revascularized percutaneously some years previously. Two years before the current hospitalization, he underwent aortic valve replacement surgery with implantation of a biologic prosthesis to treat a severe double aortic valve lesion. The patient's left ventricular systolic function was very depressed, he had an intraventricular conduction disturbance of the left bundle branch block type with QRS width > 150 ms, and he required repeated hospitalization for heart failure despite optimized medical treatment. Within this clinical profile, the patient underwent implantation of an automatic defibrillator with cardiac resynchronization therapy, with no incidents. The follow-up posteroanterior (Fig. 1A) and lateral (Fig. 1B) chest radiographs showed well-positioned electrodes and multiple, randomly distributed, radio-opaque nodules predominating in the left chest wall, upper left extremity and supraclavicular region, and bilateral cervical areas, as well as the upper portion of the abdomen. These features corresponded to shotgun pellets acquired during a hunting accident 20 years previously that did not cause serious internal injury. However, on fluoroscopy during defibrillator implantation, one of the pellets was found to be located within the right ventricular myocardial wall, and was seen to rhythmically shift along with the tip of the electrode implanted in the apex of the ventricle (black arrow).

* Corresponding author:

E-mail address: maapalomares@secardiologia.es (M.A. Arias).

Available online 23 November 2011