

Image in cardiology

Hemodynamic Changes Alert to Spontaneous Ductus Arteriosus Spasm

Cambios hemodinámicos alertan del espasmo ductal espontáneo

Georgia Sarquella-Brugada,* Yvan Mivelaz, and Nagib Dahdah

Cardiology Division, Department of Pediatrics, CHU Sainte-Justine, University of Montreal, Montreal, Quebec, Canada

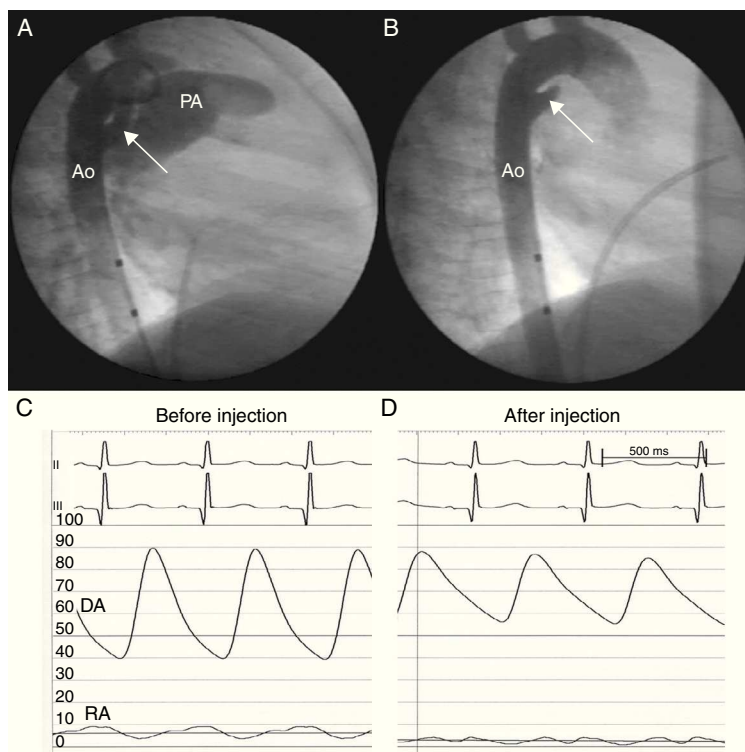


Figure.

A 14-month-old premature infant with a large, tubular, patent ductus arteriosus was under periodic follow-up. On ultrasound study, the ductus was seen to vary in diameter, but the persistent dilation of the left chambers and failure of the patient to thrive led us to present her for percutaneous closure.

Before attempting to cross the ductus, descending aorta (Ao) angiography with a pigtail catheter was performed, which showed a large ductus (Fig. A). Immediately after, an increase in diastolic pressure was observed (Fig. C and D). A second angiogram showed complete ductus occlusion (Fig. B).

After 60 min of continuous monitoring, the diastolic pressure gradually decreased. A new coronary angiography showed re-patency of the ductus. Closure was carried out with implantation of an Amplatzer® Duct Occluder II (AGA Medical Corp; Plymouth, Minnesota, United States), based on the measurements taken in the first angiogram. Outpatient follow-up has confirmed that the device is stable and there is no residual flow.

Two months later, the patient's twin sister underwent catheterization, also for patent ductus arteriosus. Surprisingly, the same phenomenon of ductal spasm occurred on angiography.

Intermittent functional closure of ductus arteriosus is typically associated with catheter manipulation. In our cases, the spasm occurred following angiography. In both patients, continuous arterial pressure monitoring enabled us to diagnose the spasm and posterior ductus repatency. We believe that the size variability of a large ductus should not be underestimated. By monitoring diastolic pressure, measurement errors and consequent embolization of closure devices for this condition can be avoided.

* Corresponding author:

E-mail address: georgia@brugada.org (G. Sarquella-Brugada).

Available online 22 March 2012