

Images in cardiology

Very Late Thrombosis in a Bifurcation

Trombosis muy tardía de una bifurcación

Pilar Carrillo, Ramón López-Palop,* and Araceli Frutos

Unidad de Hemodinámica, Sección de Cardiología, Hospital Universitario de San Juan, San Juan de Alicante, Alicante, Spain

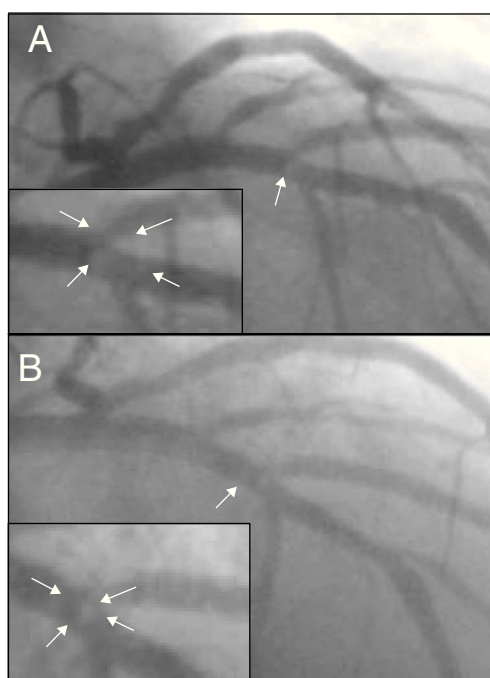


Figure 1.

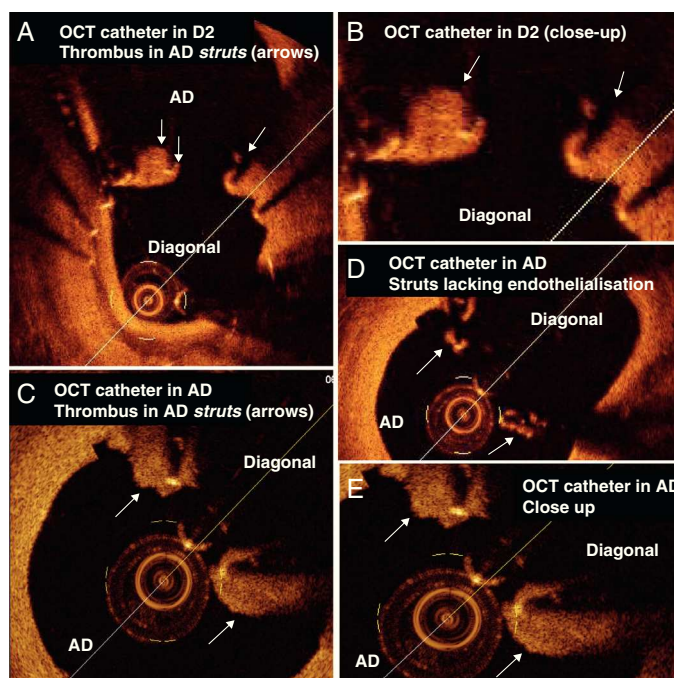


Figure 2.

A male patient 65 years old treated with a conventional stent in the second diagonal (D2) branche in 2007. In 2008, he underwent a stent-in-stent procedure for D2 in-stent restenosis, with stent implantation reaching the ostium taking off from the left anterior descending artery (LAD). In June 2011, antiplatelet treatment was discontinued due to non-cardiac surgery; the patient presented a myocardial infarction with ST elevation in V2-V6, so primary angioplasty was indicated. Coronary angiography showed an image compatible with intraluminal thrombus at the LAD/D2 bifurcation, which presented moderate in-stent restenosis and TIMI 3 flow in both branches (Fig. 1A). Angioplasty was not performed, and the patient started treatment with aspirin, clopidogrel and abciximab. After 4 days, follow-up coronary angiography showed angiographic improvement of the thrombus in the LAD (Fig. 1B). Optical coherence tomography (OCT) showed invasion and malapposition to the wall by the LAD stent implanted 3 years ago, lack of endothelialization in some of the struts (Fig. 2D, arrows) and a white thrombus adhering to the external and internal stent walls at the LAD lumen (particularly at the arrows in figures 2A and B – pullback from D2 – and arrows in figures 2C and E – pullback from anterior descending artery).

The case presented very late onset thrombosis in the main vessel of a bifurcation that had been treated only in its secondary branch. In most bifurcations treated with precise ostial stent placement, angiography does not show whether the stent is invading the artery that does not require treatment, and non-apposition of the stent can be accompanied by lack of endothelialization and late onset thrombosis. In these cases, the results of prolonging dual antiplatelet treatment are unknown.

* Corresponding author:

E-mail address: mlopezs@meditex.es (R. López-Palop).

Available online 14 March 2012