

Image in cardiology

Atypical Bidirectional Ventricular Tachycardia

Taquicardia ventricular bidireccional atípica

Miguel A. Arias,* Laia Belarte, and Marta Pachón

Unidad de Arritmias y Electrofisiología Cardíaca, Servicio de Cardiología, Hospital Virgen de la Salud, Toledo, Spain

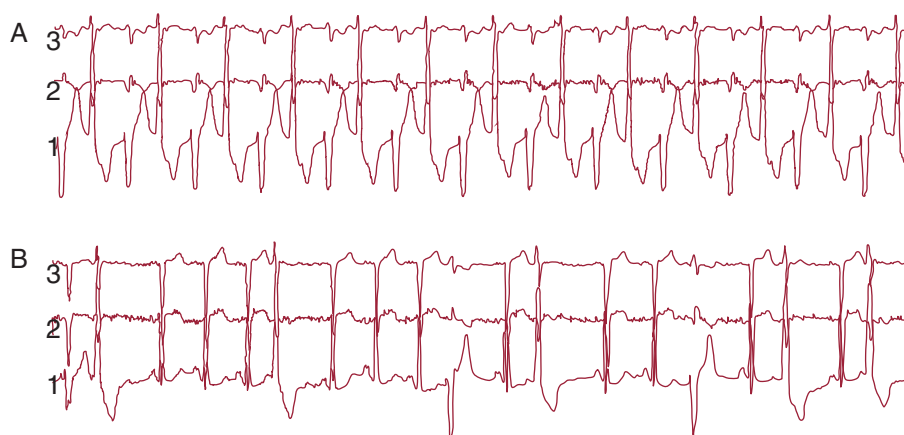


Figure.

A 75-year old male, with the sole cardiovascular risk factor of being an active smoker, was admitted with a several week history of progressive exertional dyspnea. He was not taking any medication on a regular basis. We performed a complete cardiological evaluation and diagnosed the patient with idiopathic dilated cardiomyopathy and severe left ventricular systolic dysfunction. Upon hospitalization, treatment was started with furosemide and captopril; an electrocardiogram revealed sinus rhythm with ventricular extrasystoles. Renal function parameters and serum ion concentrations were within normal limits from admission (creatinine: 0.7 mg/dL; sodium: 139 mEq/L; potassium: 4 mEq/L; magnesium: 1.6 mEq/L). We performed a continuous 24-h electrocardiogram in order to determine the density of ventricular extrasystoles as a possible cause for the cardiomyopathy, and 20% of the complexes corresponded to ventricular extrasystoles with two morphologies, as well as runs of 3-5 beats of nonsustained ventricular tachycardia. We documented one asymptomatic, at-rest episode of tachycardia at 113 bpm, which was a wide QRS tachycardia that alternated between the two morphological QRS types that had been observed in isolated extrasystoles (A). It was electrocardiographically compatible with bidirectional ventricular tachycardia. Although bidirectional ventricular tachycardia is characteristic of digitalis intoxication or familial forms of catecholaminergic ventricular tachycardia, this case was an atypical bidirectional tachycardia caused by a coupled continuous alternation of ventricular extrasystoles in the same patient (B). We started treatment with beta blockers and the ventricular extrasystole density decreased significantly (figure).

* Corresponding author: Servicio de Cardiología, Hospital Virgen de la Salud, Avda. Barber 30, 45004 Toledo, Spain.

E-mail address: maapalomares@secardiologia.es (M.A. Arias).

Available online 27 April 2012