

Image in cardiology

## Angiographic Catheter Entrapped in a Mitral Valve Prosthesis



### Catéter de angiografía atrapado en una prótesis mitral

Alejandro Martín-Trenor<sup>a,\*</sup> and Eduardo Alegría-Ezquerro<sup>b</sup>

<sup>a</sup> Departamento de Cardiología y Cirugía Cardíaca, Clínica Universidad de Navarra, Pamplona, Navarra, Spain

<sup>b</sup> Departamento de Cardiología, Policlínica Guipuzkoa, San Sebastián, Guipúzcoa, Spain

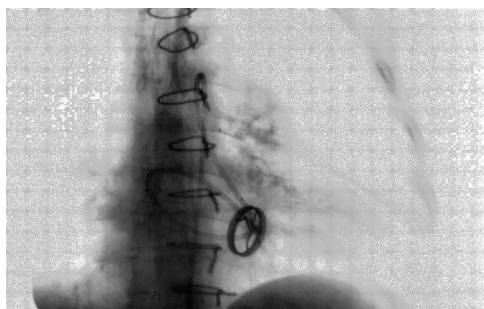


Figure 1.

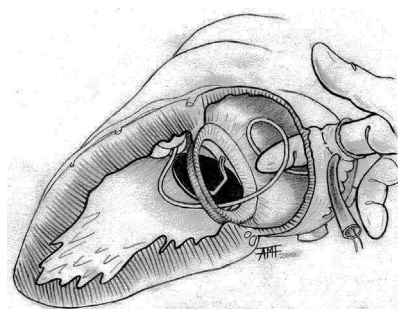


Figure 2.

The patient was a man with a Björk-Shiley mitral valve prosthesis. During a hemodynamic study, the angiographic catheter inserted into the left ventricle inadvertently passed into the atrium through the minor orifice of the prosthesis, which immobilized the disc (Figure 1). On trying to withdraw it, we noted resistance. All attempts to withdraw it failed. We were able to advance it once again, forming a loop in the atrium, but when we tried to draw it back, it again became entrapped. The patient developed acute pulmonary edema and shock. He was intubated and transferred to the operating room.

When we learned from his medical records that he had not undergone left atrial appendage ligation, we decided to perform left thoracotomy with the idea of a rapid approach and of the possibility of removing the catheter without cardiopulmonary bypass. Once a tourniquet had been applied to the atrial appendage, the surgeon inserted his index finger into the atrium to grasp the catheter, and removed it in the retrograde direction after the distal Luer connector had been detached (Figure 2). The patient's circulatory status normalized and the outcome of the intervention was good. Follow-up examinations demonstrated that the prosthesis was functioning normally.

The catheter was retained when it was passed through the minor orifice of the prosthesis in the retrograde direction and an attempt was made to withdraw it in the anterograde direction. The probe remained wedged between the disc and the ring by a "trapdoor" mechanism. The entrapment became more resistant when we attempted to pull the device out and yielded when it was reinserted; thus, it was easy to release the probe from the atrium by opening the "trapdoor" mechanism in the right direction.

This complication is fatal unless resolved within minutes, and can occur with any single disc valve, either in the mitral or aortic position.

\* Corresponding author:

E-mail address: [amtrenor@gmail.com](mailto:amtrenor@gmail.com) (A. Martín-Trenor).

Available online 17 May 2014