

Image in cardiology

Bioresorbable Scaffold T-stenting Evaluated With Optical Coherence Tomography



Stents bioabsorbibles en T evaluados con tomografía de coherencia óptica

Carlos Ortiz,* Hipólito Gutiérrez, and José A. San Román

Servicio de Cardiología, Instituto de Ciencias del Corazón (ICICOR), Hospital Clínico Universitario de Valladolid, Valladolid, Spain

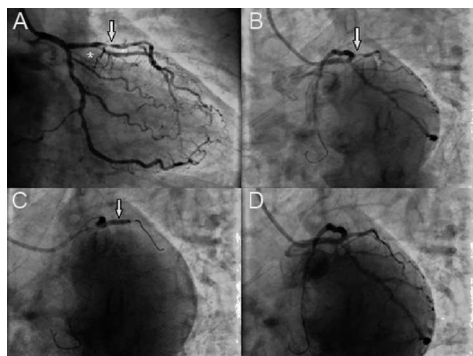


Figure 1.

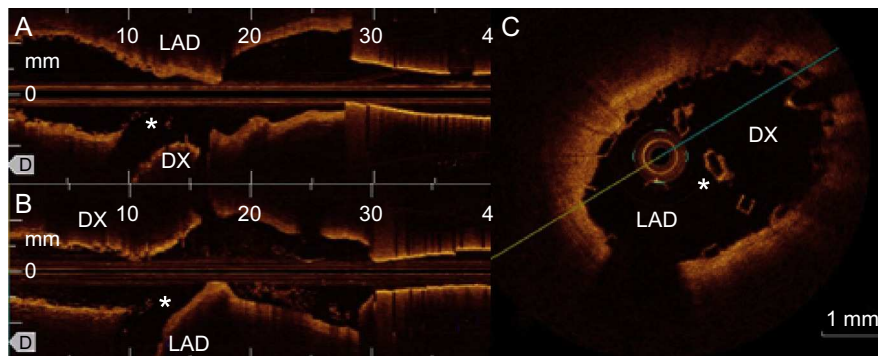


Figure 2.

A 69-year-old man without cardiovascular risk factors was admitted to our hospital with unstable angina. After 48 hours he underwent coronary angiography, showing severe disease of mid left anterior descending (LAD) coronary artery and proximal segment of the first diagonal (DX) (Figure 1A).

Balloon predilatation was performed in LAD and 2 bioresorbable everolimus-eluting (3×28 mm and 3.5×28 mm) overlapped scaffolds (Absorb, Abbott Vascular, Santa Clara, California, United States) were implanted in LAD, jailing the DX. The result at LAD was excellent but DX worsened to 90% stenosis with TIMI II flow (Figure 1B). Hence, “kissing-balloon” dilation was performed with a 3×15 mm balloon at LAD and 2.5×15 mm balloon at DX (Figure 1C). As the compromise of DX persisted, we implanted a bioresorbable everolimus-eluting scaffold (2.5×18 mm) through the proximal stent in a T-fashion stenting, inflating a 3×15 mm balloon in LAD to avoid scaffold protrusion, with excellent angiographic final result (Figure 1D). Several optical coherence tomography pullbacks from LAD and DX were performed, confirming correct strut apposition. There was a slight protrusion of the DX scaffold into LAD, perhaps because the balloon used to avoid scaffold protrusion was too small (Figure 2A: pullback from LAD and 2B: pullback from DX, *struts protruding from DX in LAD). Patient was discharged on dual antiplatelet therapy (acetylsalicylic acid, clopidogrel) for a year. Six months later remained asymptomatic.

Although increasing, experience with bioresorbable scaffolds in some situations, such as bifurcations, is limited. This is, to the best of our knowledge, the first case in which a true T-stenting was performed using bioresorbable scaffolds.

* Corresponding author:

E-mail address: ortiz.bautista.carlos@gmail.com (C. Ortiz).

Available online 29 May 2014