

Image in cardiology

Coronary Stent Implantation in an Infant



Implante de *stent* coronario en un lactante

Alberto Mendoza,^{a,*} Agustín Albarrán,^b and José M. Velasco^a

^a Instituto Pediátrico del Corazón, Hospital Universitario 12 de Octubre, Madrid, Spain

^b Unidad de Hemodinámica y Cardiología Intervencionista, Hospital Universitario 12 de Octubre, Madrid, Spain

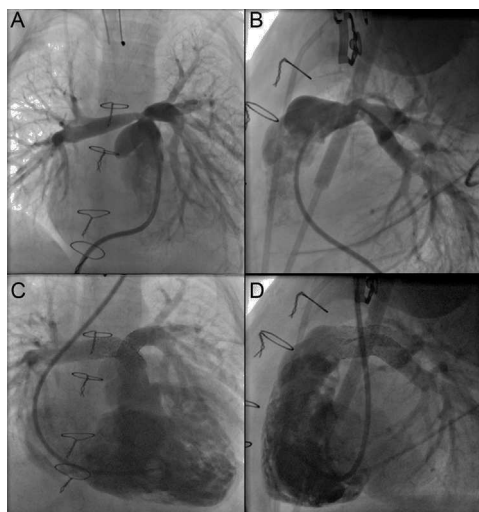


Figure 1.

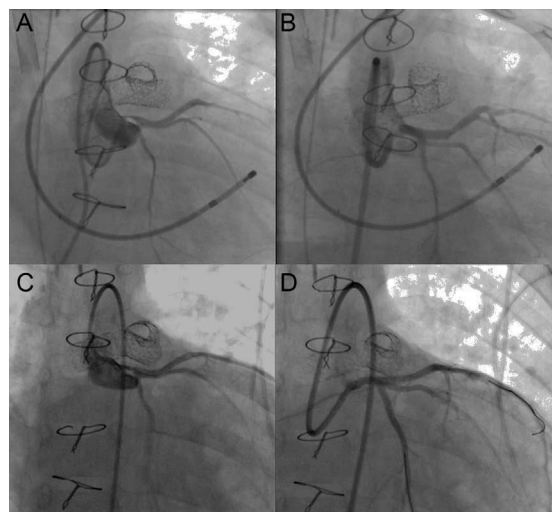


Figure 2.

A 9-month-old male infant (6.9 kg body weight) with aortic valve stenosis had been treated surgically with the Ross procedure. He underwent cardiac catheterization, which revealed severe obstruction at the origin of both pulmonary arteries (Figure 1A and B) that resolved with implantation of Formula™ 414 in both pulmonary arteries (Figure 1C and D); 12 hours later, the patient developed signs of ischemia in left coronary artery territory, with left ventricular dysfunction, and was placed on extracorporeal membrane oxygenation. Once he had been stabilized, coronary angiography was performed; this test revealed a critical obstruction in left main coronary artery (Figure 2A) that resolved after implantation of a 2.25 mm × 12 mm Taxus Liberté™ stent into coronary artery (Figure 2B). Ventricular function began to improve, and extracorporeal membrane oxygenation was discontinued 5 days later. When the child was 3 years old, follow-up coronary angiography revealed endothelial proliferation within the stent, with a considerable reduction in the lumen (Figure 2C), that resolved after implantation of a 2.5 mm × 11 mm BioMatrix Flex™ stent (Figure 2D).

Coronary stenosis following stent implantation into the pulmonary arteries is a very uncommon complication that can be avoided by performing imaging studies or coronary angiography simultaneously with intra-arterial balloon inflation prior to the intervention.

A high index of suspicion, together with stabilization under extracorporeal membrane oxygenation and intracoronary stent implantation, can save the patient's life.

* Corresponding author:

E-mail address: alberto.mendoza@salud.madrid.org (A. Mendoza).

Available online 29 May 2014