

Image in cardiology

## Coronary Aneurysm Closure With Pericardial Covered Stent Evaluated With Optical Coherence Tomography



### Cierre de aneurisma coronario con *stent* de pericardio evaluado con tomografía de coherencia óptica

Carlos Ortiz,\* Ana Serrador, and José Alberto San Román

Servicio de Cardiología, Hospital Clínico Universitario de Valladolid, Instituto de Ciencias del Corazón (ICICOR), Valladolid, Spain

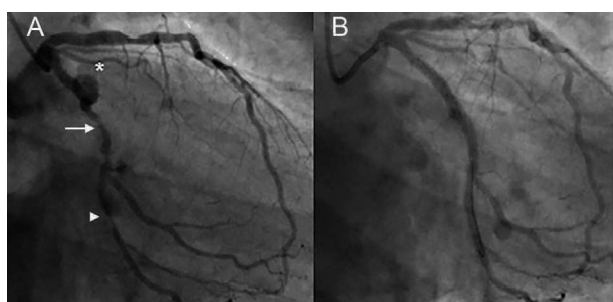


Figure 1.

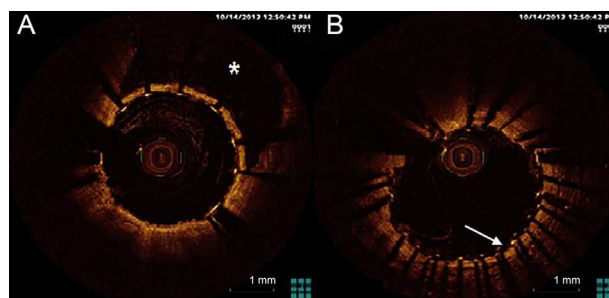


Figure 2.

A 62-year-old man with personal history of arterial hypertension and smoking was admitted to our hospital with ST elevation myocardial infarction. Intravenous fibrinolytic therapy was given by emergency services during hospital transfer, which was effective. Routine coronary angiography showed moderate lesion on the proximal left anterior descending, proximal coronary aneurysm (Figure 1A, asterisk) and significant lesions at mid segment of circumflex (white arrow) and proximal segment of the second marginal (arrowhead). The case was discussed with the heart team and the decision was made to perform percutaneous coronary intervention.

Balloon predilation was performed and drug-eluting stent was implanted in second marginal followed by direct drug-eluting stent implantation at mid segment of circumflex, fitting the proximal stent to distal origin of aneurysm. A 3.5 × 18 mm, pericardial, covered stent (Aneugraft, ITGI Medical Ltd., Israel) was implanted at circumflex aneurysm, overlapped to the distal drug-eluting stent with good final result (Figure 1B). Several optical coherence tomography pullbacks were conducted in order to confirm correct implantation of pericardial covered stent (Figure 2A, asterisk) and correct overlapping with distal drug-eluting stent (Figure 2B, white arrow). Patient was discharged on dual antiplatelet therapy with aspirin and clopidogrel for 1 year.

Although initially designed for vein graft angioplasty, pericardial covered stents have been used to treat other problems in interventional cardiology, such as coronary aneurysm, with limited experience. We present here what is, to the best of our knowledge, the first case to use optical coherence tomography to evaluate the final result of pericardial covered stenting in coronary aneurysm.

\* Corresponding author:

E-mail address: [ortiz.bautista.carlos@gmail.com](mailto:ortiz.bautista.carlos@gmail.com) (C. Ortiz).

Available online 18 June 2014