

Image in cardiology

Aortic Regurgitation Directed Toward Right Ventricle



Insuficiencia aórtica en ventrículo derecho

Irene A. García-Escribano, Juan C. Bonaque,* and Juan A. Castillo

Servicio de Cardiología, Hospital Universitario Santa Lucía, Cartagena, Murcia, Spain

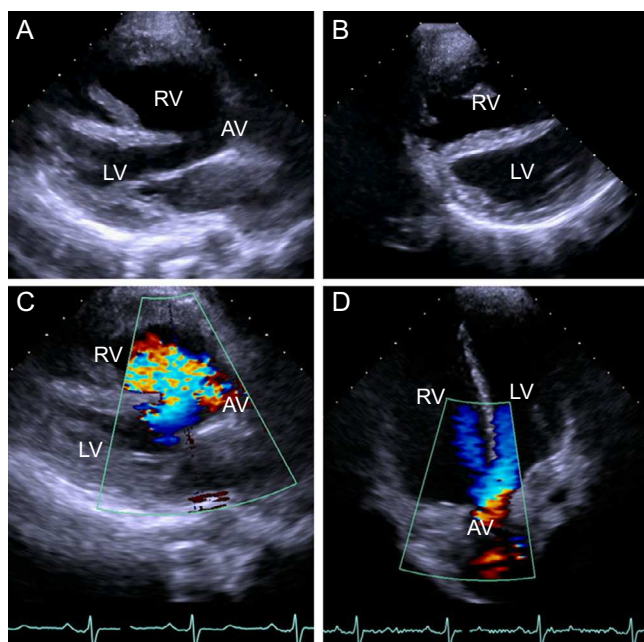


Figure 1.

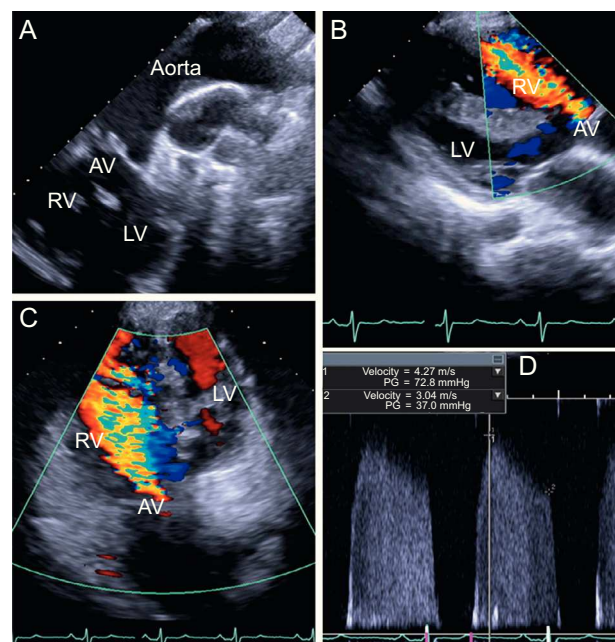


Figure 2.

We report the case of a 31-year-old woman who came to our cardiac imaging laboratory for a follow-up study of pulmonary atresia with a congenital ventricular septal defect. She had undergone palliative surgery consisting of a Waterston shunt (aortopulmonary anastomosis) as a child.

A transthoracic echocardiogram revealed that the aorta was completely overriding the ventricular septum, with a ventricular septal defect of 2.5 cm in diameter (Figure 1A; AV, aortic valve; LV, left ventricle; RV, right ventricle). We also observed a dilated right ventricle with generalized hypocontractility and signs of volume overload, as well as ventricular septal flattening during diastole (Figure 1B). Due to the presence of pulmonary atresia, blood flow into the ventricles passed through the aortic valve (Figures 1C and D), which was tricuspid and showed swelling of the leaflets, mainly on the free edge (Figure 2A) suprasternal window. This produced severe aortic regurgitation in which the blood flowed exclusively toward right ventricle (Figures 2B and C), with a protodiastolic pressure gradient of 73 mmHg and an end-systolic pressure gradient of 37 mmHg (Figure 2D). As was to be expected, the Waterston shunt showed no signs of compromise in the suprasternal views.

There have been very few reports of aortic regurgitation in which some of the blood returning to the heart reached right ventricle. However, the fact that the aortic regurgitation jet was directed exclusively toward right ventricle in such a complex heart disease, and the degree of severity, make this a singular case because, to the best of our knowledge, this condition had not been reported until now.

* Corresponding author:

E-mail address: jc_bonaque@hotmail.es (J.C. Bonaque).

Available online 10 July 2014