

Image in cardiology

# Cardiac Computed Tomography-guided Closure of Ventricular Septal Defect Secondary to Myocardial Infarction



## Cierre de comunicación interventricular posinfarto guiado por tomografía computarizada cardiaca

Dabit Arzamendi,\* Chi Hion Li, and Antoni Serra

Servicio de Cardiología, Hospital de Sant Pau i de la Santa Creu, Universidad de Barcelona, Barcelona, Spain

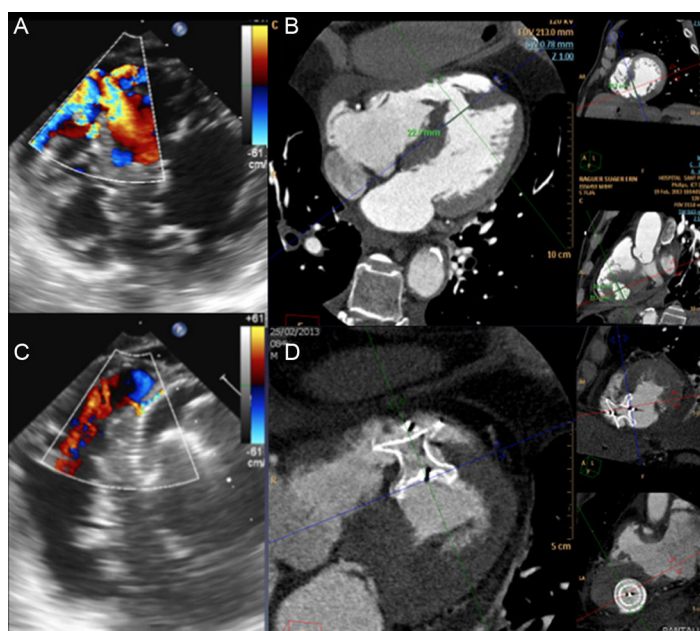


Figure.

An 84-year-old man with an unremarkable disease history came to our center more than 24 hours after having an inferoposterior myocardial infarction. He underwent coronary angiography, which revealed occlusion of the posterolateral branch, with organized thrombus, that could not be revascularized; the thrombolysis in myocardial infarction (TIMI) flow was grade 1. The patient remained asymptomatic and stable until, 4 days later, he again experienced tightness associated with hypotension; an echocardiogram disclosed the presence of a ventricular septal defect (VSD) in inferomedial septum (Figure A). Surgery was ruled out due to a EuroSCORE risk of mortality > 20% and, with a view to carrying out transcatheter repair, cardiac computed tomography (CT) was performed. It revealed a 22-mm VSD with a ragged septum on the right ventricular aspect (Figure B). On the basis of these findings, the decision was made to close the VSD, creating a femorojugular venovenous loop (right femoral vein, transseptal access to left atrium, left ventricle, right ventricle, right atrium, jugular vein). This enabled a first step to release the disk in right ventricle and gather all the ragged tissue, aligning the septum. Using this technique, a 24-mm Amplatzer postinfarction VSD occluder was successfully implanted (Figures C and D). The patient progressed satisfactorily and, after 16 months of follow-up, he remained alive, was in functional class II, and had a residual Qp/Qs of 1.8. This case shows the great utility of CT for profiling the ventricular septum and determining the size of the defect, the margins, and the irregularities of VSD secondary to myocardial infarction, providing essential information for transcatheter closure strategies.

### CONFLICTS OF INTEREST

Dr. Arzamendi is a proctor for St. Jude Medical.

\* Corresponding author:  
E-mail address: [darzamendi@santpau.cat](mailto:darzamendi@santpau.cat) (D. Arzamendi).  
Available online 28 January 2015