

ECG Contest

ECG, July 2015

ECG de julio de 2015

Antonio Tello-Montoliu

Servicio de Cardiología, Hospital Clínico Universitario Virgen de la Arrixaca, Murcia, Spain



A 60-year-old man with hypertension as the only risk factor and a family history of sudden death of his father at the age of 28 years was diagnosed with prostate carcinoma in 2010 and treated with brachytherapy, which is currently being managed by the urology department. The patient was seen by the out-of-hospital emergency services for oppressive retrosternal chest pain, with no radiation but accompanied by general malaise. He underwent an electrocardiogram (ECG) and was given sublingual diazepam. As the symptoms worsened, he was sent to the hospital's emergency department, where an ECG was performed (Figure).

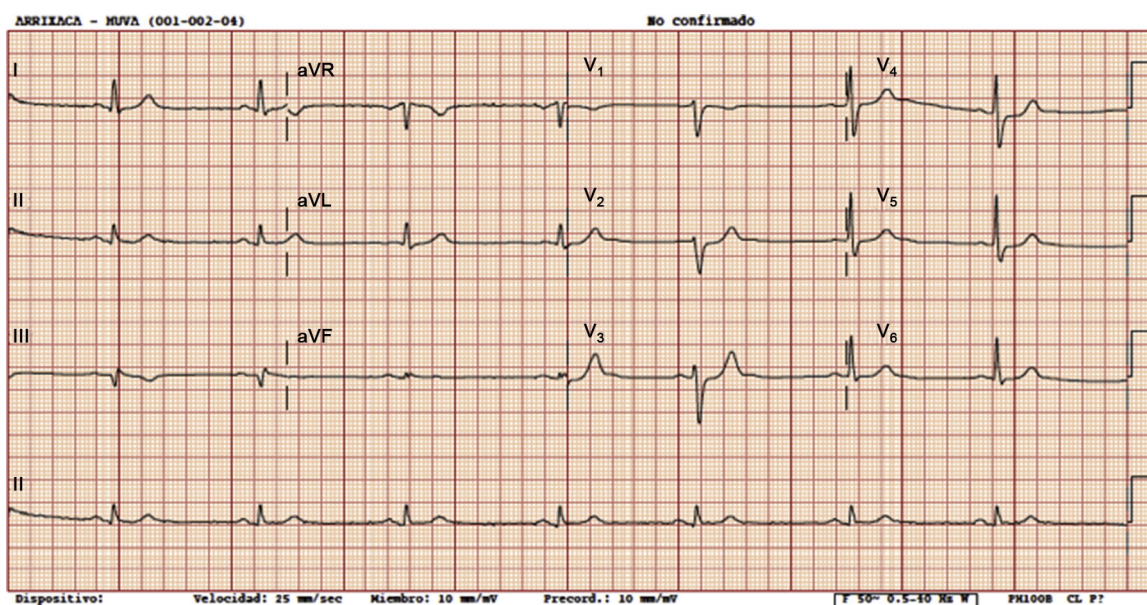


Figure.

Suggest a solution to this ECG Contest at <http://www.revespcardiol.org/es/electroreto/68/07> (only Spanish). The answer will be published in the next issue (August 2015). #RetoECG.

E-mail address: atellomont@hotmail.com