

The *SCN5A*^{p.Arg219His} mutation was present in all affected persons in the paternal family. The phenotype was very similar to that described earlier, although in the literature, SSS was reported in unrelated patients.^{1,2} This is therefore the first time that cosegregation of *SCN5A*^{p.Arg219His} with familial paralysis of the atrium^{1,2} has been reported (Figure 2). In addition, 2 women aged 58 years and 34 years (II.8 and III.7, respectively) were identified as asymptomatic carriers. This finding fits with the later clinical presentation in women (Figure 1D).

The *HCN4*^{p.Arg1068His} mutation and the *KCNE1*^{p.Asp85Asn} polymorphism were transmitted by the mother, whose clinical study was normal. It was not possible to study the other members of the mother's family. Given that lack of cosegregation with SSS, *HCN4*^{p.Arg1068His} is considered a variant of unknown significance that does not explain FPA.

Sick sinus syndrome is defined as abnormal formation and propagation of the electric impulse in the sinus node. It is characterized by sinus bradycardia, sinoatrial block, sinus arrest, chronotropic incompetence, and/or atrial tachyarrhythmias (essentially atrial fibrillation). It is a common disorder in elderly individuals but rarely seen in young people. A permanent PM needs to be implanted in approximately 50% of affected individuals.⁴ According to data from the Spanish Pacemaker Registry,⁵ SSS and atrial fibrillation/atrial flutter with bradycardia account for approximately 36% of PM implantations. There does not appear to be any predominance of one sex or the other (ratio of men to women, 0.98) although atrial fibrillation/atrial flutter with bradycardia occurs predominantly in men (ratio, 1.7).⁵

We consider the *SCN5A*^{p.Arg219His} mutation the cause of the familial condition as it shows cosegregation with the disease and has been described previously. The *HCN4*^{p.Arg1068His} mutation is a variant of unknown significance that could act as a disease modifier, although it is not the cause. These findings would enable genetic counselling to be provided to individual carriers (Figure 2). In the case of asymptomatic patients, follow-up with electrocardiogram, Holter, and echocardiographic studies (given the association with dilated cardiomyopathy) were planned, and, depending on the symptoms, exercise testing was considered to detect chronotropic incompetence. The familial study, in this case, was essential to clarify which of the documented genetic variants was the cause of the familial paralysis of the atrium.

FUNDING

This study was partly funded by the *Instituto de Salud Carlos III* (grants P114/0967, RD12/0042/0049, and RD12/0042/0066).

Carolina Robles,^a María Gallego-Delgado,^a Víctor Castro-Urda,^b Carmen Muñoz-Esparza,^c Emiliano González-Vioque,^d and Pablo García-Pavía^{a,*}

^aUnidad de Insuficiencia Cardíaca y Cardiopatías Familiares, Servicio de Cardiología, Hospital Universitario Puerta de Hierro, Majadahonda, Madrid, Spain

^bUnidad de Arritmias, Servicio de Cardiología, Hospital Universitario Puerta de Hierro, Majadahonda, Madrid, Spain

^cUnidad de Cardiopatías Familiares, Servicio de Cardiología, Hospital Clínico Universitario Virgen de la Arrixaca, El Palmar, Murcia, Spain

^dServicio de Bioquímica, Hospital Universitario Puerta de Hierro, CIBERER, Majadahonda, Madrid, Spain

*Corresponding author:

E-mail address: pablogpavia@yahoo.es (P. García-Pavía).

Available online 22 August 2015

REFERENCES

- Gosselin-Badaroudine P, Keller DI, Huang H, Pouliot V, Chatelier A, Osswald S, et al. A proton leak current through the cardiac sodium channel is linked to mixed arrhythmia and the dilated cardiomyopathy phenotype. *Plos One*. 2012;7:e38331.
- Abe K, Machida T, Sumitomo N, Yamamoto H, Ohkubo K, Watanabe I, et al. Sodium channelopathy underlying familial sick sinus syndrome with early onset and predominantly male characteristics. *Circ Arrhythm Electrophysiol*. 2014;7:511-7.
- Milanesi R, Baruscotti M, Gnecci-Ruscone T, DiFrancesco D. Familial sinus bradycardia associated with a mutation in the cardiac pacemaker channel. *N Engl J Med*. 2006;354:151-7.
- Gui J, Wang T, Jones RP, Trump D, Zimmer T, Lei M. Multiple loss-of-function mechanisms contribute to *SCN5A*-related familial sick sinus syndrome. *Plos One*. 2010;5:e10985.
- Coma-Samartín R, Cano-Pérez O, Pombo-Jiménez M. Registro Español de Marcapasos. XI Informe Oficial de la Sección de Estimulación Cardíaca de la Sociedad Española de Cardiología (2013). *Rev Esp Cardiol*. 2014;67:1024-38.

<http://dx.doi.org/10.1016/j.rec.2015.06.014>

Impella CP® Circulatory Support Device as a Bridge to Heart Transplantation: First Experience in Spain



Dispositivo de asistencia circulatoria Impella CP® como terapia puente a trasplante cardíaco: primera experiencia en España

To the Editor,

Death due to cardiogenic shock is still high (50%-80%) despite early coronary revascularization, intra-aortic balloon counterpulsation, and short-term mechanical ventricular assist devices (VADs; extracorporeal membrane oxygenator or Levitronix®).

One recently approved short-term percutaneous VAD, the Impella CP®, provides a theoretical flow of up to 4 L.

We report the case of a 37-year-old woman with cardiomyopathy after childhood thoracic chemotherapy and radiotherapy who

had spent 6 months on the elective heart transplant list due to advanced heart failure. When the patient was admitted with refractory cardiogenic shock despite inotropic therapy (INTERMACS level 2), it was decided to implant a VAD as a bridge to heart transplant. However, due to the history of thoracic irradiation, reduced size of the left ventricle (46 mL), and severe dysfunction of the right ventricle, she was a suboptimal candidate for a surgical VAD, and a percutaneous 4-L Impella CP® device was implanted. Implantation was performed without complications via a right femoral approach (Figure), and the mean flow achieved of 3 L improved her clinical and hemodynamic profile (Table). Given the cardiogenic shock and dependence on a short-term VAD, she was prioritized on the national emergency heart transplant waiting list. The device was stopped after 10 days because it displayed a "high motor current" alarm. Because the patient showed renewed hemodynamic deterioration, the dysfunctional device was removed and a new one was implanted. After 4 days with this second

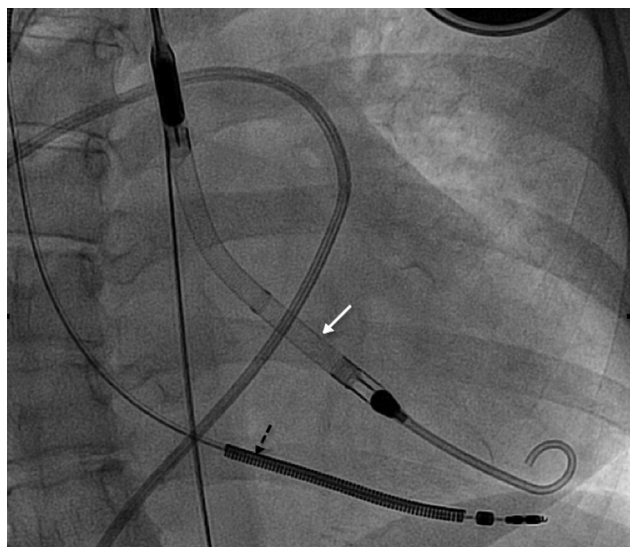

Figure. Fluoroscopy during the implantation of the Impella CP[®] (white arrow) showing the lead of the implantable cardioverter defibrillator (black arrow).

device, the patient showed left homonymous hemianopia due to right occipital hemorrhage requiring urgent surgical drainage. It was decided to stop anticoagulation therapy and, thus, the VAD was removed while high-dose vasoactive support was maintained. After 2 weeks of proper neurological development and no hemorrhage and due to progressive hemodynamic deterioration, an intra-aortic balloon pump was implanted, without anticoagulation, and the patient was included on the emergency heart transplant list. The transplant was successfully performed 48 hours later. Ten months after the heart transplant, the patient has minimal neurological sequelae that do not impede a normal life.

The Impella device contains an axial pump that is placed across the aortic valve and continually draws blood from the left ventricle to the aorta. Recent trials support the use of the Impella 2.5 (percutaneous, 13 Fr) in high-risk coronary interventions but the flow provided (1.5-2.0 L) is insufficient for cardiogenic shock.^{1,2} The current report of the use of the Impella CP[®] (4 L) as a bridge to heart transplant is the first in Spain.

Table
Hemodynamic and Analytical Data Before and After Impella CP[®] Implantation

	Before	After 48 hours
<i>Swan-Ganz, mmHg</i>		
RAP	18	10
PAP	52/28 (36)	43/20 (28)
PWP	28	18
CO/CI	2.2/1.4	3.5/2.4
<i>Liver function, GOT/GPT</i>	139/73	164/44
<i>Perfusion: lactic acid</i>	2.3	1.0
<i>Renal function</i>		
Creatinine, mg/dL	2.3	1.1
Diuresis, mL/h	20	70

CI, cardiac index; CO, cardiac output; PAP, pulmonary artery pressure; PWP, pulmonary wedge pressure; RAP, right atrial pressure.

From this experience, we learned that percutaneous implantation is straightforward and can be performed in the catheterization laboratory in a mean time of 15 min. For implantation, a 14-Fr introducer is required to pass the motor (12 Fr). This introducer is the peel-away type and fits a flexible 10-Fr sheath. This difference in diameter can allow bleeding around the sheath. In our patient, the risk of bleeding was controlled by adjusting the slipknot of the Proglide[®] around the 10-Fr sheath. Additionally, the Impella device moved between 2 cm and 4 cm on 4 occasions. Relocalization was performed at the bedside with echocardiographic monitoring.

The Impella device can cause hemolysis, which can be reduced by optimization of the minimum revolutions required to maintain the desired flow; in our patient, the initial flow of 3.3 L with the maximum power (46 000 rpm) was later decreased to between 2.8 L and 3.0 L (44 000 rpm) to reduce hemolysis. This flow was sufficient to stabilize the patient (1.43 m² body surface area) without overloading the right ventricle. If the flow had been insufficient and/or there had been refractory right ventricle failure, an extracorporeal membrane oxygenator would have been implanted as a VAD.

The first notable complication was the motor dysfunction that occurred on the tenth day after surgery. This is the first report of mechanical failure due to exceeding the approved duration of use (7 days). Currently, the mean waiting time for an urgent heart transplant is 8 days. Thus, this device offers hemodynamic support for a reasonable period of time while a patient is waiting on a national emergency transplant list; once the approved duration of use has elapsed, individualization of the strategy is required: replacement of the Impella Levitronix Centrimag[®] or implantation of another longer-lasting VAD (Berlin Heart EXCOR[®], HeartMate II, or HeartWare).

The second noteworthy complication was cerebral hemorrhage, which occurred when the patient was anticoagulated with sodium heparin with an activated clotting time of 168 s (recommended time, 160-180 s). The prevalence of hemorrhagic complications for axial flow devices is 24%; this type of flow can cause mechanical shear stress, a syndrome termed acquired von Willebrand syndrome.³ This condition affects small vessels; the most common complications being gastrointestinal bleeding. In our patient, we could not rule out this syndrome or the presence of pre-existing cerebral arteriovenous malformations.

In conclusion, the Impella CP[®] device can be an alternative to surgical VAD in selected patients with cardiogenic shock as a bridge to decision-making or heart transplant. This device is limited to between 7 and 10 days and is not without serious complications.

Inés Sayago,^{a,*} Fernando Domínguez-Rodríguez,^a
Juan Francisco Oteo-Domínguez,^b Manuel Gómez-Bueno,^a
Javier Segovia,^a and Luis Alonso-Pulpón^a

^aServicio de Cardiología, Unidad de Insuficiencia Cardíaca Avanzada y Trasplante Cardíaco, Hospital Universitario Puerta de Hierro, Majadahonda, Madrid, Spain

^bServicio de Cardiología, Unidad de Cardiología Intervencionista, Hospital Universitario Puerta de Hierro, Majadahonda, Madrid, Spain

* Corresponding author:

E-mail address: inessayago@gmail.com (I. Sayago).

Available online 28 August 2015

REFERENCES

1. Seyfarth M, Sibbing D, Bauer I, Fröhlich G, Bott-Flügel L, Byrne R, et al. A randomized clinical trial to evaluate the safety and efficacy of a percutaneous left ventricular assist device versus intra-aortic balloon pumping for treatment of cardiogenic shock caused by myocardial infarction. *J Am Coll Cardiol*. 2008;52:1584-8.
 2. Lauten A, Engström AE, Jung C, Empen K, Erne P, Cook S, et al. Percutaneous left-ventricular support with the Impella-2.5-assist device in acute cardiogenic

shock: results of the Impella-EUROSHOCK-registry. *Circ Heart Fail*. 2013;6:23-30.
 3. Davis ME, Haglund NA, Tricarico NM, Keebler ME, Maltais S. Development of acquired von Willebrand syndrome during short-term micro axial pump support: implications for bleeding in a patient bridged to a long-term continuous-flow left ventricular assist device. *ASAIO J*. 2014;60:355-7.

<http://dx.doi.org/10.1016/j.rec.2015.06.016>

Successful Use of Maribavir for Drug-resistant Cytomegalovirus Colitis in a Heart Transplant Recipient



Uso exitoso de maribavir en un caso de colitis por citomegalovirus farmacorresistente en un paciente receptor de un trasplante cardiaco

To the Editor,

Cytomegalovirus (CMV) infection is associated with significant morbidity and unfavorable outcomes in transplant recipients. Clinical resistance to classic anti-CMV drugs (ganciclovir, valganciclovir, foscarnet and their combinations) and the occurrence of unacceptable adverse events may confront attending physicians with seemingly insoluble situations. Maribavir, a novel benzimidazole antiviral agent, may be of help in this setting.

We report the case of a 45-year-old male recipient of a CMV D-/R+ heart transplant. Immunosuppression consisted of basiliximab induction (2 doses) and triple therapy with tacrolimus, mycophenolate mofetil, and prednisone. Since he was not at high risk for CMV, a preemptive therapy strategy was planned.

Four weeks after heart transplantation, the patient developed mild fever, abdominal pain, and diarrhea. Physical examination

revealed hepatosplenomegaly. Cytomegalovirus viral load (COBAS® AmpliPrep/COBAS® TaqMan® CMV test) was 4270 copies/mL. He was treated with intravenous ganciclovir (5 mg/kg twice daily) for 3 weeks, with no improvement in his symptoms or CMV viremia. Foscarnet (60 mg/kg once daily iv) was added, and mycophenolate was switched to azathioprine to decrease diarrhea.

After 3 additional weeks of combined anti-CMV treatment, there was clinical improvement, with resolution of diarrhea and 2 low-indeterminate CMV loads (< 150 copies/mL). Moderate generalized muscle cramps and hypocalcemia were attributed to foscarnet. Anti-CMV therapy was switched to oral valganciclovir (900 mg twice daily). Two weeks later, the diarrhea resumed, with persistently low CMV PCR loads. A colonoscopy confirmed CMV colitis (Figure), and viral load increased to 7500 copies/mL. Baseline immunosuppression was changed: tacrolimus and azathioprine were replaced by a combination of cyclosporine and everolimus. Foscarnet (55 mg/kg once daily iv) was added to oral valganciclovir. Again, muscle cramps and hypocalcemia developed, with worsening renal function (Creatinine: 3 mg/dL) and neutropenia (2.200 leukocytes/mm³) associated with foscarnet and valganciclovir. Because of clinical resistance to different combinations of anti-CMV therapies over 10 weeks and drug toxicities, we decided to initiate oral maribavir (200 mg/8 h) as an off-label therapy, with a baseline viral load of 1680 copies/mL. Three weeks later, CMV PCR counts were reduced to

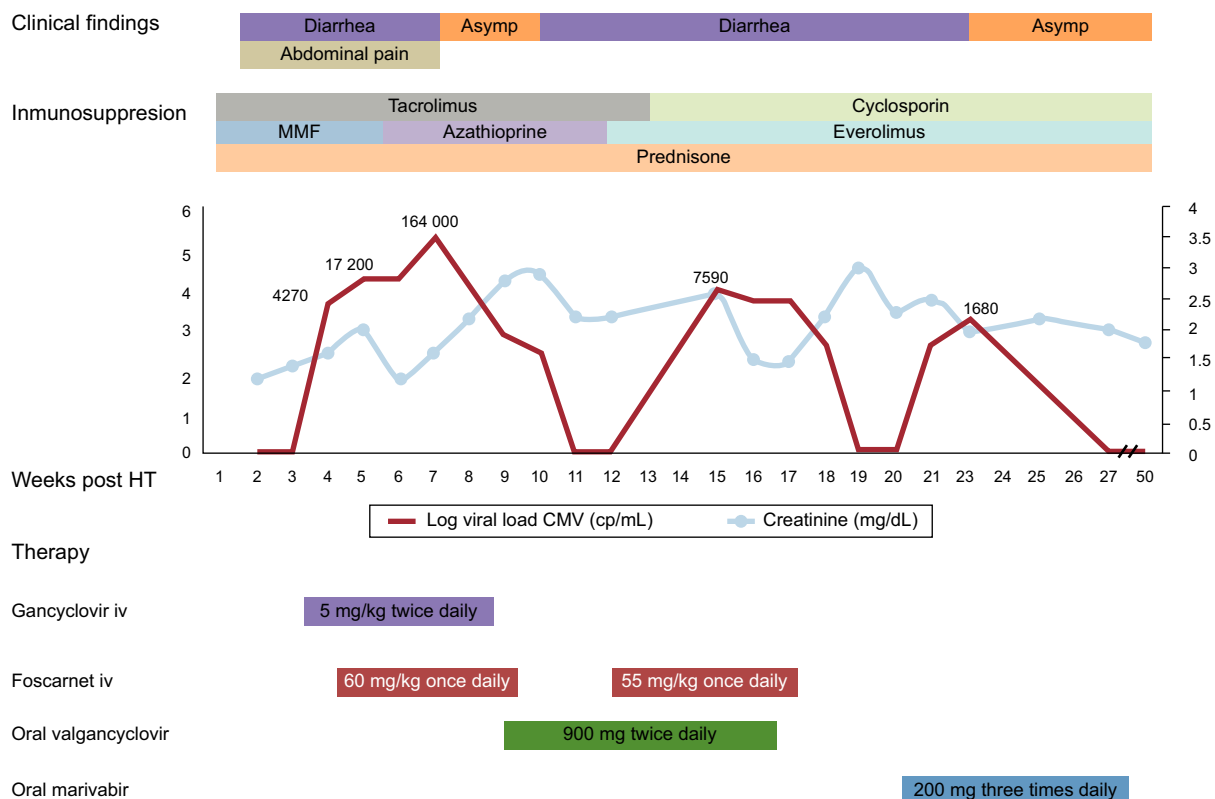


Figure. Timeline of clinical findings, treatment and cytomegalovirus viral load. Cytomegalovirus plasma viral loads and renal function are shown as weekly values. Abd, abdominal; Asymp, asymptomatic; CMV, cytomegalovirus; HT, heart transplantation; i.v., intravenous; MMF, mycophenolate mofetil.