

## ECG Contest

### ECG, April 2016



### ECG de abril de 2016

Albert Ariza Solé

Unidad Coronaria, Área de Enfermedades del Corazón, IDIBELL, Hospital Universitari de Bellvitge, L'Hospitalet de Llobregat, Barcelona, Spain

The patient was a 55-year-old man, a smoker, who reported a 3-day history of severe chest pain, symptoms and signs of autonomic dysfunction, and poor general health. At home, he was found to have severe hypotension and bradycardia with signs of peripheral hypoperfusion. External pacing was undertaken, followed by intubation and mechanical ventilation. The electrocardiogram carried out on arrival at the hospital is shown in the [Figure](#).

An echocardiogram revealed mild left ventricular dilation with very severe systolic dysfunction. Right ventricle was not dilated and there was no evidence of valve disease or pericardial effusion. He arrived at the hospital with severe hypotension, despite the administration of high doses of inotropic agents and vasopressors, as well as metabolic acidosis and renal failure. What is the diagnosis and the immediate therapeutic approach?

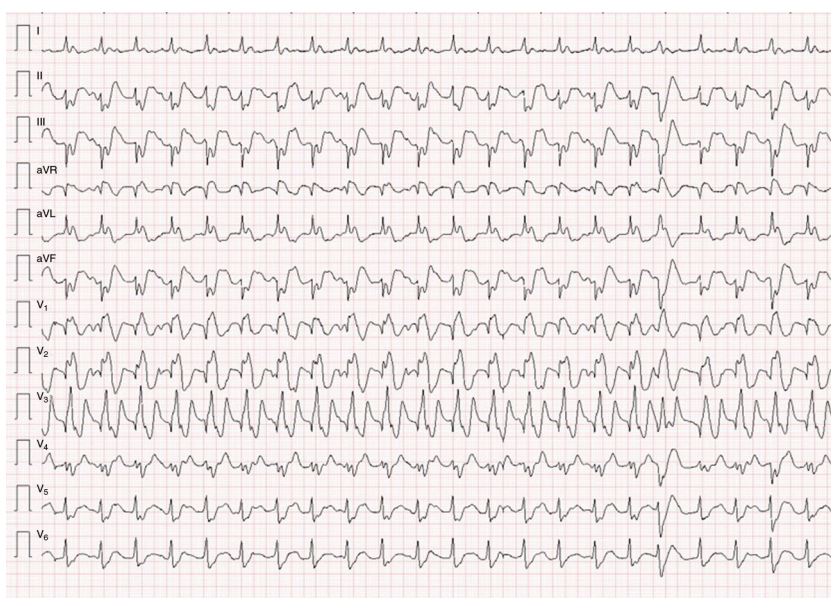


Figure.

Suggest a solution to this ECG Contest at <http://www.revespcardiol.org/es/electroreto/69/04> (only Spanish). The answer will be published in the next issue (May 2016). #RetoECG.

E-mail address: [aariza@bellvitgehospital.cat](mailto:aariza@bellvitgehospital.cat)