

Image in cardiology

Aberrant Subclavian and Vertebrals Arteries in Acute Aortic Syndrome



Arterias subclavia y vertebrales aberrantes en síndrome aórtico agudo

Francisco Manresa-Manresa,* Sergio Villar-Jiménez, and Manuel Ángel Canalejo-Raya

Unidad de Angiología y Cirugía Vascolar, Hospital Universitario Virgen del Rocío, Seville, Spain

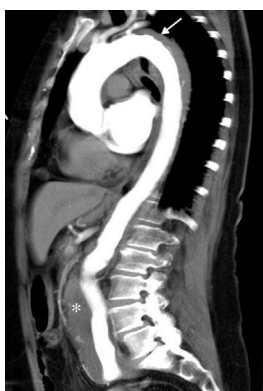

Figure 1.

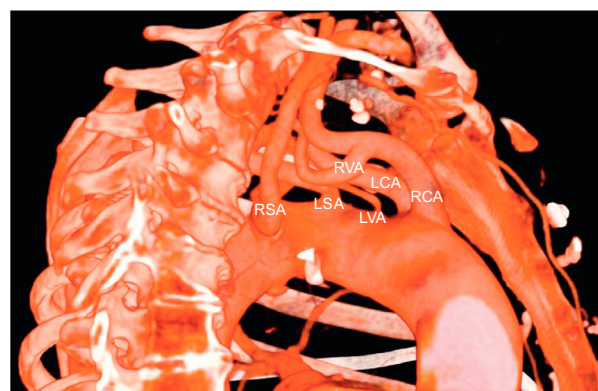


Figure 2.

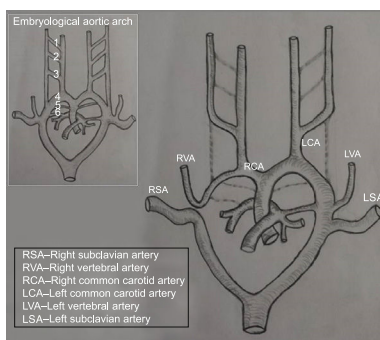


Figure 3.

A 72-year-old woman, an active smoker with hypertension and dyslipidemia, presented with sudden interscapular pain and a hypertensive crisis. Given the suspicion of acute aortic syndrome, computed tomography angiography was performed (Figure 1). This revealed an intramural hematoma distal to the exit of the left subclavian artery with a thrombosed false lumen (arrow), and an uncomplicated abdominal aortic aneurysm of 6.5 cm (asterisk). Angiography also revealed an anatomically abnormal configuration of the aortic arch (Figure 2): an aberrant right subclavian artery (RSA) originating distal to the left subclavian artery (LSA), the left vertebral artery (LVA) originating directly from the aortic arch between the left carotid artery (LCA) and the LSA, and the right vertebral artery (RVA) exiting from the right carotid artery (RCA). This anatomy can be explained embryologically (Figure 3) by abnormal involution of the embryonic aortic arches with persistence of the right thoracic aorta as the origin of the RSA. The patient was haemodynamically stable; therefore she was treated medically in the intensive care unit.

This patient's unusual aortic arch anatomy would become more relevant in the planning of a potential surgical intervention, should she become clinically unstable. Implantation of an endoprosthesis covering the origin of the RSA would require revascularization of the right upper limb (right carotid-subclavian bypass), due to the absence of the usual compensation provided by retrograde flow in the RVA when it has a normal origin in the RSA. We have not found this anatomical configuration of the aortic arch described elsewhere in the literature.

* Corresponding author:
E-mail address: franman.m@gmail.com (F. Manresa-Manresa).
Available online 29 March 2016