

Image in cardiology

Hybrid Culotte for Bifurcations With Side Branch Lesion



Culotte híbrido en bifurcaciones con lesión en rama lateral

Manuel Pan, Soledad Ojeda, and Jorge Chavarría*

Departamento de Cardiología, Hospital Reina Sofía, Universidad de Córdoba (IMIBIC), Córdoba, Spain

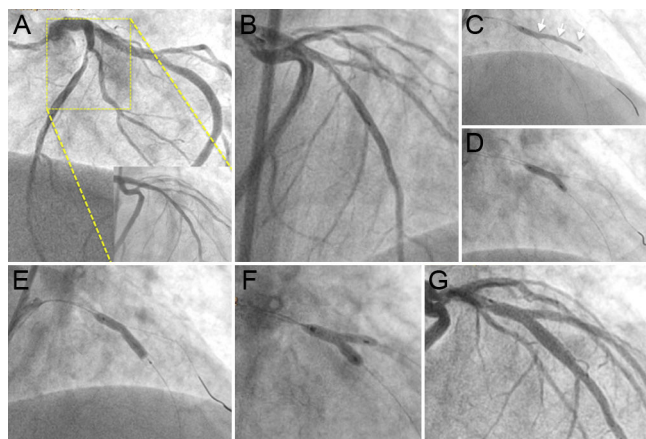


Figure 1.

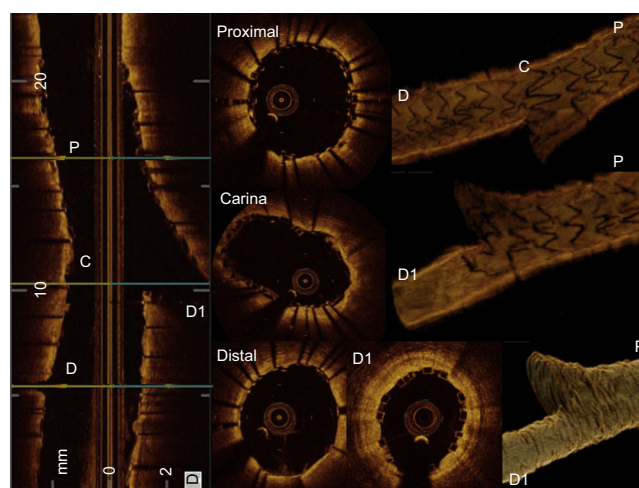


Figure 2.

A diabetic 78-year-old man with unstable angina was admitted to the hospital. Multivessel disease with preserved left ventricular function was observed. The left anterior descending artery (LAD) showed a {1,1,1} bifurcation lesion with diffuse stenosis at the diagonal branch (D1) (Figure 1A). After predilation of D1, a long dissection occurred (Figure 1B). A culotte technique was performed by the implantation of a 2.5 x 28 mm bioresorbable vascular scaffold (BVS) at D1-LAD (Figure 1C), and a metallic drug eluting stent (DES) at LAD. After BVS implantation, postdilation with a noncompliant balloon 2.75 x 15 mm through the struts of the BVS (Figure 1D) was performed and a 3.0 x 18 mm DES was implanted at LAD (Figure 1E). The procedure was finished with kissing balloon inflation (3 + 2.5 mm noncompliant balloon diameters) (Figure 1F). The final result is shown in Figure 1G. The final optical coherence tomography with excellent result is shown in Figure 2. When using this technique, the fragility of the BVS is an advantage. The device does not offer any resistance to dilation through the struts. Another advantage of this strategy is the possibility of using conventional kissing balloon inflation. Although it induces BVS proximal strut fracture, the overlapped metallic stent preserves the scaffolding in the proximal part of the bifurcation. To minimize the potential risk of scaffold thrombosis, dual antiplatelet therapy for at least 12 months seems an advisable option. Finally, studies are needed to determine the value of this technique in comparison with other therapeutic strategies in complex bifurcation lesions.

CONFLICTS OF INTEREST

M. Pan has received minor lecture fees from Abbott and S. Ojeda has received minor lecture fees from Abbott.

* Corresponding author:
E-mail address: jorgechv@yahoo.com (J. Chavarría).
Available online 26 July 2016