

2. Hidalgo-Urbanos R, Carrascosa-Rosilloa C, Martínez-Quesada M, González-Valdayoa M. Trombosis subaguda de *stent* en paciente con púrpura trombocitopénica idiopática tratado con inmunoglobulina intravenosa. *Rev Esp Cardiol*. 2008;61:329–331.
3. Zaid G, Dawod S, Rosenschein U. Immune thrombocytopenic purpura and myocardial infarction: a dilemma of management. *Isr Med Assoc J*. 2013;15:775–776.
4. Rayoo R, Sharma N, Van Gaal WJ. A case of acute *stent* thrombosis during treatment with the thrombopoietin receptor agonist peptide—romiplostim. *Heart Lung Circ*. 2012;21:182–184.
5. Kikuchi S, Hayashi Y, Fujioka S, Kukita H, Ochi N. A case of intracoronary *stent* implanted for acute myocardial infarction in an elderly patient with idiopathic thrombocytopenic purpura. *Nihon Ronen Igakkai Zasshi*. 2002;39:88–93.
6. Moretti C, Teresa Lucciola M, Morena L, et al. Idiopathic thrombocytopenic purpura and percutaneous coronary stenting: a dangerous duo? *Int J Cardiol*. 2008;130:e96–e97.

<http://dx.doi.org/10.1016/j.rec.2016.06.010>

1885-5857/

© 2016 Sociedad Española de Cardiología. Published by Elsevier España, S.L.U. All rights reserved.

## Acute Clinical Presentation of Pseudoaneurysm and Aortopulmonary Fistula as a Very Late Complication of Aortic Coarctation Patch Repair



### Presentación clínica aguda de pseudoaneurisma y fístula aortopulmonar como complicación tardía de la reparación quirúrgica de la coartación de aorta

#### To the Editor,

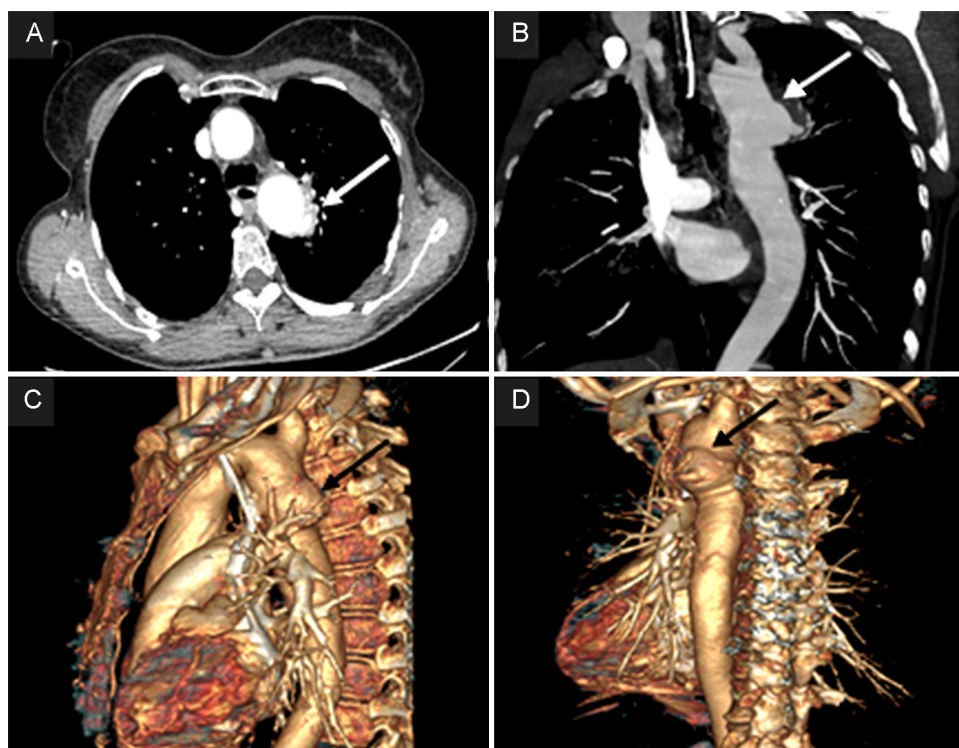
A 57-year-old woman was admitted to the emergency room of our hospital for sudden lipothymia and copious hemoptysis. Twenty-seven years previously she had undergone Dacron patch aortoplasty for aortic coarctation with the Cooley technique.<sup>1</sup> On admission, the patient was hypotensive, dyspneic and anemic (Hb 6.3 mg/dL). A computed tomography scan showed a 36-mm pseudoaneurysm in the proximity of the aortic isthmus, perforated through a 6-mm fistula into the posterolateral aspect of the left lung (Figure 1A-D).

Thoracic endovascular aortic repair was not indicated due to unsuitable vascular access and lack of appropriate landing zones for endograft placement. The patient underwent emergency surgical reoperation.

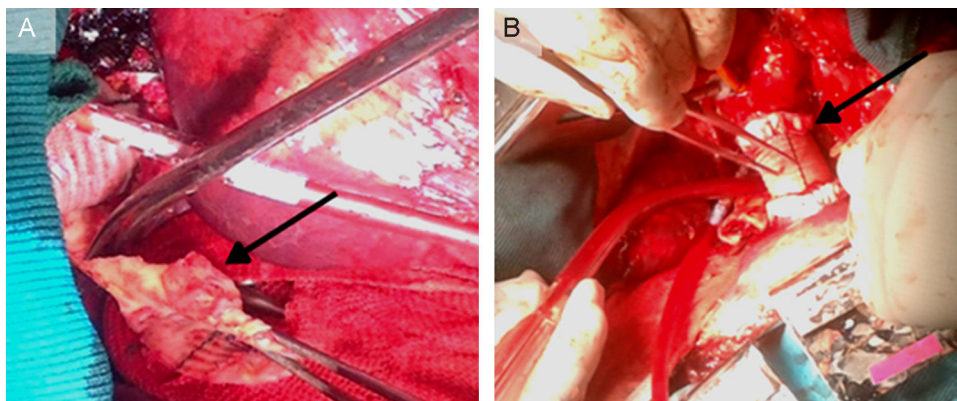
The chest was entered through a fourth intercostal space left thoracotomy. The proximal thoracic aorta immediately distal to the left subclavian artery and the descending aorta at the seventh intercostal space level were isolated for subsequent cross clamping. At the level of the previously coarctated segment, a pseudoaneurysmatic dilatation of the aorta was observed, tenaciously adherent to the left upper pulmonary lobe. On moderate (32 °C) hypothermic cardiopulmonary bypass, by using left femoral vein drainage and dual femoral artery and distal aortic arch arterial return, the descending aorta was proximally and distally cross clamped. The pseudoaneurysm was partially dissected free and was then excised, leaving the anteromedial wall attached to the lung, thus penetrating into the pulmonic parenchyma. The Dacron patch showed a 1-cm disruption of the suture line (Figure 2A).

The continuity of the descending thoracic aorta was reconstructed with a 24-mm Dacron tube graft (Figure 2B). The patient was hemodynamically stable after the intervention, with no evidence of hemorrhage, but unfortunately died 2 months later from sepsis.

Aortic coarctation represents approximately 5% of all congenital heart malformations, with an incidence of 0.2–0.6 per 1000 live births.<sup>2</sup> Surgical correction in young patients is indicated and many



**Figure 1.** Computed tomography angiography scan shows the 36-mm pseudoaneurysm (arrows), located 13 mm distal to the origin of the left subclavian artery, perforated through a 6-mm fistula with the bronchial tree. A: 2D computed tomography angiography scan, axial view. B: 2D coronal view. C: 3D sagittal plane reconstruction. D: 3D left posterior reconstruction. Arrows show the 36 mm pseudoaneurysm located 13 mm distal to the origin of the left subclavian artery, perforated through a 6 mm fistula with the bronchial tree.



**Figure 2.** A: operative findings: the Dacron patch, a segment of the aortic wall at the level of the suture line dehiscence and periaortic inflammatory tissue (arrow) are evident. B: the surgical repair: Dacron tube graft descending aorta reconstruction (arrow), with suture line being reinforced by Teflon strips. The site of the aortic arch cannulation is also quite evident.

techniques have been proposed. The longitudinal Dacron patch aortoplasty of the aortic constricted segment is preferred by many surgeons as it potentially allows subsequent growth of the aortic wall and reduces the number of collaterals to be tied off. Several postoperative complications have been described, such as restenosis, aneurysm, and pseudoaneurysm, frequently developing many years after the intervention.<sup>3</sup>

Aneurysm and pseudoaneurysm may occur in up to 10% of patients, at a mean interval from operation superior to 12 years.<sup>4</sup>

In our patient, disruption of the aortic Dacron patch suture line was evident and clearly generated the pseudoaneurysm, composed of thrombotic material surrounded by fibrous and inflammatory tissue. The progressively expanding pseudoaneurysm, mainly in older patients, may compress and erode the pulmonary parenchyma, leading—as in our patient—to the aortopulmonary fistula.

As previously observed,<sup>5</sup> the present case confirms that sudden lipothymia, hemoptysis, and anemia could be clinical signs indicative of aortopulmonary fistula in patients who have undergone aortic coarctation repair even many decades earlier. Lifelong follow-up after coarctation aortoplasty is recommended.

Giovanni Alfonso Chiariello,\* Piergiorgio Bruno, Andrea Mazza, Marco Luciani, Franco Glicca, and Massimo Massetti

Cardiovascular Sciences Department, Catholic University of The Sacred Heart, Agostino Gemelli Policlinic, Rome, Italy

\*Corresponding author:

E-mail address: [gio.chiariello88@tiscali.it](mailto:gio.chiariello88@tiscali.it) (G.A. Chiariello).

Available online 19 September 2016

## REFERENCES

1. Reul Jr GJ, Kabbani SS, Sandiford FM, Wukasz DC, Cooley DA. Repair of coarctation of the thoracic aorta by patch graft aortoplasty. *J Thorac Cardiovasc Surg.* 1974;68:696–704.
2. Lemaire A, Cuttone F, Desgùe J, et al. Late complication after repair of aortic coarctation. *Asian Cardiovasc Thorac Ann.* 2015;23:423–429.
3. Brown ML, Burkhart HM, Connolly HM, Dearani JA, Hagler DJ, Schaff HV. Late outcomes of reintervention on the descending aorta after repair of aortic coarctation. *Circulation.* 2010;122:81–84.
4. von Kodolitsch Y, Aydin MA, Koschyk DH, et al. Predictors of aneurysmal formation after surgical correction of aortic coarctation. *J Am Coll Cardiol.* 2002;39:617–624.
5. Algaba Calderón A, Jara Chinarro B, Abad Fernández A, Isidoro Navarrete O, Ramos Martos A, Juretschke Moragues MA. Recurrent hemoptysis secondary to an aorto-bronchial fistula. *Arch Bronconeumol.* 2005;41:352–354.

<http://dx.doi.org/10.1016/j.rec.2016.08.005>  
1885-5857/

© 2016 Sociedad Española de Cardiología. Published by Elsevier España, S.L.U. All rights reserved.

## Safety and Effectiveness of Percutaneous Closure of Left Atrial Appendage in Patients With Intracranial Hemorrhage



### Eficacia y seguridad del cierre percutáneo de orejuela izquierda en pacientes con hemorragia intracranial

#### To the Editor,

Oral anticoagulants (OAC) are the treatment of choice for preventing ischemic stroke in patients with nonvalvular atrial fibrillation (NVAF).<sup>1</sup> However, these drugs (including the new OACs) are associated with an increased risk of serious complications such as intracranial hemorrhage (ICH).<sup>2</sup> Restarting OACs after an ICH triples the risk of hemorrhagic events,<sup>3</sup> therefore their use in this context is controversial and can even be contraindicated.<sup>4</sup> In addition, there is little evidence on the safety of new OACs following ICH.<sup>4</sup> Percutaneous closure of the left atrial appendage (LAA) is an effective therapeutic alternative to OACs.<sup>5</sup> However,

there are insufficient data on the safety and effectiveness of this procedure in patients with ICH.<sup>6</sup>

Our objective was to evaluate the safety and effectiveness of LAA closure in patients with an indication for OACs due to NVAF with a history of ICH.

The study included all patients with an indication for OACs for NVAF and a history of ICH referred to our unit between June 2009 and June 2016 for LAA closure. We analyzed clinical, echocardiographic, and procedure-related variables. The devices used for LAA closure were the Amplatzer Cardiac Plug, the Amplatzer Amulet (both St. Jude Medical), and the Watchman Implant (Boston Scientific). After the procedure, patients were treated with antiplatelet therapy or anticoagulation (low-molecular weight heparin) for at least 45 days. The decision on antiplatelet therapy vs anticoagulation was made at the discretion of the surgeon in consensus with neurology. At follow-up (at 45 days, 6 months, 12 months, and annually thereafter) we analyzed the following variables: death, ischemic stroke, and hemorrhagic