

ECG Contest

ECG, December 2016

ECG de diciembre de 2016

Jaume Francisco-Pascual*

Unitat d'Arrítmies, Servei de Cardiologia, Hospital Universitari Vall d'Hebron, Universitat Autònoma de Barcelona, Barcelona, Spain



A single-chamber implantable cardioverter defibrillator (ICD) was implanted as secondary prevention in a 7-year-old patient with Brugada syndrome. Ten days after the implantation, the patient came to the emergency department with chest discomfort. The electrocardiogram shown in the [Figure](#) was recorded (from precordial leads).

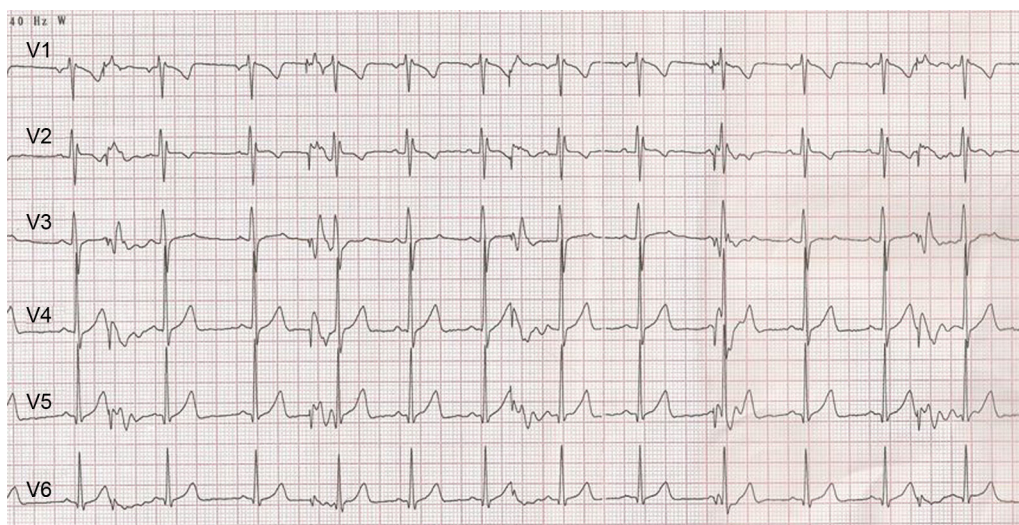


Figure.

What is the most likely diagnosis?

1. ICD lead dislodgement.
2. Inappropriate antitachycardia therapy.
3. Early depletion of ICD battery.
4. ICD lead fracture.

Suggest a solution to this ECG Contest at <http://www.revespcardiol.org/es/electroreto/69/12>. The answer will be published in the next issue (January 2017). #RetoECG.

* Corresponding author:
E-mail address: jafranci@vhebron.net