

ECG Contest

ECG, January 2017

ECG de enero de 2017

Zorba Blázquez Bermejo,\* Laura Peña Conde, and Rafael Peinado

Servicio de Cardiología, Hospital Universitario La Paz, Madrid, Spain



A 64-year-old man with diabetes and dyslipidemia who had an acute myocardial infarction in 1998 and stents implanted in the anterior descending and right coronary arteries. In a recent echocardiogram, he had mild left ventricular dysfunction (left ventricular ejection fraction of 46%). He attended the emergency department due to 6-hour history of general discomfort, dizziness, and sweating, with a blood pressure of 100/68 mmHg and heart rate of 160 bpm. Physical examination revealed no evidence of heart failure. An electrocardiogram was performed, as shown in Figure.

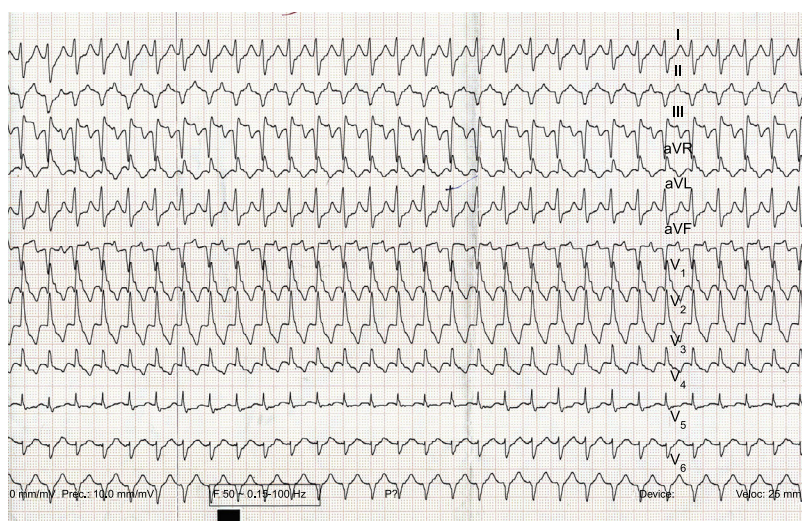


Figure.

What would be your diagnosis and treatment of this patient?

1. Atrial flutter. Electrical cardioversion and subsequent ablation of the cavotricuspid isthmus.
2. Ventricular tachycardia. Cardioversion and defibrillator implantation.
3. Atrioventricular nodal reentrant tachycardia. Vagal maneuvers or intravenous adenosine and subsequent intravenous catheter ablation.
4. Ventricular tachycardia. Cardioversion and electrophysiological study before any therapeutic decision.

Suggest a solution to this ECG Contest at <http://www.revespcardiol.org/es/electroreto/70/01>. The answer will be published in the next issue (February 2017). #RetoECG.

\* Corresponding author:  
E-mail address: [zorbablbe@gmail.com](mailto:zorbablbe@gmail.com) (Z. Blázquez Bermejo).