

Images in cardiology

Metallic Stent Optimization in Dedicated Bifurcation Stent Assessment



Optimización de *stent* metálico en la evaluación de *stent* específico para bifurcaciones

Santiago Jesús Camacho Freire,* Javier León Jiménez, and Antonio Enrique Gómez Menchero

Servicio de Cardiología, Hospital Universitario Juan Ramón Jiménez, Huelva, Spain

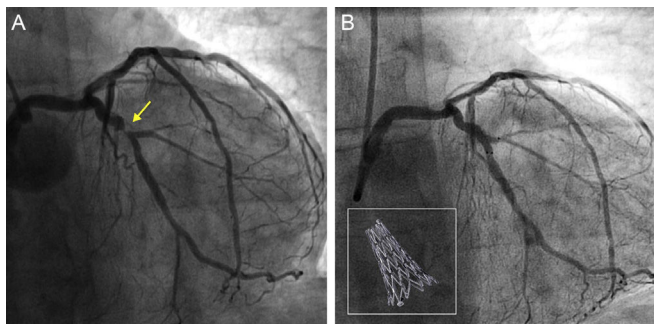


Figure 1.

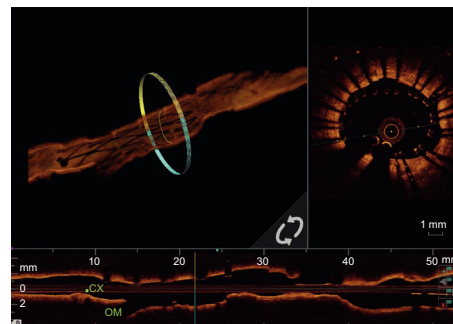


Figure 2.



Figure 3.

The patient was a 67-year-old man, with a history that included hypertension, diabetes, and dyslipidemia. He presented with a non-ST-segment elevation lateral myocardial infarction. The **Figure 1A** shows a severe bifurcation lesion (1,0,0) (arrow) in the circumflex artery, which was resolved by implantation of a specific stent for bifurcations (3.5 × 14 mm Axxess) (**Figure 1B**, box), with a good angiographic result (**Figure 1B**). Optical coherence tomography using 3-dimensional reconstruction confirmed the correct apposition of the stent in distal terms and the proper covering of the ostium of both branches, leaving the carina free of struts (**Figure 2**). Using the OPTIS Metallic Stent Optimization software package, we processed the images (**Figure 2**, **Figure 3A**, **Figure 3B**, and **Video of the supplementary material**), in which it is possible to see a discernible poor apposition at the middle level and very poor apposition at the proximal level. The struts colored in yellow represent slightly poor apposition, whereas those in red reflect considerably poor apposition (> 300 μm). Given these findings, we performed postdilatation with an unadaptable balloon, and the angiographic results were excellent, as shown by optical coherence tomography. The results after implantation were evaluated using intracoronary imaging techniques, especially when the lesions involved the bifurcation. They were very useful despite the good angiographic results. Reconstruction using the Metallic Stent Optimization system shows, in a novel, rapid and highly illustrative way, the results after the implantation.

SUPPLEMENTARY MATERIAL



Supplementary material associated with this article can be found in the online version available at [doi:10.1016/j.rec.2016.09.016](https://doi.org/10.1016/j.rec.2016.09.016).

* Corresponding author:
E-mail address: navallana@hotmail.com (S.J. Camacho Freire).
Available online 24 October 2016