

Image in cardiology

# ARCAPA Syndrome in Adulthood



## Síndrome de ARCAPA en la edad adulta

José María Arqué Gibernau,<sup>a,b</sup> Alfonso Arias Recalde,<sup>c,d</sup> and Rafael Bravo Marqués<sup>c,e,\*</sup>

<sup>a</sup> Servicio de Cirugía Cardiovascular, Hospital Parque San Antonio, Málaga, Spain

<sup>b</sup> Servicio de Cirugía Cardiovascular, Hospital Quirón, Málaga, Spain

<sup>c</sup> Servicio de Cardiología, Hospital Costa del Sol, Marbella, Málaga, Spain

<sup>d</sup> Servicio de Cardiología, Hospital Parque San Antonio, Málaga, Spain

<sup>e</sup> Servicio de Cardiología, Hospital Quirón, Málaga, Spain

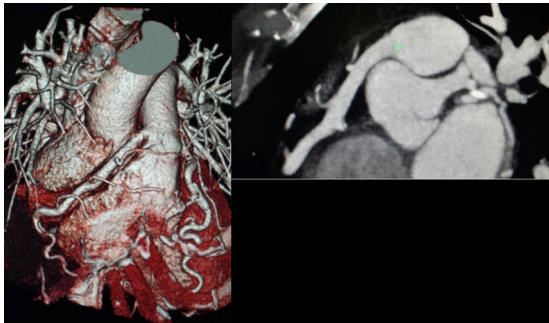


Figure 1.

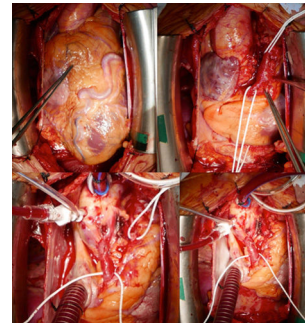


Figure 2.

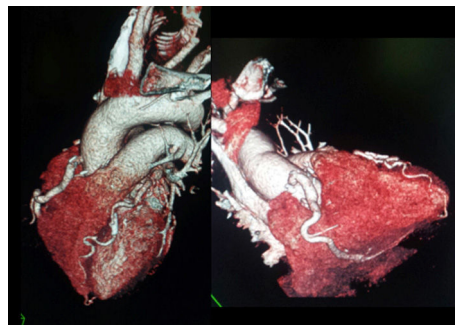

Figure 3.

The present report concerns a 52-year-old woman with hypertension as a cardiovascular risk factor. She had history of atypical chest pain that had recently manifested as chest tightness on moderate exertion. Physical examination revealed a grade II/IV systolic murmur. Transthoracic echocardiography showed a borderline dilated left ventricle (end-diastolic diameter, 52 mm) and preserved global/segmental systolic function; cardiac stress testing (Bruce protocol) was clinically positive (chest tightness) but electrically negative. Coronary computed tomography revealed a dilated right coronary artery (RCA) with an anomalous origin in the pulmonary artery (PA), with normal origin of the coronary artery and a very dilated anterior descending artery (DA) (Figure 1). The patient was diagnosed with ARCAPA syndrome (anomalous origin of the RCA from the PA) and surgical intervention was chosen. A very dilated RCA and DA were observed. The RCA was dissected close to the origin of the PA and the anomalous coronary artery was anastomosed to the aorta, resolving the left-to-right shunt (Figure 2). Follow-up computed tomography showed good subsequent development (Figure 3).

An anomalous origin of the right coronary arteries in the PA is infrequent, with an even lower incidence for the RCA (ARCAPA syndrome). This syndrome corresponds to 0.002% of all congenital heart diseases and is generally diagnosed in adulthood. It is associated with aneurysm of the coronary arteries and PA and fistulous tracts. In most patients, the treatment is surgical (reimplantation of the anomalous coronary artery in the aorta). Although the treatment required in asymptomatic patients is debated, most authors are in favor of surgical correction because patients show a progressive increase in left-to-right shunt flow and poor coronary reserve and are prone to ischemia, arrhythmias, and sudden cardiac death.

\* Corresponding author:

E-mail address: [rafabravomarques@gmail.com](mailto:rafabravomarques@gmail.com) (R. Bravo Marqués).

Available online 20 January 2017