

## ECG Contest

### ECG, July 2017

### ECG de julio de 2017



Moisés Rodríguez-Mañero,\* Javier García-Seara, and José Luis Martínez-Sande

Unidad de Arritmias, Servizo de Cardiología, Complejo Hospitalario Universitario de Santiago de Compostela (CHUS), Santiago de Compostela, A Coruña, Spain

An evaluation is requested for a patient who has episodes of atrioventricular block (AVB) in the Holter-ECG study (Figure A, Figure B, and Figure C).

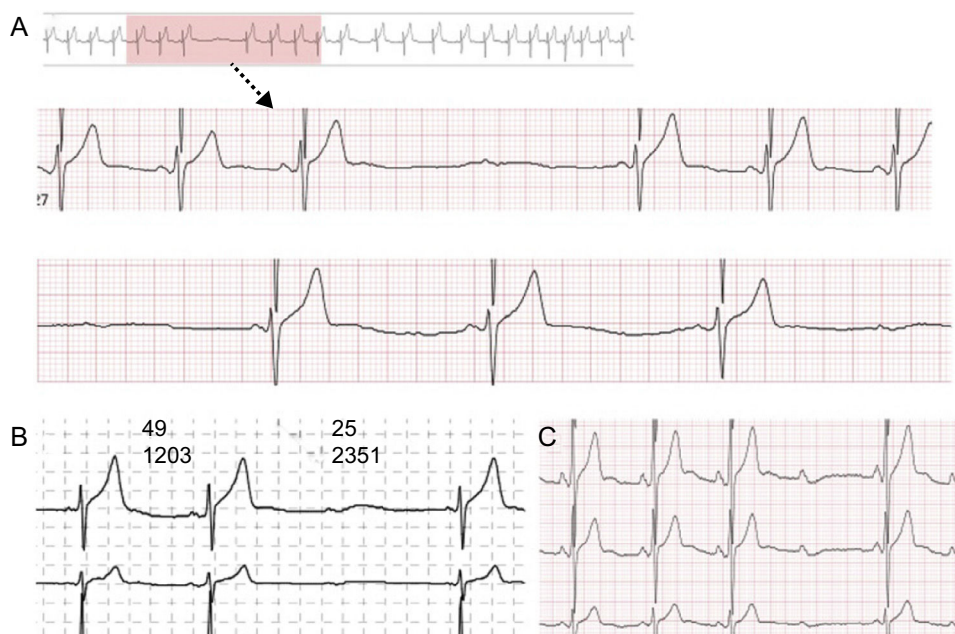


Figure.

What disorder do you think he has?

1. Mobitz II second-degree AVB
2. Bradycardia-dependent AVB
3. Vagally-mediated AVB
4. All options correspond to the same underlying disorder, and are therefore to the same approach.

Suggest a diagnosis to this ECG Contest at <http://www.revespcardiol.org/es/electroreto/70/7>. The answer will be published in the next issue (August 2017). #EKGchallenge.

\* Corresponding author:  
E-mail address: [moirmanero@gmail.com](mailto:moirmanero@gmail.com) (M. Rodríguez-Mañero).