

via 3 small incisions in the submammary sulcus. This procedure was followed by video-assisted thoracoscopy and epicardial cryoablation of the AP in the tricuspid annulus (Figure 2B and Figure 2C). AP conduction was immediately eliminated. The patient was discharged from hospital at 48 hours with good prognosis.

The typical location for APs is in the endocardium close to the atrioventricular ring. The atrial or ventricular insertion is sometimes further away from this site. Less often, the location is epicardial and exceptionally involves cardiac abnormalities such as diverticulum or right atrial appendage fistula.^{2–5}

Endocavitary catheter ablation is highly effective. Difficulties in ablation are associated with subsequent relapse. Three elements associated with difficulties in AP ablation have been described in the literature: atypical location, erroneous location of the insertion site, and technical difficulties in achieving ablation. In these situations, the combination of new electroanatomic mapping, x-ray mapping, and x-ray imaging techniques can be of immense help in correct diagnosis and treatment^{2,5,6} which, in some cases, must be surgical. The surgical treatment of AP is well established and its usefulness has been proven. However, percutaneous ablation has confined the surgical approach to complex cases with mainly epicardial location.

We can see how the diagnosis and ablation of an AP can sometimes be a complex task. Imaging techniques such as cardiac computed tomography angiography can be very useful and should probably be performed more frequently, especially after failure of the initial approach. These techniques provide anatomical data that help in detecting and predicting difficulties in ablation procedures and thus in rethinking the approach. If surgery is needed, it is important to bear in mind the minimally invasive approach as a safe and effective option with excellent esthetic results (Figure of the supplementary material).

Acknowledgments

The authors would like to thank rest of the team for their collaboration, especially Dr Basterra, Dr Martínez, and Dr Romero for their invaluable help.

SUPPLEMENTARY MATERIAL



Supplementary material associated with this article can be found in the online version available at <http://dx.doi.org/10.1016/j.rec.2017.01.020>.

Ignacio Roy,^{a,*} Virginia Álvarez,^a José-Miguel Ormaetxe,^b Jesús-Daniel Martínez-Alday,^b Ramón Pérez-Caballero,^c and Juan Miguel Gil-Jaurena^c

^aDepartamento de Cardiología, Complejo Hospitalario de Navarra, Pamplona, Navarra, Spain

^bDepartamento de Cardiología, Hospital Universitario de Basurto, Bilbao, Vizcaya, Spain

^cDepartamento de Cirugía Cardíaca Infantil, Hospital Gregorio Marañón, Madrid, Spain

*Corresponding author:

E-mail address: iroy.md@gmail.com (I. Roy).

Available online 14 February 2017

REFERENCES

1. Pérez-Caballero-Martínez R, Pita-Fernández A, González-López MT, et al. Combined ablation and exclusion of the left atrial appendage in a pediatric patient: a minimally invasive simplified approach. *Ann Thorac Surg*. 2016;101:2379–2382.
2. Campbell RM, Parks WJ, Crawford FA, et al. Right atrial diverticulum presenting as Wolff-Parkinson-White syndrome. *Pacing Clin Electrophysiol*. 1992;15:1101–1104.
3. Mah D, Miyake C, Clegg R, et al. Epicardial left atrial appendage and atrial appendage accessory pathways. *Heart Rhythm*. 2010;7:1740–1745.
4. Köse S, Başarıcı I, Kabul KH, et al. Successful percutaneous epicardial ablation of an accessory pathway located at the right atrial appendage. *Turk Kardiyol Dern Ars*. 2011;39:579–583.
5. Hocini M, Shah AJ, Cochet H, et al. Noninvasive electrocardiogram mapping facilitates previously failed ablation of right atrial appendage diverticulum associated life-threatening accessory pathway. *J Cardiovasc Electrophysiol*. 2013;24:583–585.
6. Cipoletta L, Acosta J, Mont L, et al. Posterior coronary vein as the substrate for an epicardial accessory pathway. *Indian Pacing Electrophysiol J*. 2013;13:142–147.

<http://dx.doi.org/10.1016/j.rec.2017.01.020>
1885-5857/

© 2016 Sociedad Española de Cardiología. Published by Elsevier España, S.L.U. All rights reserved.

Comparison of Bleeding Risk Scores in Patients With Nonvalvular Atrial Fibrillation Starting Direct Oral Anticoagulants



Comparación de escalas de riesgo hemorrágico en pacientes con fibrilación auricular no valvular que inician anticoagulantes orales de acción directa

To the Editor,

We have read with interest the study by Riziq-Yousef Abumuaileq et al.¹ in which they demonstrate a similar predictive capacity for the HAS-BLED, ORBIT and ATRIA scoring systems for predicting bleeding complications in patients with atrial fibrillation (AF) being treated with vitamin K antagonists. However, the study that initially validated the ORBIT scoring system² showed it to be superior to the other 2 scoring systems. Based on these seemingly discordant results, and taking into account the increasing use of direct oral anticoagulants (DOACs), with its specific characteristics in our area, we consider the validation and comparison of these scoring systems to be clinically significant in patients in our environment starting treatment with DOACs.

To this end, a retrospective study was conducted in 3 Spanish hospitals. Between January 2013 and December 2014, 973 consecutive patients with nonvalvular AF who started treatment with DOACs were included. Patients with an indication of temporary anticoagulation or different from AF and those with hypertrophic cardiomyopathy, moderate/severe rheumatic mitral stenosis, carriers of mechanical valvular prostheses or those already taking DOACs were excluded. The 3 bleeding risk scores (HAS-BLED, ATRIA and ORBIT) were calculated in 970 patients (99.7%). During the follow-up period (mean, 646 [470–839] days), bleeding complications were collected by reviewing electronic medical records and through telephone calls in 99.8% of the patients. Bleeding complications were classified according to the International Society on Thrombosis and Hemostasis criteria.^{3,4}

The population characteristics are shown in Table. A total of 505 patients (51.9%) received rivaroxaban; 188 (19.3%) received dabigatran and 280 (28.8%) received apixaban. During the follow-up period, there were 101 clinically significant bleeding episodes (6.11/100 people/y), 47 major bleeding episodes (2.76/100 people/y), 40 significant gastrointestinal bleeding episodes (2.33/100 people/y), 25 major gastrointestinal bleeding episodes

Table
Baseline Population Characteristics

Variables	All (N = 973)	Rivaroxaban (n = 505)	Dabigatran (n = 188)	Apixaban (n = 280)	P	P ^a	P ^b	P ^c
Age, y	76 ± 9	76 ± 9	74 ± 9	77 ± 8	.001	.002	.491	.001
Sex (female)	529 (54.4)	283 (56)	97 (51.6)	149 (53.2)	.522	.296	.446	.731
Hypertension	825 (84.8)	442 (87.5)	151 (80.3)	232 (82.9)	.036	.016	.072	.485
Diabetes mellitus	291 (29.9)	133 (26.3)	60 (31.9)	98 (35)	.032	.145	.011	.489
Previous stroke and/or TIA	197 (20.2)	79 (15.6)	46 (24.5)	72 (25.7)	.001	.007	.001	.761
Heart failure	164 (16.9)	79 (15.6)	30 (16)	55 (19.6)	.335	.920	.154	.311
Glomerular filtration rate < 60 mL/min/1.73 m ²	339 (34.9)	169 (33.5)	53 (28.3)	117 (41.8)	.007	.200	.020	.003
Previous VKA	377 (38.8)	179 (35.5)	85 (45.2)	113 (40.5)	.053	.019	.167	.312
Previous labile INR ^d	243 (65.0)	120 (67.4)	49 (59.0)	74 (65.5)	.414	.119	.415	.373
CHADS ₂ (points)	2.3 ± 1.3	2.2 ± 1.8	2.3 ± 1.4	2.5 ± 1.3	.003	.315	< .001	.086
CHA ₂ DS ₂ -VASC (points)	3.9 ± 1.6	3.8 ± 1.5	3.9 ± 1.8	4.2 ± 1.7	.010	.722	.002	.052
HAS-BLED (points)	1.6 ± 0.9	1.6 ± 0.9	1.6 ± 0.9	1.8 ± 0.9	.041	.909	.018	.051
ATRIA (points)	2.9 ± 1.9	2.9 ± 1.8	2.5 ± 1.7	3.1 ± 2.1	.004	.014	.148	.002
ORBIT (points)	1.7 ± 1.5	1.6 ± 1.5	1.4 ± 1.3	2.0 ± 1.7	< .001	.070	.002	< .001

INR, international normalised ratio; TIA, transient ischaemic attack; VKA, vitamin K antagonists.

Values are expressed as mean ± standard deviation and No. (%).

^a Comparison between rivaroxaban and dabigatran.

^b Comparison between rivaroxaban and apixaban.

^c Comparison between dabigatran and apixaban.

^d Data refer to patients with previous use of VKA and known INR control (n = 374).

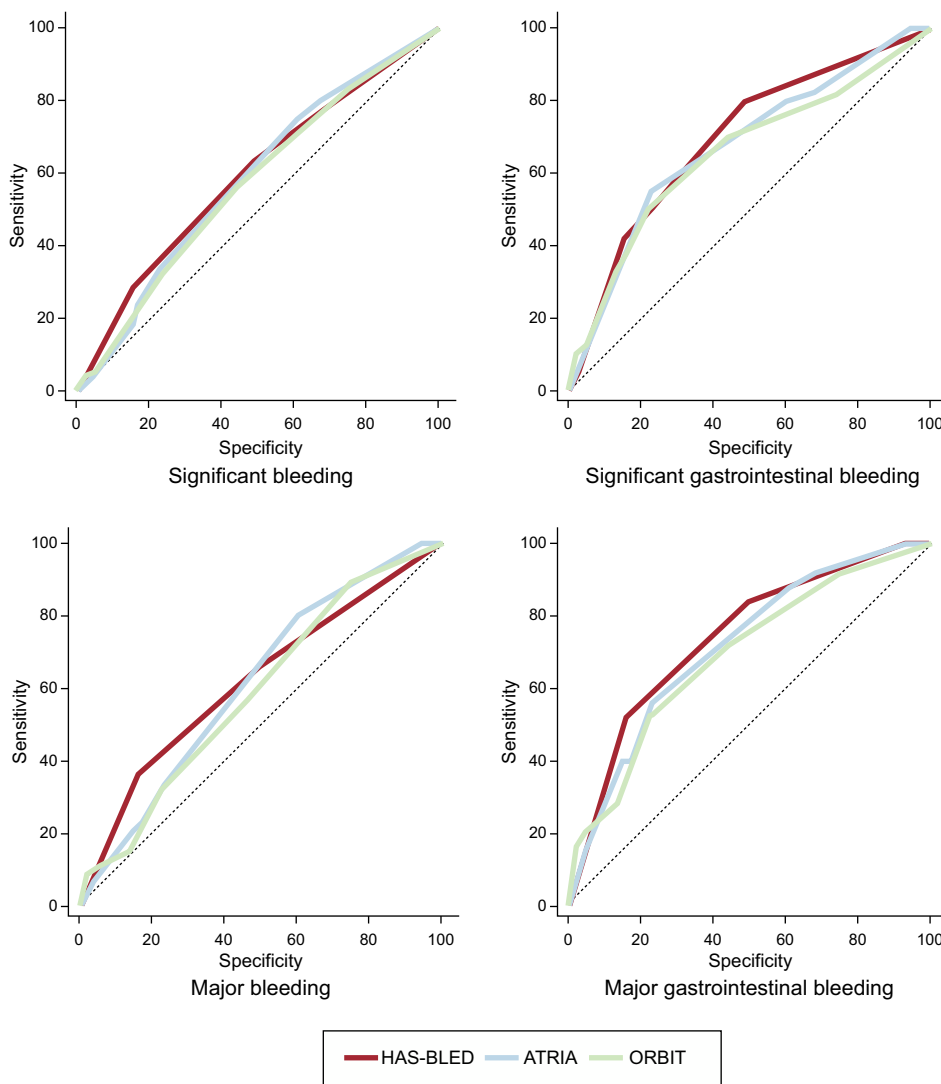


Figure. Risk scoring system discrimination according to events.

(1.46/100 people/y), 5 episodes of intracranial bleeding (0.29/100 people/y) and 102 deaths (5.85/100 people/y), 34 of which were of cardiovascular origin (1.95/100 people/y). The bleeding rate increased in line with the risk scores (Table 1, Table 2, Table 3 and Table 4 of the supplementary material). All the risk scores showed moderate discriminatory ability (Figure) for both major bleeding–HAS-BLED, 0.62 (95% confidence interval [95%CI], 0.59–0.65); ATRIA, 0.61 (95%CI, 0.58–0.64) and ORBIT, 0.59 (95%CI, 0.56–0.62)—and significant bleeding–HAS-BLED, 0.59 (95%CI, 0.56–0.62); ATRIA, 0.58 (95%CI, 0.55–0.61) and ORBIT, 0.57 (95%CI, 0.54–0.60). The discriminatory ability was somewhat higher for gastrointestinal bleeding—major gastrointestinal bleeding: HAS-BLED, 0.74 (95%CI, 0.71–0.76); ATRIA, 0.71 (95%CI, 0.68–0.74) and ORBIT, 0.69 (95%CI, 0.66–0.72); significant gastrointestinal bleeding: HAS-BLED, 0.69 (95%CI, 0.66–0.72); ATRIA, 0.67 (95%CI, 0.64–0.70) and ORBIT, 0.65 (95%CI, 0.62–0.69). Comparison of the ROC curves of the bleeding risk scoring systems showed no significant differences in any type of event in the general population or after stratification by type of DOAC (all $P > .05$) (Table 5 of the supplementary material).

The results of this study demonstrate that the 3 scoring systems assessed show moderate capacity with no significant differences in discriminating bleeding in patients with nonvalvular AF starting treatment with DOACs. Our results confirm the findings of Riziq-Yousef Abumuaileq et al.¹ and also extend their use to patients with AF being treated with DOACs. Given the increasing use of these anticoagulant agents in routine clinical practice, we consider our findings to be clinically significant. Bleeding risk scoring systems are highly useful for identifying patients with a high risk of bleeding who would probably benefit from closer monitoring. Among the different scoring systems available, the HAS-BLED scoring system has become a benchmark in routine clinical practice, as it has various advantages over other published scoring systems. Because this scoring system has been previously validated in various populations with various antithrombotic regimens, it can be applied to a wide population group. Furthermore, the presence of reversible bleeding risk factors that can be modified by clinicians allows patients' bleeding risk treatment to be considered a nonstatic process, unlike other scoring systems that do not include these potentially modifiable factors. The European Society of Cardiology recently published new clinical practice guidelines for the management of AF.⁵ Unlike previous guidelines, these do not recommend using a particular bleeding risk scoring system, but rather focus on using any of them to identify and correct potentially modifiable bleeding risk factors.

SUPPLEMENTARY MATERIAL



Supplementary material associated with this article can be found in the online version available at <http://dx.doi.org/10.1016/j.rec.2017.01.021>.

César Caro Martínez,^{a*} José Manuel Andreu Cayuelas,^b Pedro José Flores Blanco,^b Mariano Valdés,^b José Luis Bailén Lorenzo,^a and Sergio Manzano Fernández^b

^aServicio de Cardiología, Hospital Vega Baja, Orihuela, Alicante, Spain

^bServicio de Cardiología, Hospital Clínico Universitario Virgen de La Arrixaca-IMIB, El Palmar, Murcia, Spain

*Corresponding author:

E-mail address: ccaro1980@gmail.com (C. Caro Martínez).

Available online 24 February 2017

REFERENCES

- Riziq-Yousef Abumuaileq R, Abu-Assi E, Raposeiras-Roubin S, Rodríguez-Mañero M, Peña-Gil C, González-Juanatey JR. Comparison between 3 bleeding scoring systems in nonvalvular atrial fibrillation patients. What can the new ORBIT score provide? *Rev Esp Cardiol.* 2016;69:1112–1114.
- O'Brien EC, Simon DN, Thomas LE, et al. The ORBIT bleeding score: a simple bedside score to assess bleeding risk in atrial fibrillation. *Eur Heart J.* 2015;36:3258–3264.
- Schulman S, Kearon C. Subcommittee on Control of Anticoagulation of the Scientific and Standardization Committee of the International Society on Thrombosis and Haemostasis. Definition of major bleeding in clinical investigations of antihemostatic medicinal products in non-surgical patients. *J Thromb Haemost.* 2005;3:692–694.
- Kaatz S, Ahmad D, Spyropoulos AC, Schulman S. Subcommittee on Control of Anticoagulation. Definition of clinically relevant non-major bleeding in studies of anticoagulants in atrial fibrillation and venous thromboembolic disease in non-surgical patients: communication from the SSC of the ISTH. *J Thromb Haemost.* 2015;13:2119–2126.
- Kirchhof P, Benussi S, Kotecha D, et al. ESC Guidelines for the management of atrial fibrillation developed in collaboration with EACTS: The Task Force for the management of atrial fibrillation of the European Society of Cardiology (ESC). Developed with the special contribution of the European Heart Rhythm Association (EHRA) of the ESC Endorsed by the European Stroke Organisation (ESO). *Eur Heart J.* 2016. <http://dx.doi.org/10.1093/eurheartj/ehw210>.

<http://dx.doi.org/10.1016/j.rec.2017.01.021>
1885-5857/

© 2016 Sociedad Española de Cardiología. Published by Elsevier España, S.L.U. All rights reserved.

Late Coronary Obstruction After Implantation of Self-expandable Valves. Clinical and Angiographic Features of an Unexpected Complication



Obstrucción coronaria tardía tras válvulas autoexpandibles: características clínicas y angiográficas de una complicación inesperada

To the Editor,

Coronary obstruction is reported in 1% of transcatheter aortic valve implantation (TAVI) procedures, making it a dreaded complication.¹ According to a large study, the vast majority of cases (89%) become manifest during the procedure.² We report the cases of 2 patients that illustrate how coronary obstruction

can occur several hours after implantation of self-expandable valves.

The first patient was an 87-year-old woman in a delicate state of health with bronchial asthma. She was scheduled for transfemoral TAVI (Society of Thoracic Surgeons score, 6%). The echocardiographic study showed a moderately calcified valve with maximum gradient of 81 mmHg, mean gradient of 40 mmHg, and area of 0.9 cm². The aortic root was small (annulus diameter, 21 mm; sinus, 24 mm; height of the left ostium, 6 mm). After 18 mm balloon valvuloplasty with simultaneous aortography, a 26 mm CoreValve was implanted. The positioning was high but the functional result was acceptable (Figure 1 and video 1 of the supplementary material). The next day, the patient developed angina with ST depression. Aortography showed preserved coronary artery flow, and therefore it was decided to start medical treatment. Three days later, she had a more intense