

ECG Contest

Response to ECG, October 2017



Respuesta al ECG de octubre de 2017

Carlos Rubén López Perales,\* Georgina Fuertes Ferre, and Juan Carlos Porres Azpiroz

Servicio de Cardiología, Hospital Universitario Miguel Servet, Zaragoza, Spain

Conduction via an accessory pathway (option 1) can be ruled out given the absence of pre-excitation in most of the complexes (narrow QRS) and the presence of nonconducted P waves (unlikely simultaneous block of conduction system and accessory pathway).

Moreover, although extrasystoles of ventricular origin are present, the atrial cycle is maintained, and so the electrocardiogram (ECG) cannot be considered a premature atrial complex (option 2).

Option 3 is ruled out given that nonconducted atrial complexes coincide with a prior ventricular extrasystole, and so the ventricular extrasystole has to be involved in the origin of the phenomenon.

The correct solution is option 4. The ECG shows atrial rhythm of low origin with a 760 ms cycle. Twice, the ventricular extrasystole is transmitted in retrograde direction, leading to a refractory period in the atrioventricular node. This blocks conduction of the next atrial pulse (Figure).

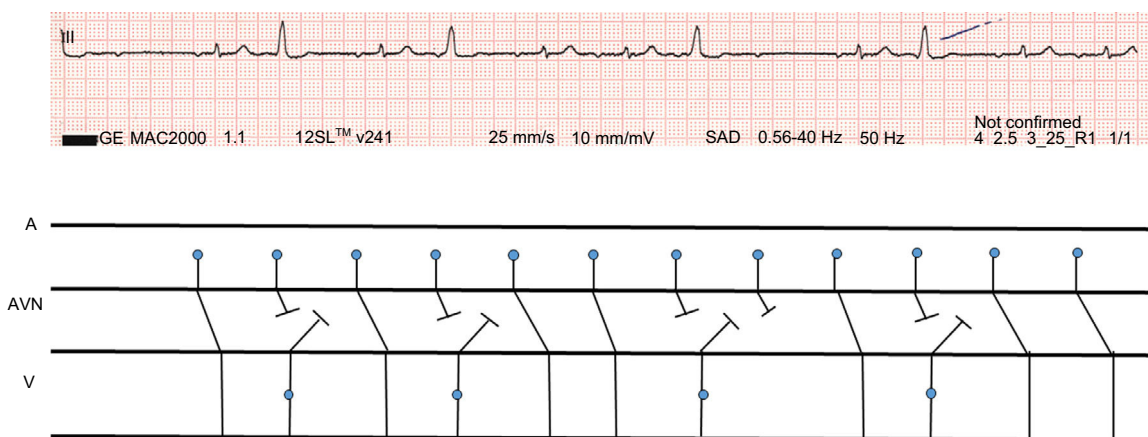


Figure. Lewis diagram showing retrograde atrioventricular conduction.

SEE RELATED CONTENT:

<http://dx.doi.org/10.1016/j.rec.2017.04.005>

\* Corresponding author:

E-mail address: [caruben89@gmail.com](mailto:caruben89@gmail.com) (C.R. López Perales).

<http://dx.doi.org/10.1016/j.rec.2017.03.017>

1885-5857/© 2017 Sociedad Española de Cardiología. Published by Elsevier España, S.L.U. All rights reserved.