

Image in cardiology

Aortic Arch in Marfan Syndrome Repaired Using the XL-stent



Reparación del arco aórtico mediante *stent* XL en Marfan

Noelia Cenizo Revuelta,* Vicente Gutiérrez Alonso, and Carlos Vaquero Puerta

Servicio de Angiología y Cirugía Vascular, Hospital Clínico Universitario de Valladolid, Valladolid, Spain

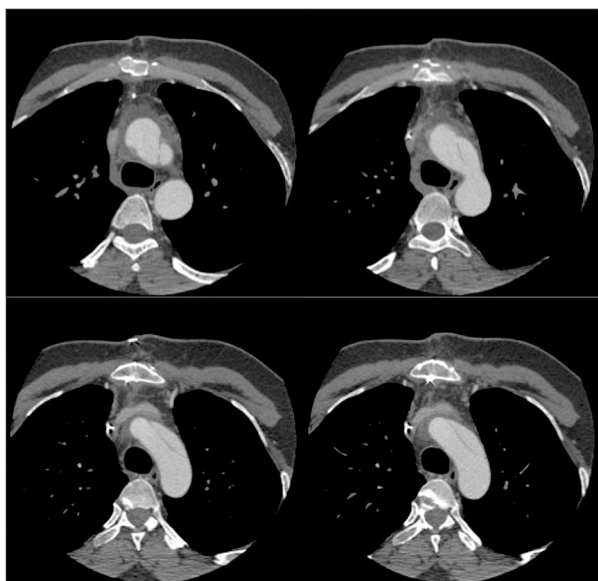


Figure 1.

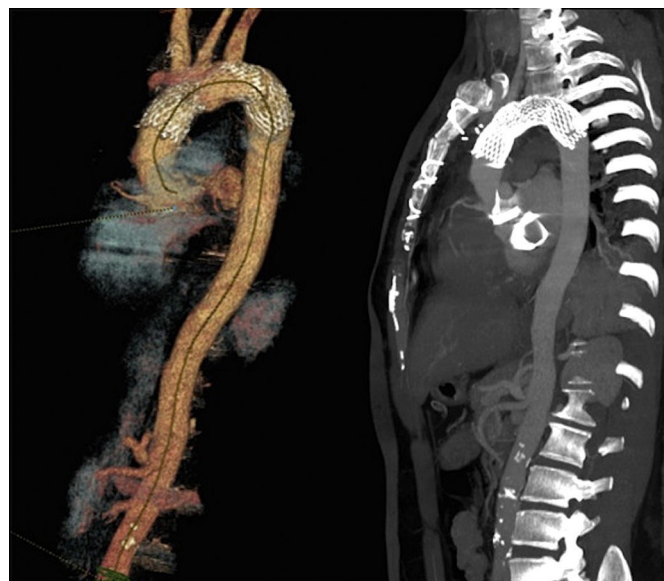

Figure 2.

The patient was a 35-year-old man with Marfan syndrome who presented with severe aortic regurgitation. Five years earlier, he had undergone elective surgery for aortic root dilation, with replacement of the ascending aorta with a Dacron tube. He now underwent a further intervention to replace the native aortic valve with a mechanical one. Immediately after the procedure, follow-up computed tomography angiography revealed the presence of type A dissection located in the aortic arch, from the origin of the brachiocephalic artery to the origin of the left subclavian artery (Figure 1). Our department was consulted to perform endovascular repair, given the history of repeat aortic surgery.

An E-XL stent (32 × 28 × 130 mm, JO TEC GmbH, Hechingen, Germany) was implanted percutaneously in the aortic arch under controlled hypotension (80 mmHg), totally covering the entry points. Intraoperative arteriography confirmed the correct positioning of the stent and the patency of the supraaortic arteries. No hypoperfusion or ischemic events were observed in the supra-aortic territory.

After 3 months, computed tomography angiography showed complete thrombosis of the false lumen (Figure 2). Given that the patient had Marfan syndrome, more extensive initial surgery (Bentall-type valve tube) could have avoided the need for subsequent intervention. Patients with this disease have a propensity for multiple aortic interventions during their lives, and we believe they should be managed in multidisciplinary units, with extensive experience and available resources, including the capacity for endovascular procedures. The off-label use of the E-XL stent reported here is a relatively noninvasive procedure that was able to resolve the problem.

* Corresponding author:

E-mail address: noecen@yahoo.es (N. Cenizo Revuelta).

Available online 25 April 2017