

Original article

Incidence and predictors of reCurrent restenosis after drug-coated balloon Angioplasty for Restenosis of a drUg-eluting Stent: The ICARUS Cooperation



Salvatore Cassese,^{a,*} Bo Xu,^b Seiji Habara,^c Harald Rittger,^d Robert A. Byrne,^a Matthias Waliszewski,^e María José Pérez-Vizcayno,^f Runlin Gao,^b Adnan Kastrati,^{a,g} and Fernando Alfonso^h

^a Klinik für Herz- und Kreislauferkrankungen, Deutsches Herzzentrum München, Technische Universität München, München, Germany

^b National Center for Cardiovascular Diseases, Fu Wai Hospital, Beijing, China

^c Department of Cardiology, Kurashiki Central Hospital, Okayama, Japan

^d Medizinische Klinik I, Klinikum Fürth, Fürth, Germany

^e Medical Scientific Affairs, B. Braun Vascular Systems, Berlin, Germany

^f Fundación Interhospitalaria de Investigación Cardiovascular, Hospital Universitario Clínico San Carlos, Madrid, Spain

^g German Centre for Cardiovascular Research (Deutsches Zentrum für Herz-Kreislauf-Forschung, DZHK), partner site Munich Heart Alliance, München, Germany

^h Servicio de Cardiología, Hospital Universitario de La Princesa, Madrid, Spain

Article history:

Received 11 April 2017

Accepted 25 July 2017

Available online 13 September 2017

Keywords:

Angiography

Coronary artery disease

Drug-coated balloon

Drug-eluting stent

Restenosis

ABSTRACT

Introduction and objectives: The incidence and predictors of recurrent restenosis after drug-coated balloon (DCB) angioplasty for drug-eluting stent (DES) restenosis remain poorly studied. We sought to evaluate the incidence and predictors of recurrent restenosis among participants in randomized controlled trials receiving DCB angioplasty for DES restenosis.

Methods: The clinical and lesion data of individuals enrolled in 6 randomized controlled trials of DCB angioplasty for DES restenosis were pooled. All patients included in this report were assigned to receive paclitaxel-coated balloon angioplasty with the SeQuent Please DCB (B Braun, Melsungen, Germany). The current analysis focused on participants with available follow-up angiography at 6 to 9 months. The incidence of recurrent restenosis, defined as diameter restenosis $\geq 50\%$ in the in-segment area at follow-up angiography, and its clinical and angiographic predictors were evaluated.

Results: A total of 546 patients were combined in a single dataset. Angiographic follow-up at 6 to 9 months was available for 484 patients (88.6%) with 518 treated lesions. Recurrent restenosis was detected in 101 (20.8%) patients. On multivariable analysis, lesion length (OR, 1.58; 95%CI, 1.10-2.26; $P = .012$ for 5 mm increase) and vessel size (OR, 1.42; 95%, 1.12-1.79; $P = .003$ for 0.5 mm reduction) were independently associated with recurrent restenosis.

Conclusions: In the largest cohort to date of individuals with angiographic surveillance after DCB angioplasty for DES restenosis, we demonstrated that recurrent restenosis occurs in approximately 1 out of 5 patients. Predictors of recurrent restenosis are increased lesion length and small vessel size.

© 2017 Sociedad Española de Cardiología. Published by Elsevier España, S.L.U. All rights reserved.

Incidencia y predictores de la reestenosis recurrente tras angioplastia con balón farmacológico en reestenosis de stents farmacológicos: proyecto cooperativo ICARUS

RESUMEN

Introducción y objetivos: No se ha estudiado bien la incidencia y los predictores de la reestenosis recurrente tras angioplastia con balón farmacológico (BFA) en reestenosis de stents farmacológicos (SFA). Nuestro objetivo es analizar la incidencia y los predictores de la reestenosis recurrente en los estudios aleatorizados en que se utilizaron BFA para el tratamiento de la reestenosis del SFA.

Métodos: Los datos clínicos y anatómicos de los pacientes incluidos en 6 estudios aleatorizados sobre BFA para el tratamiento de reestenosis de SFA se analizaron en conjunto. Se asignó a todos los pacientes incluidos en este análisis a tratamiento con el BFA de paclitaxel SeQuent Please (B Braun; Melsungen, Alemania). El análisis se centró en los pacientes que tenían seguimiento angiográfico a los 6-9 meses. Se evaluó tanto la incidencia de reestenosis (definida como estenosis $\geq 50\%$ del diámetro luminal en el análisis por segmento durante el seguimiento angiográfico tardío) como sus predictores clínicos y angiográficos.

Palabras clave:

Angiografía

Enfermedad coronaria

Balón farmacológico

Stent farmacológico

Reestenosis

SEE RELATED CONTENT:

<https://doi.org/10.1016/j.rec.2018.01.013>

* Corresponding author: Deutsches Herzzentrum München, Technische Universität München, Lazarettstrasse 36, 80636 München, Germany.

E-mail address: cassese@dhm.mhn.de (S. Cassese).

<http://dx.doi.org/10.1016/j.rec.2017.08.005>

1885-5857/© 2017 Sociedad Española de Cardiología. Published by Elsevier España, S.L.U. All rights reserved.

Resultados: Los datos de 546 pacientes se incluyeron en una única base de datos. De 484 pacientes (88,6%), con un total de 518 lesiones tratadas, se disponía de seguimiento angiográfico tardío, y se detectó recurrencia de reestenosis en 101 pacientes (20,8%). En el análisis multivariable, la longitud de la lesión (por cada incremento de 5 mm, OR = 1,58; IC95%, 1,10-2,26; $p = 0,012$) y el tamaño del vaso (por cada reducción de 0,5 mm, OR = 1,42; IC95%, 1,12-1,79; $p = 0,003$) se asociaron de manera independiente con la recurrencia de reestenosis.

Conclusiones: Este estudio, el mayor disponible de pacientes tratados con BFA por reestenosis de SFA con seguimiento angiográfico tardío, demuestra que la recurrencia de reestenosis se produce en 1 de cada 5 de estos pacientes. Los predictores de la reestenosis recurrente son la longitud de la lesión y el tamaño del vaso.

© 2017 Sociedad Española de Cardiología. Publicado por Elsevier España, S.L.U. Todos los derechos reservados.

Abbreviations

DCB: drug-coated balloon

DES: drug-eluting stent

INTRODUCTION

Contemporary drug-eluting stents (DES) have markedly reduced the need for reintervention compared with both bare metal stents and early-generation DES. However, the occurrence of restenosis due to neointimal proliferation and/or neoatherosclerosis within stented segments is still the main reason for DES failure.¹ Moreover, the optimal treatment of DES restenosis remains a matter of debate and continues to be associated with high rates of recurrent restenosis.²

In patients with DES restenosis, European guidelines recommend treatment with either drug-coated balloon (DCB) or repeat stenting with DES; recommendations for both options are supported by a similar level of evidence.³ Drug-coated balloon represents an attractive treatment option, providing antiproliferative efficacy without the requirement for an additional stent implant.⁴ Although recent studies of patients with DES restenosis ranked the antirestenotic potency of DCB as the second most effective treatment after repeat stenting with everolimus-eluting stents,⁵ this treatment might be the preferred option for patients due to concerns about the late outcomes of patients treated with multiple stent layers.⁶

Follow-up angiography is the modality of choice for the detection of lumen renarrowing after coronary intervention and for assessment of device efficacy.⁷ To date, however, investigations of the incidence and predictors of recurrent restenosis after DCB angioplasty for DES restenosis remain scarce. Moreover, the identification of clinical, angiographic and procedural risk factors predicting the risk of recurrent restenosis at follow-up angiography may provide a basis for treatment optimization or individualization of revascularization strategies in specific patient and lesion subsets. In this report, we evaluated the incidence and predictors of recurrent restenosis in a cohort of patients treated with DCB angioplasty for DES restenosis in the setting of randomized controlled trials.

METHODS

Data Sources and Eligibility Criteria

For inclusion in the current analysis, randomized trials of DCB therapy for patients with stable or unstable coronary artery disease because of DES restenosis were identified by searching Medline, EMBASE, the Cochrane Central Register of Controlled Trials (CENTRAL), the abstracts of scientific sessions, and relevant websites. No restrictions in terms of language or publication status

were imposed. The reference lists from all eligible studies and previous meta-analyses on this topic^{5,8} were checked to identify further citations. Search terms included the keywords and the corresponding Medical Subject Headings for “drug-coated (-eluting) balloon”, “paclitaxel-coated (-eluting) balloon”, “drug-eluting stent(s)”, “restenosis”, “trial”, and “randomized trial”. Inclusion criteria consisted of randomized design and the availability of follow-up angiography data 6 to 9 months after the index procedure. Investigations of DCB angioplasty for indications other than DES restenosis were ineligible. The last search was performed on June 22, 2016.

Collection of Individual Participant Data and Quality Assessment

Two investigators (S. Cassese and R.A. Byrne) independently assessed publications for eligibility at the title and/or abstract level. Divergences were resolved by consensus. Studies that met the inclusion criteria were selected for further analysis. Freedom from bias was evaluated for each study in accordance with The Cochrane Collaboration method.⁹ Composite quality scores were not assigned.¹⁰

Of 8 studies identified through the electronic search, 2 randomized trials¹¹ were excluded since the overall percentage of patients receiving DCB angioplasty because of DES restenosis was < 5%. Finally, 6 randomized trials^{12–17} were available for inclusion in the present analysis. The principal investigators of these studies were contacted to provide individual data of participants randomly assigned to DCB angioplasty. Data was transferred without patient identifiers to the ISAResearch Center (Deutsches Herzzentrum München, Technische Universität München, Munich, Germany) and combined in a single pooled database. The final dataset was checked for completeness and consistency and compared with the results of prior publications. Principal investigators were directly contacted in case of requirement for additional data. Data were analyzed according to the intention-to-treat principle. Each study included in the present analysis was approved by the institutional review board or ethics committee at each participating center, and all patients provided informed, written consent before receiving the assigned treatment.

Angiographic Data and Study Definitions

At baseline, procedural parameters were gathered and follow-up coronary angiograms were digitally recorded and assessed off-line with automated edge-detection systems by independent operators in all studies.^{12–17} Lesion characteristics were described in accordance with standard definitions, while restenosis morphology was classified according to criteria modified from Mehran et al.¹⁸

The angiographic and procedural parameters collected for the current analysis were vessel size, lesion length, initial diameter stenosis, maximal balloon pressure, final lumen diameter, and final

diameter stenosis. The balloon-to-vessel ratio was calculated with the maximal diameter of the inflated balloon divided by the coronary vessel size. The percentage of diameter stenosis was calculated as $([1 - \text{minimal lumen diameter}/\text{reference vessel diameter}] \times 100)$. Restenosis (angiographic or binary), the main outcome of interest in this report, was defined as diameter stenosis $\geq 50\%$ in the in-segment area (defined as the balloon-treated area and 5-mm segments proximal and distal to the treated area).

Data Synthesis and Statistical Analysis

Categorical data are presented as counts and proportions (percent). Continuous data are presented as median and interquartile range [25th to 75th percentiles] or as mean \pm standard deviation, as appropriate. The data distribution was tested for normality using the Kolmogorov-Smirnov test. For patient-level data, the differences between groups were checked for significance using the Student *t* or Kruskal-Wallis tests (continuous data) or the chi-squared or Fisher exact tests where the expected cell value was < 5 (categorical variables). For lesion-level data, the differences between groups were checked for statistical significance using generalized estimating equations (R-package *gee*) to address the intrapatient correlation in patients with multilesion interventions. Depending on the nature of the dependent variable, we used the Gaussian or the binomial family for continuous and discrete variables, respectively. We employed the exchangeable link function. The predictors of recurrent restenosis were studied by means of a multivariable analysis. Missing baseline data were imputed by using the predictive mean matching function (R-package *mice*) and the selection of variables for the multivariable model was performed by the use of the LASSO (Least Absolute Shrinkage and Selection Operator) regression method after entering all baseline and procedural characteristics as candidates (R-package *glmnet*). Finally, a logistic regression model stratified by trial was applied for recurrent restenosis after entering also a cluster term to account for the presence of multiple treated lesions in the same patient. The adjusted odds ratios (ORs) with 95% confidence intervals (95%CI) were used as summary statistics. A *P*-value of $< .05$ was considered significant. All analyses were performed in R (version 3.3.2, R Foundation for Statistical Computing, Vienna, Austria). This study was reported in compliance with the Preferred Reporting Items for a Systematic Review and Meta-analysis of Individual Participant Data (Table 1 of the [supplementary material](#)).¹⁹

RESULTS

Figure 1 shows the flow diagram for the trial selection process, while Table 1 displays the main features of selected studies. Briefly, patients with clinical or instrumental evidence of stable or unstable coronary artery disease and $\geq 50\%$ diameter stenosis in a previous DES-treated segment were included in 6 randomized trials.^{12–17} Drug-coated balloon therapy consisted of a balloon angioplasty with the SeQuent Please catheter (B Braun, Melsungen, Germany). The coating of the DCB under investigation comprises of the antirestenotic drug paclitaxel at a dose of 3 μg for mm^2 of balloon surface and contrast medium (iopromide) as drug-vehicle. The control therapy was conventional balloon angioplasty^{12–15} or repeat stenting with DES.^{15–17} In all trials except one¹⁴ the primary endpoint consisted of angiographic measures of efficacy after 6 to 9 months. Of note, the participants of the trial with a clinical primary endpoint accounted for 9.7% of the entire cohort available for this report. Aspirin at the time of the index intervention and a loading dose of platelet adenosine-diphosphate receptor inhibitors were administered in all patients. Anticoagulation during coronary

interventions was accomplished through administration of either unfractionated heparin or bivalirudin. At discharge, aspirin therapy was recommended indefinitely for all participants, while platelet adenosine-diphosphate receptor inhibitors were prescribed for a period of time ranging from 3 to 12 months, depending on clinical presentation or protocol-specific requirements. The evaluation of risk of bias among studies is reported in Table 2 of the [supplementary material](#).

Among selected trials,^{12–17} 546 individuals with 588 lesions were assigned to DCB therapy because of DES restenosis. Table 3 of the [supplementary material](#) displays the main features of patients randomly assigned to DCB angioplasty in each individual trial. Among participants, a total of 484 individuals (88.6%) with 518 treated lesions had angiographic surveillance available at a median of 202 days (range, 180–275) after the index procedure. At this time point, recurrent restenosis was observed in 101 patients (20.8%) with 103 treated lesions. The study flow diagram is displayed in the Figure of the [supplementary material](#).

A total of 62 patients did not undergo follow-up angiography: these patients were slightly older (age 62.2 [58.0–68.0] vs 59.0 [52.1–67.5] years; *P* = .09), were more likely to have a diagnosis of diabetes (58.1% vs 43.0%; *P* = .02), and had similar rates of previous myocardial infarction (43.5% vs 46.9%; *P* = .62) in comparison to patients with follow-up angiography. Four out of 62 patients died before the scheduled angiography.

Univariable Analysis

The baseline clinical characteristics of patients with and without recurrent restenosis at follow-up angiography are shown in Table 2. The proportions of individuals with diabetes mellitus and with a history of myocardial infarction approached 50% and were comparable between groups. In both groups, most patients complained of stable angina at the time of the index intervention. Multivessel coronary artery disease was more likely to be present in patients with recurrent stenosis than in those without.

Baseline angiographic and procedural characteristics of lesions with and without recurrent restenosis are shown in Table 3. Treatment of chronic occlusions, long lesions, small vessels and higher-degree of baseline stenosis was more likely in patients with recurrent stenosis than in those without. There was a numerically higher proportion of diffuse-pattern restenosis in those lesions showing recurrent restenosis at follow-up angiography than in those that did not. Notably in both groups, more than 4 out of 5 of restenotic stents eluted sirolimus or its analogs.

Multivariable Analysis

Figure 2 shows the plot of ORs for the variables entered in the final model. The presence of longer lesion length (OR, 1.58; 95%CI, 1.10–2.26; *P* = .012 for 5 mm increase) and smaller vessel size (OR, 1.42; 95%CI, 1.12–1.79; *P* = .003 for 0.5 mm reduction) were independently associated with a higher likelihood of recurrent restenosis

DISCUSSION

In the current analysis, we investigated the incidence and predictors of recurrent restenosis at surveillance angiography in 546 individuals treated with DCB angioplasty for DES restenosis across 6 randomized trials. The dataset analyzed represents the largest population with follow-up angiography after DCB angioplasty for DES restenosis studied so far. The main findings are the following: a) recurrent restenosis after DCB angioplasty for DES

Table 1
Main Features of Trials Selected for Inclusion in the Study

Trial	Enrollment period	Patients included, no.	Design	Main inclusion criteria	Main exclusion criteria	Primary endpoint
Habara et al. ¹²	2008–2009	50	Single-center, single-blind, RCT of DCB vs POBA (1:1 ratio) for DES restenosis	<ul style="list-style-type: none"> • Age \geq 18 y • Stable CAD • First DES restenosis (SES restenosis) • RVD \geq 2.5 and \leq 3.5 mm • Lesion length $<$ 26 mm 	<ul style="list-style-type: none"> • ACS • Severe CKD • Prior stenting $<$ 6 mo • DES restenosis involving uLMCA, ostial lesion • Bifurcation lesion • CTO 	6 mo LLL
Habara et al. ¹⁴	2009–2011	210	Multicenter, open-label, RCT of DCB vs POBA (2:1 ratio) for DES or BMS restenosis	<ul style="list-style-type: none"> • Age $>$ 20 y • Stable or unstable CAD • Single BMS or DES restenosis (EES, SES, ZES restenosis) lesion or \leq 2 restenotic lesions in different vessels • RVD \geq 2.0 and \leq 4.0 mm • Lesion length \leq 22 mm 	<ul style="list-style-type: none"> • $<$ 30% LVEF • AMI $<$ 72 h • CKD • Any PCI $<$ 28 d • PCI with DES $<$ 6 mo • Any CVA $<$ 6 mo • Antiplatelet, anticoagulant, paclitaxel or contrast media intolerance • Pregnancy or childbearing potential • Severe illnesses with $<$ 12 mo life expectancy • $>$ 50% uLMCA diameter stenosis • Tortuous ($>$ 90° angle) lesion • Multiple lesions in the target vessel • CTO, heavily calcified lesion, DES restenosis involving bypass graft or bifurcation with $>$ 2.0 mm RVD of side branch 	6 mo TVF (cardiac death related to the target vessel, MI and TVR)
ISAR-DESIRE 3 ¹⁵	2009–2011	402	Multicenter, open-label, RCT of DCB vs PES vs POBA (1:1:1 ratio) for DES restenosis	<ul style="list-style-type: none"> • Age $>$ 18 y • Stable or unstable CAD • $>$ 50% diameter DES restenosis (BES, EES, SES, ZES restenosis) 	<ul style="list-style-type: none"> • STEMI $<$ 48 h • Cardiogenic shock • Severe CKD • Severe illnesses with $<$ 12 mo life expectancy or that might result in protocol noncompliance • Contraindications or known allergy to antiplatelet therapy or paclitaxel, pregnancy or childbearing potential • DES restenosis involving uLMCA or bypass graft 	6–8 mo diameter stenosis
PEPCAD China ISR ¹⁶	2011–2012	220	Single-center, single-blind, RCT of DCB vs PES (1:1 ratio) for DES restenosis	<ul style="list-style-type: none"> • Age \geq 18 to \leq 80 y • Stable or unstable CAD • $>$ 50% and \leq 70% diameter DES restenosis (EES, SES, PES restenosis) • ISR Mehran class I–III • RVD \geq 2.5 and \leq 4.0 mm • Lesion length \leq 30 mm 	<ul style="list-style-type: none"> • AMI $<$ 1 wk • Heart failure NYHA class IV • Severe valvular heart disease • CVA $<$ 6 mo • Severe CKD • DES restenosis involving bifurcation with $>$ 2.5 mm RVD of side branch • Thrombus in the target vessel 	9 mo LLL
PEPCAD DES ¹³	2009–2011	110	Multicenter, single-blind, RCT of DCB vs POBA (2:1 ratio) for DES restenosis	<ul style="list-style-type: none"> • DES restenosis (EES, SES, PES restenosis) • RVD \geq 2.5 and \leq 3.5 mm • Lesion length $<$ 22 mm 	<ul style="list-style-type: none"> • Planned surgery within 6 mo • Contraindication to antiplatelet therapy • Thrombus in the target vessel • DES restenosis involving uLMCA or bypass graft • Bifurcation lesion • Ostial lesion • Multiple lesions in the target vessel • CTO 	6 mo LLL
RIBS IV ¹⁷	2010–2013	309	Multicenter, open-label, RCT of DCB vs EES (1:1 ratio) for DES restenosis	<ul style="list-style-type: none"> • Stable or unstable CAD • $>$ 50% diameter DES restenosis • RVD $>$ 2.0 mm • Lesion length \leq 30 mm 	<ul style="list-style-type: none"> • CTO • $<$ 1 mo DES restenosis • AMI • Thrombus in the target vessel • Severe peripheral vascular disease • Severe illnesses with $<$ 12-mo life expectancy or that might result in protocol noncompliance • Contraindications to antiplatelet therapy 	6–9 mo MLD

ACS, acute coronary syndrome; AMI, acute myocardial infarction; BES, biolimus-eluting stent; BMS, bare metal stent; CAD, coronary artery disease; CKD, chronic kidney disease; CTO, chronic total occlusion; CVA, cerebrovascular accident; DCB, drug-coated balloon; DES, drug-eluting stent; EES, everolimus-eluting stent; ISAR-DESIRE 3, Randomized Trial of Paclitaxel-Eluting Balloon, Paclitaxel-Eluting Stent and Plain Balloon Angioplasty for Restenosis in “Limus”-Eluting Coronary Stents; ISR, in-stent restenosis; LLL, late lumen loss; LVEF, left ventricular ejection fraction; MI, myocardial infarction; MLD, minimal lumen diameter; NYHA, New York Heart Association; PCI, percutaneous coronary intervention; PEPCAD China ISR, A Multicenter, Randomized, Active Controlled Clinical Study to Evaluate the Safety and Efficacy of the Treatment of In-stent Restenosis Lesion by Paclitaxel-eluting PTCA-Balloon Catheter vs Paclitaxel-eluting Stent; PEPCAD DES, Treatment of DES-In-Stent Restenosis With Sequent Please Paclitaxel Eluting PTCA Catheter; PES, paclitaxel-eluting stent; POBA, plain old balloon angioplasty; RCT, randomized controlled trial; RIBS IV, Restenosis Intrastent of Drug-eluting Stents: Paclitaxel-eluting Balloon vs Everolimus-eluting Stent). A Prospective, Multicenter and Randomized Clinical Trial; RVD, reference vessel diameter; SES, sirolimus-eluting stent; STEMI, ST-segment elevation myocardial infarction; TVF, target vessel failure; TVR, target vessel revascularization; uLMCA, unprotected left main coronary artery; ZES, zotarolimus-eluting stent.

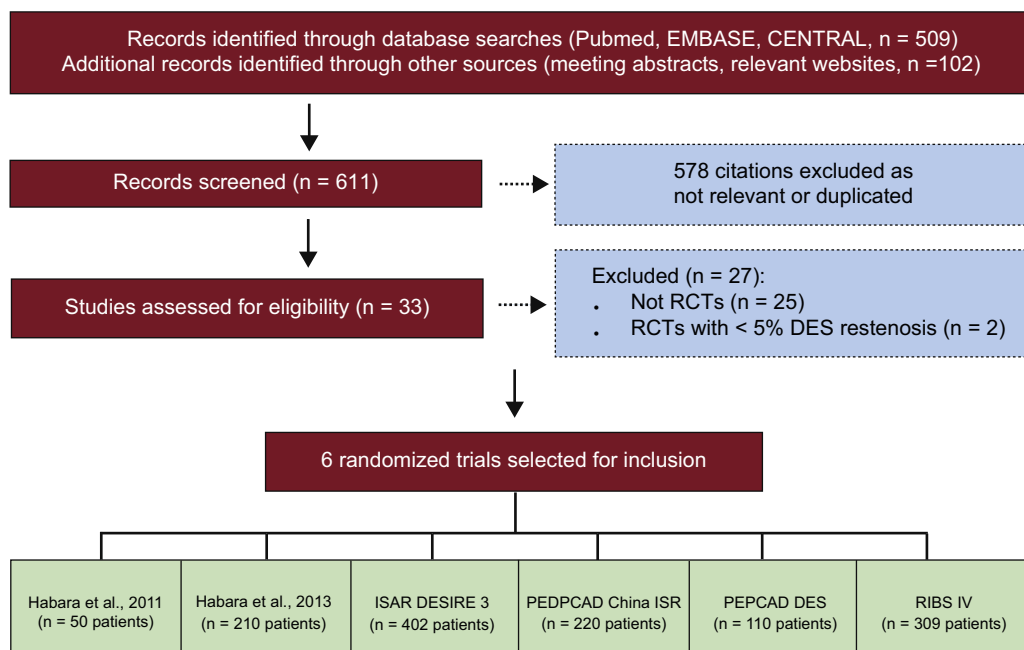


Figure 1. Flow diagram of trial selection process. CENTRAL, Cochrane Central Register of Controlled Trials; ISAR-DESIRE 3, Randomized Trial of Paclitaxel-Eluting Balloon, Paclitaxel-Eluting Stent and Plain Balloon Angioplasty for Restenosis in “-Limus”-Eluting Coronary Stents; PEPCAD China ISR, A Multicenter, Randomized, Active Controlled Clinical Study to Evaluate the Safety and Efficacy of the Treatment of In-stent Restenosis Lesion by Paclitaxel-eluting PTCA-Balloon Catheter vs Paclitaxel-eluting Stent; PEPCAD DES, Treatment of DES-In-Stent Restenosis With SeQuent Please Paclitaxel Eluting PTCA Catheter; RCT, randomized controlled trial; RIBS IV, Restenosis Intrastent of Drug-eluting Stents: Paclitaxel-eluting Balloon vs Everolimus-eluting Stent). A Prospective, Multicenter and Randomized Clinical Trial.

Table 2
Baseline Clinical Features of Patients With Available Follow-up Angiography After Drug-coated Balloon Angioplasty for Drug-eluting Stent Restenosis

Characteristics	Recurrent restenosis		P
	Yes (n = 101)	No (n = 383)	
Age, y	68.4 [61.0-75.0]	67.0 [59.0-74.2]	.76
Male sex	80 (79.2)	309 (80.7)	.74
Diabetes mellitus	48 (47.5)	160 (41.8)	.30
Insulin-treated ^a	17 (18.7)	55 (16.5)	.62
Smoking	23 (22.8)	99 (25.8)	.53
Hypertension	76 (75.2)	299 (78.1)	.55
Dyslipidemia	71 (70.3)	265 (69.2)	.83
History of myocardial infarction	47 (46.5)	180 (47.0)	.93
History of bypass surgery	6 (6.0)	28 (7.3)	.63
Clinical presentation			
Stable angina	61 (60.4)	240 (62.6)	.67
NSTEMI/ACS	20 (19.8)	68 (17.7)	.63
Multivessel CAD	71 (70.3)	211 (55.2)	.006
Left ventricular ejection fraction, % ^b	60 [52-65]	60 [52-65]	.76

CAD, coronary artery disease; NSTEMI/ACS, non-ST-segment elevation acute coronary syndrome.

Data are presented as median [25th-75th percentiles] or counts (proportion) of patients.

^a Data available for 425 of 484 (88.0%) patients.

^b Data available for 324 of 484 (67.0%) patients.

restenosis occurs in approximately 1 out of 5 patients; b) the presence of longer lesion length and smaller vessel size are predictors of recurrent restenosis.

The continuous iteration of DES therapy has expanded the indications of percutaneous interventions to increasingly complex patient and lesion populations.¹ Accordingly, as rates of stent failure may be considered a function of disease complexity,²⁰ the

Table 3
Angiographic and Procedural Features of Patients With Available Follow-up Angiography After Drug-coated Balloon Angioplasty for Drug-eluting Stent restenosis

Characteristic	Recurrent restenosis		P
	Yes (n = 103)	No (n = 415)	
Target vessel			
Left main coronary artery	1 (1.0)	—	—
Left anterior descending coronary artery	36 (35.0)	179 (43.2)	.13
Left circumflex coronary artery	30 (29.0)	95 (22.9)	.19
Right coronary artery	36 (35.0)	133 (32.1)	.57
Bypass graft	—	7 (1.8)	—
Chronic occlusion	5 (4.9)	6 (1.5)	.04
Bifurcation	25 (24.3)	79 (19.0)	.22
Ostial	13/78 (16.7)	40/306 (13.1)	.40
Restenosis morphology			.07
Focal	61 (59.2)	285 (68.7)	
Diffuse	42 (40.8)	130 (31.3)	
Index DES type			.29
Limus-eluting	91 (88.3)	352 (84.8)	
Paclitaxel-eluting	10 (9.7)	45 (10.8)	
Unknown ^c	2 (2.0)	18 (4.4)	
Lesion length, mm	12.6 ± 7.7	10.6 ± 5.8 (414)	.004
Vessel size, mm	2.51 ± 0.52	2.63 ± 0.50 (413)	.03
Initial diameter stenosis, %	70.7 ± 15.5	66.5 ± 14.6 (413)	.02
Predilatation	96 (93.2)	394 (94.9)	.52
Maximal balloon pressure, atm	14.8 ± 4.3	14.5 ± 4.5 (406)	.43
Balloon-to-vessel ratio	1.20 ± 0.31	1.18 ± 0.26 (406)	.40
Final diameter stenosis, %	17.5 ± 9.9	17.2 ± 8.8 (412)	.75

DES, drug-eluting stent.

Data are presented mean ± standard deviation or counts (proportion) of lesions. Denominators have been provided when they differ from the total number of lesions.

^c DES confirmed, but the precise type of DES was unknown.

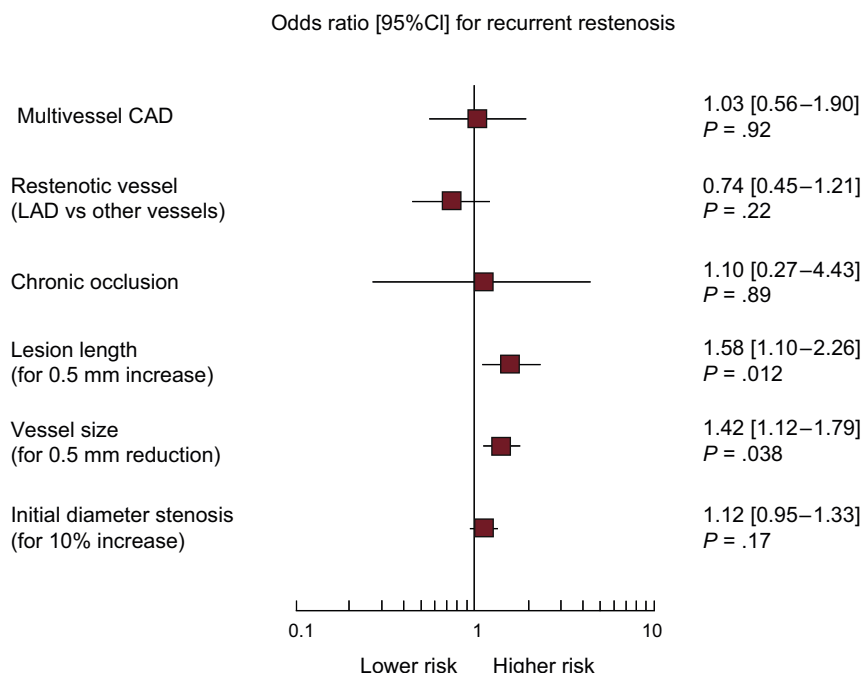


Figure 2. Multivariable analysis for recurrent restenosis in patients treated with drug-coated balloon angioplasty for drug-eluting stent restenosis. Plot of odds ratios associated with recurrent restenosis stratified by trial. The squares indicate the point estimate and the left and the right ends of the lines the [95%CI]. 95%CI, 95% confidence interval; CAD, coronary artery disease; LAD, left anterior descending coronary artery.

absolute number of patients presenting with DES restenosis remains considerable in absolute terms and is expected to increase in the years to come. Since DCB angioplasty is among the most effective options for patients with DES restenosis,⁵ investigations of recurrent restenosis in this setting represent an important undertaking.

The present report investigated the largest dataset of participants randomly assigned to receive DCB angioplasty for DES restenosis across controlled clinical trials. Notably, baseline features were comparable to those of individuals with DES restenosis receiving DCB therapy in daily practice.^{21,22} We found that recurrent binary angiographic restenosis occurs in nearly 21% of patients. These results are broadly consistent with those from individual clinical trials and support DCB as the second most efficacious treatment for DES restenosis after repeat everolimus-eluting stent implantation, which has been associated with an incidence of recurrent restenosis as high as 11.3%.²³

In this analysis, long lesions were strong predictors of recurrent restenosis after DCB angioplasty for DES restenosis. In particular, we found a 58% higher risk of recurrence for each increase in lesion length by 5 mm. Proper contact with the underlying restenotic tissue of sufficient drug concentrations is a prerequisite for the efficacy of DCB therapy.⁴ In this respect, a higher displacement of drug particles from balloon catheters into the bloodstream during delivery of the balloon in long restenotic segments may contribute to a reduced DCB efficacy in this setting.²⁴ In addition, other factors associated with poor outcomes, such as stent underexpansion, are more frequent with long-segment stenting²⁵ and likely impair an effective drug transfer to the vessel wall.

Small-caliber coronary arteries remain the factor most closely correlated with restenosis regardless of the type of percutaneous treatment.²⁶ Intuitively, at an individual patient level, for any given degree of neointimal overgrowth after intervention the probability that the resultant diameter stenosis exceeds 50% is a function of vessel size and residual after procedural stenosis. Here, we report a 42% higher risk of recurrent restenosis for each 0.5 mm decrease in reference vessel diameter. On the one hand, DCB represents an attractive treatment option among patients with DES restenosis of

small coronary vessels, by implementing an antiproliferative therapy by means of a nonstent-based platform, thus avoiding a mechanical shrinkage of the vessel lumen due to an additional metal layer. On the other hand, the superior antirestenotic efficacy of alternative treatments, namely contemporary high-performance stent platforms such as everolimus-eluting stents, may be of particular relevance for patients with DES restenosis of small coronary vessels.²⁶

It is interesting to note that in our analysis the type of underlying DES did not emerge as an independent predictor of recurrent restenosis after DCB angioplasty for DES restenosis. Although this observation was based on a limited number of patients, it is in keeping with data from previous studies.²⁷ Current commercially available DCB catheters use exclusively the taxol-derivative paclitaxel as antirestenotic drug.⁴ Although the influence of drug-resistance on DCB efficacy in patients with DES restenosis is of scientific interest, paclitaxel-eluting stents are no longer used in daily practice and limus-based DCB catheters are still in the development phase.²⁸ In this regard, it remains to be addressed whether the continuous development of new DCB catheters (paclitaxel- and limus-based), the synergy of different technologies (cutting/scoring balloon catheters for predilation before DCB angioplasty), and a more liberal use of intravascular imaging to optimize lesion preparation will decrease the risk of recurrence after DCB angioplasty for DES restenosis.

Limitations

The current analysis has some limitations. First, it applies only to patients with DES restenosis and the incidence and predictors of recurrence after DCB angioplasty for restenosis of bare metal stents cannot be extrapolated from this study. Second, the rate of recurrent restenosis after DCB angioplasty for DES restenosis at a time point other than 6 to 9 months remains poorly studied and the predictors identified in this report may not apply to patients with recurrent restenosis at a different time point. Third, adjudication of restenosis was based on the percentage diameter of lumen

renarrowing at follow-up angiography. The association between further lesion-specific factors (such as restenotic tissue characterization) on subsequent angiographic results was not assessed. Fourth, it should be noted that this study pooled well-selected patients and lesions. In this respect, the recurrence rate observed in the present analysis should be interpreted with caution and is not generalizable to higher-risk subsets of patients. Fifth, the original trials included in this report did not routinely assess ischemic burden in patients with recurrent restenosis at 6 to 9 months; in this regard, the clinical relevance of angiographic findings cannot be assessed in this context. Finally, all patients included in this report received DCB angioplasty with a single balloon catheter. Although this aspect eliminates an important source of variability, the available evidence does not support a class effect for DCB platforms.⁴ In this respect, the angiographic data observed in this analysis should not be extrapolated to other DCB devices.

CONCLUSIONS

In the largest cohort of patients with angiographic surveillance after DCB angioplasty for DES restenosis, recurrence was found in approximately 1 out of 5 patients. Independent predictors of recurrent restenosis were increased lesion length and small vessel size.

CONFLICTS OF INTEREST

A. Kastrati reports patent applications related to drug-eluting stent technologies. R.A. Byrne reports receiving lecture fees from B. Braun Melsungen AG, Biotronik and Boston Scientific and scientific support from Boston Scientific and Heartflow. M. Waliszewski is a full-time employee of the Medical Scientific Affairs Department of B. Braun Melsungen AG.

WHAT IS KNOWN ABOUT THE TOPIC?

- The occurrence of restenosis within stented segments still represents the principal reason of failure after contemporary DES therapy.
- Drug-coated balloon is an attractive therapeutic option by providing antiproliferative efficacy without requirement for an additional stent.
- Nevertheless, the treatment of DES restenosis continues to be associated with high recurrence rates.

WHAT DOES THIS STUDY ADD?

- In this pooled analysis of individual participant data from 6 randomized controlled trials of drug-coated balloon angioplasty for DES restenosis, we demonstrate that recurrent restenosis at follow-up angiography occurs in approximately 1 out of 5 patients.
- Predictors of recurrent restenosis are increased lesion length and small vessel size.
- Knowledge of the incidence and predictors of recurrent restenosis after drug-coated balloon angioplasty for DES restenosis may provide a basis for treatment optimization or individualization of revascularization strategies in specific patient and lesion subsets.

SUPPLEMENTARY MATERIAL



Supplementary material associated with this article can be found in the online version available at <http://dx.doi.org/10.1016/j.rec.2017.08.005>

REFERENCES

1. Byrne RA, Joner M, Kastrati A. Stent thrombosis and restenosis: what have we learned and where are we going? The Andreas Gruntzig Lecture ESC 2014. *Eur Heart J*. 2015;36:3320–3331.
2. Alfonso F, Byrne RA, Rivero F, Kastrati A. Current treatment of in-stent restenosis. *J Am Coll Cardiol*. 2014;63:2659–2673.
3. Windecker S, Kolh P, Alfonso F, et al. 2014 ESC/EACTS Guidelines on myocardial revascularization: The Task Force on Myocardial Revascularization of the European Society of Cardiology (ESC) and the European Association for Cardio-Thoracic Surgery (EACTS) Developed with the special contribution of the European Association of Percutaneous Cardiovascular Interventions (EAPCI). *Eur Heart J*. 2014;35:2541–2619.
4. Byrne RA, Joner M, Alfonso F, Kastrati A. Drug-coated balloon therapy in coronary and peripheral artery disease. *Nat Rev Cardiol*. 2014;11:13–23.
5. Siontis GC, Stefanini GG, Mavridis D, et al. Percutaneous coronary interventional strategies for treatment of in-stent restenosis: a network meta-analysis. *Lancet*. 2015;386:655–664.
6. Kufner S, Cassese S, Valeskini M, et al. Long-Term Efficacy and Safety of Paclitaxel-Eluting Balloon for the Treatment of Drug-Eluting Stent Restenosis: 3-Year Results of a Randomized Controlled Trial. *JACC Cardiovasc Interv*. 2015;8:877–884.
7. Cassese S, Byrne RA, Tada T, et al. Incidence and predictors of restenosis after coronary stenting in 10 004 patients with surveillance angiography. *Heart*. 2014;100:153–159.
8. Indermuehle A, Bahl R, Lansky AJ, et al. Drug-eluting balloon angioplasty for in-stent restenosis: a systematic review and meta-analysis of randomised controlled trials. *Heart*. 2013;99:327–333.
9. Higgins JP, Altman DG, Gotzsche PC, et al. Cochrane Bias Methods Group; Cochrane Statistical Methods Group. The Cochrane Collaboration's tool for assessing risk of bias in randomised trials. *BMJ*. 2011;343:d5928.
10. Juni P, Witschi A, Bloch R, Egger M. The hazards of scoring the quality of clinical trials for meta-analysis. *JAMA*. 1999;282:1054–1060.
11. Scheller B, Hehrlein C, Bocksch W, et al. Two year follow-up after treatment of coronary in-stent restenosis with a paclitaxel-coated balloon catheter. *Clin Res Cardiol*. 2008;97:773–781.
12. Habara S, Mitsudo K, Kadota K, et al. Effectiveness of paclitaxel-eluting balloon catheter in patients with sirolimus-eluting stent restenosis. *JACC Cardiovasc Interv*. 2011;4:149–154.
13. Rittger H, Brachmann J, Sinha AM, et al. A randomized, multicenter, single-blinded trial comparing paclitaxel-coated balloon angioplasty with plain balloon angioplasty in drug-eluting stent restenosis: the PEPCAD-DES study. *J Am Coll Cardiol*. 2012;59:1377–1382.
14. Habara S, Iwabuchi M, Inoue N, et al. A multicenter randomized comparison of paclitaxel-coated balloon catheter with conventional balloon angioplasty in patients with bare-metal stent restenosis and drug-eluting stent restenosis. *Am Heart J*. 2013;166:527–533.
15. Byrne RA, Neumann FJ, Mehilli J, et al. ISAR-DESIRE 3 investigators. Paclitaxel-eluting balloons, paclitaxel-eluting stents, and balloon angioplasty in patients with restenosis after implantation of a drug-eluting stent (ISAR-DESIRE 3): a randomised, open-label trial. *Lancet*. 2013;381:461–467.
16. Xu B, Gao R, Wang J, et al. PEPCAD China ISR Trial Investigators. A prospective, multicenter, randomized trial of paclitaxel-coated balloon versus paclitaxel-eluting stent for the treatment of drug-eluting stent in-stent restenosis: results from the PEPCAD China ISR trial. *JACC Cardiovasc Interv*. 2014;7:204–211.
17. Alfonso F, Pérez-Vizcayno MJ, Cárdenas A, et al. RIBS IV Study Investigators (under auspices of Interventional Cardiology Working Group of Spanish Society of Cardiology). A Prospective Randomized Trial of Drug-Eluting Balloons Versus Everolimus-Eluting Stents in Patients With In-Stent Restenosis of Drug-Eluting Stents: The RIBS IV Randomized Clinical Trial. *J Am Coll Cardiol*. 2015;66:23–33.
18. Mehran R, Dangas G, Abizaid AS, et al. Angiographic patterns of in-stent restenosis: classification and implications for long-term outcome. *Circulation*. 1999;100:1872–1878.
19. Stewart LA, Clarke M, Rovers M, et al. PRISMA-IPD Development Group. Preferred Reporting Items for Systematic Review and Meta-Analyses of individual participant data: the PRISMA-IPD Statement. *JAMA*. 2015;313:1657–1665.
20. Hausleiter J, Kastrati A, Mehilli J, et al. Impact of lesion complexity on the capacity of a trial to detect differences in stent performance: results from the ISAR-STEREO trial. *Am Heart J*. 2003;146:882–886.
21. Wöhrle J, Zadura M, Möbius-Winkler S, et al. SeQuentPlease World Wide Registry: clinical results of SeQuent please paclitaxel-coated balloon angioplasty in a large-scale, prospective registry study. *J Am Coll Cardiol*. 2012;60:1733–1738.
22. Habara S, Kadota K, Kanazawa T, et al. Paclitaxel-coated balloon catheter compared with drug-eluting stent for drug-eluting stent restenosis in routine clinical practice. *EuroIntervention*. 2016;11:1098–1105.

23. Alfonso F, Pérez-Vizcayno MJ, García del Blanco B, et al. under the auspices of the Interventional Cardiology Working Group of the Spanish Society of Cardiology. Everolimus-Eluting Stents in Patients With Bare-Metal and Drug-Eluting In-Stent Restenosis: Results From a Patient-Level Pooled Analysis of the RIBS IV and V Trials. *Circ Cardiovasc Interv.* 2016;9:e003479.
24. Gray WA, Granada JF. Drug-coated balloons for the prevention of vascular restenosis. *Circulation.* 2010;121:2672–2680.
25. Kang SJ, Mintz GS, Park DW, et al. Mechanisms of in-stent restenosis after drug-eluting stent implantation: intravascular ultrasound analysis. *Circ Cardiovasc Interv.* 2011;4:9–14.
26. Siontis GC, Piccolo R, Praz F, et al. Percutaneous Coronary Interventions for the Treatment of Stenoses in Small Coronary Arteries: A Network Meta-Analysis. *JACC Cardiovasc Interv.* 2016;9:1324–1334.
27. Rittger H, Wöhrle J, Brachmann J, et al. Angiographic patterns of drug-eluting stent restenosis after treatment with drug-coated balloon versus balloon angioplasty: Late lumen loss subgroup analyses of the PEPCAD-DES study. *Catheter Cardiovasc Interv.* 2016;88:529–534.
28. Clever YP, Peters D, Calisse J, et al. Novel Sirolimus-Coated Balloon Catheter: In Vivo Evaluation in a Porcine Coronary Model. *Circ Cardiovasc Interv.* 2016;9:e003543.