

Image in cardiology

Lung Ultrasound for Cardiogenic Shock in VA-ECMO



Ecografía pulmonar para el shock cardiogénico en ECMO-VA

Javier Rodríguez-Fanjul,^a Julio Moreno Hernando,^a and Joan Sánchez-de-Toledo^{b,c,*}

^aServicio de Neonatología, BCNatal, Sant Joan de Déu-Hospital Clínic, Barcelona, Spain

^bServicio de Cardiología Pediátrica, Sant Joan de Déu-Hospital Clínic, Barcelona, Spain

^cCritical Care Medicine Department, University of Pittsburgh, Pittsburgh, Pennsylvania, United States

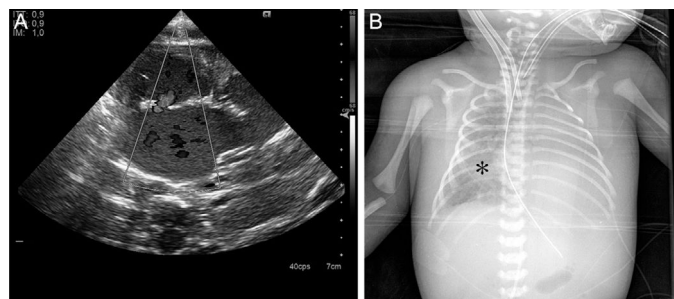


Figure 1.

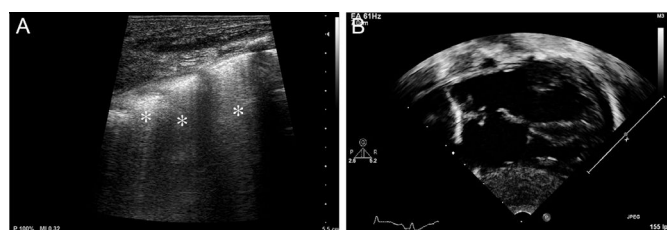


Figure 2.

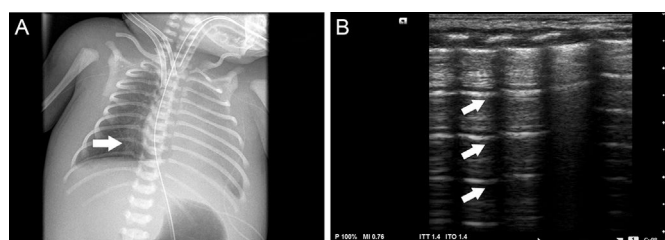


Figure 3.

A neonate was referred with a diagnosis of refractory cardiogenic shock resulting from dilated cardiomyopathy of unknown origin. Echocardiography showed dilation and severe dysfunction (left ventricular ejection fraction < 10%). Venoarterial extracorporeal membrane oxygenation (VA-ECMO) was started. Subsequent echocardiography showed persistence of dilatation of the left chambers (Figure 1A). Chest X-ray (Figure 1B) and lung ultrasound (Figure 2A) showed bilateral pulmonary edema (asterisks), indicated by the presence of B lines (hyperechogenic stripes perpendicular to the transducer and spreading from the pleural line across the screen) in the lung ultrasound (Figure 2A). Left heart decompression was performed by atrial balloon septostomy and the left atrium decreased in size (Figure 2B), with progressive recovery of ventricular function and resolution of pulmonary edema. Lung ultrasound was performed 48 hours after recovery of the pattern of normal pulmonary aeration, as indicated by chest X-ray (Figure 3A) and ultrasound, which showed the presence of A lines (hyperechogenic stripes parallel to the pleura) without the presence of B lines (arrows), a sign of normal pulmonary aeration (Figure 3B). The patient showed progressive improvement, and decannulation of ECMO was possible 7 days later. Echocardiography showed improvement in left ventricular function, with ejection fraction > 60%.

This case illustrates the sensitivity and usefulness of chest ultrasound compared with chest X-ray for monitoring pulmonary edema as it reduces children's exposure to ionizing radiation.

* Corresponding author:

E-mail address: joansdt@gmail.com (J. Sánchez-de-Toledo).

Available online 14 October 2017