

ECG Contest

ECG, June 2018

ECG de junio de 2018

Juan Caro-Codón,* Ángel M. Iniesta Manjavacas, and Mar Moreno Yangüela

Servicio de Cardiología, Hospital Universitario La Paz, Madrid, Spain



A 50-year-old woman with a family history of ischemic heart disease and no other risk factors attended the emergency department after a 15-minute episode of oppressive pain in the center of her chest. No electrocardiographic changes suggestive of ischemia were observed and markers of myocardial damage were negative. A resting echocardiogram showed no indication of structural heart disease. Subsequently, treadmill exercise echocardiography was performed to check for ischemia. This test was conclusive, with a clinically and echocardiographically negative result, and so the presence of myocardial ischemia was ruled out beyond reasonable doubt. The Figure shows the ECG obtained at 1 minute 30 seconds of recovery.

According to this trace, what is the most likely diagnosis?

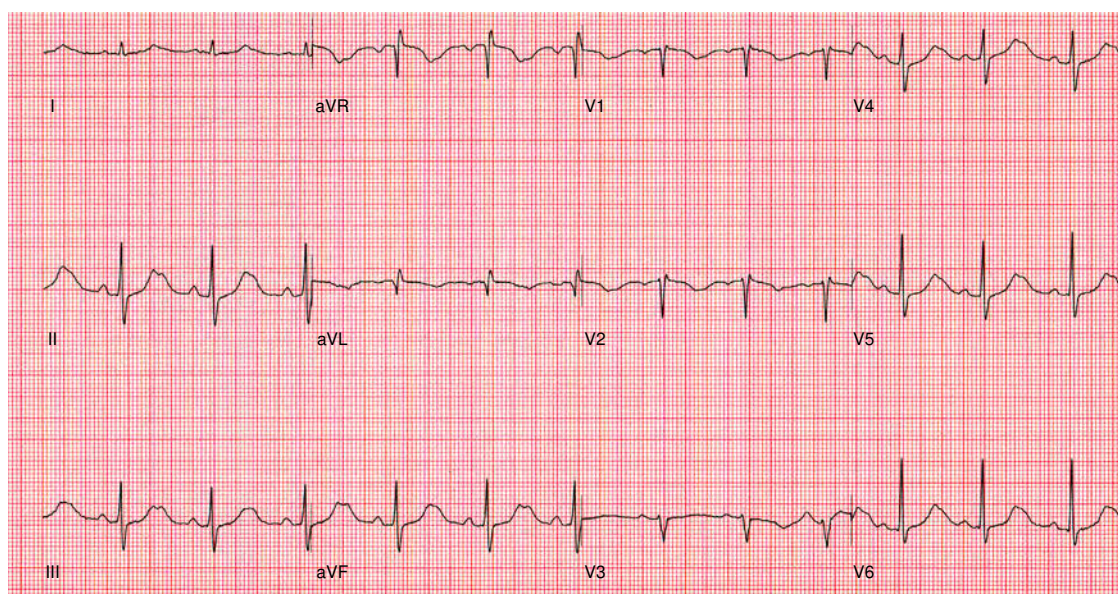


Figure.

1. Right-ventricular arrhythmogenic cardiomyopathy
2. Exercise-induced atrioventricular block
3. Type 1 long QT syndrome
4. Type 2 long QT syndrome

Suggest a diagnosis to this ECG Contest at <http://www.revespcardiol.org/en/electroreto/71/6>. The diagnosis will be published in the next issue (July 2018). #RetoECG.

* Corresponding author:

E-mail address: juancarocd@gmail.com (J. Caro-Codón).