

ECG Contest

Response to ECG, August 2018

Respuesta al ECG de agosto de 2018

Ana Andrés Lahuerta,* Joaquín Osca Asensi, and Víctor José Donoso Trenado

Departamento de Cardiología, Unidad de Arritmias, Hospital Universitario y Politécnico La Fe, Valencia, Spain

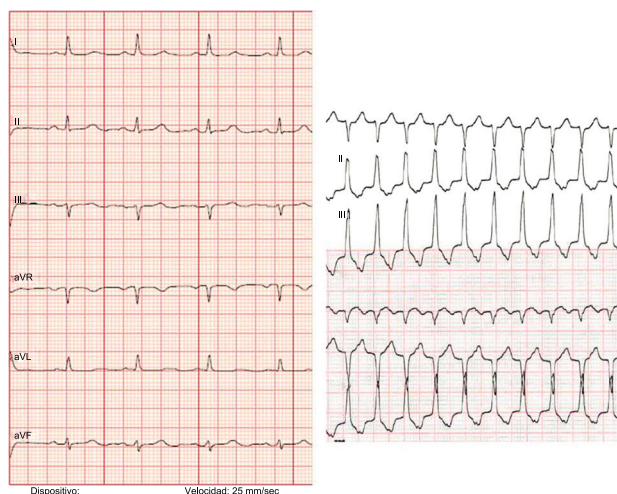

Figure 1.

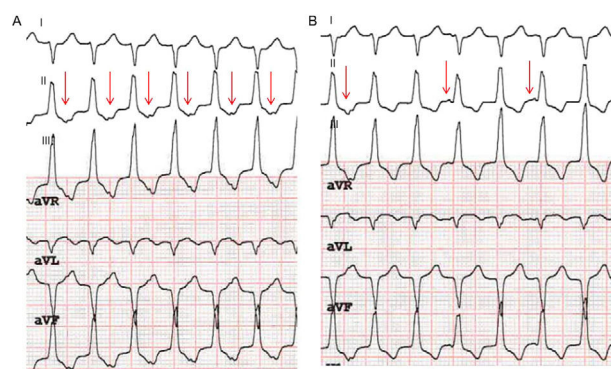


Figure 2.

The ECG recording during tachycardia shows a longer QRS interval than in sinus rhythm (115 ms). There are differences in the QRS morphology of tachycardia (90° axis during tachycardia vs 30° in sinus rhythm; negative complex in leads I and aVL in tachycardia vs positive complex in sinus rhythm) without meeting the criteria for aberrant conduction (Figure 1). Supraventricular tachycardia is ruled out (answers 1 and 2, incorrect). Prior to adenosine administration, a notched T wave can be observed in the lower leads, which could correspond to an atrial mechanism. An atrial/ventricular ratio of 1:1 is observed (Figure 2A). After adenosine administration, which interrupts ventriculoatrial conduction, atrioventricular dissociation can be observed (Figure 2B), confirming that this is ventricular tachycardia with 1:1 ventriculoatrial conduction (there is an effect of adenosine on the tachycardia but without conversion to sinus rhythm, thus ruling out option 3). The correct answer is therefore number 4: the electrophysiological diagnosis was idiopathic right ventricular outflow tract tachycardia.

SEE RELATED CONTENT:

<https://doi.org/10.1016/j.rec.2018.01.021>, *Rev Esp Cardiol.* xxxx;xx:xx-xx

* Corresponding author:

E-mail address: anaandreslahuerta@gmail.com (A. Andrés Lahuerta).

<https://doi.org/10.1016/j.rec.2018.01.022>

1885-5857/© 2018 Sociedad Española de Cardiología. Published by Elsevier España, S.L.U. All rights reserved.