

bances.^{4,5} Cardiac arrest has been described as a result of ischemia in the context of coronary involvement.²

Some authors have reported successful steroid therapy for the reduction of residual lesions after surgery,⁴ but there are also cases in which these agents were only able to stop tumoral growth⁶ and even 1 patient who developed symptoms under steroid therapy for extracardiac disease.⁵

To the best of our knowledge, this is the first reported case of cardiac IgG4-RD presenting as nonischemic cardiac arrest. It is also the first to report the use of rituximab, a B-cell depleting agent currently regarded as second-line therapy in IgG4-RD. While clinically stable, our patient showed no signs of mass reduction; we hypothesize that these therapeutic strategies act on the inflammatory component of the lesions, but are probably unable to reduce the established fibrotic reaction.

Acknowledgments

We would like to thank the contribution of the multidisciplinary team involved in the management of the patient, including Doctors Rui Almeida, Helena Baldaia, João Carlos Silva, and Jorge Almeida.

Gonçalo Pestana,^{a,*} Teresa Pinho,^{a,b} Catarina Costa,^{b,c} Pedro Bernardo Almeida,^{a,b} Paulo Pinho,^{b,d} and M. Júlia Maciel^{a,b}

^aCardiology Department, Centro Hospitalar São João, Porto, Portugal

^bFaculty of Medicine, Porto University, Porto, Portugal

^cAnatomical Pathology Department, Centro Hospitalar São João, Porto, Portugal

^dCardiac Surgery Department, Centro Hospitalar São João, Porto, Portugal

*Corresponding author:

E-mail address: gpestana.md@gmail.com (G. Pestana).

Available online 16 March 2018

REFERENCES

1. Kamisawa T, Zen Y, Pillai S, Stone JH. IgG4-related disease. *Lancet*. 2015;385:1460–1471.
2. Tajima M, Nagai R, Hiroi Y. IgG4-related cardiovascular disorders. *Int Heart J*. 2014;55:287–295.
3. Yang JH, Kim JS, Kim DK. Fibrotic periaortitis infiltrating into the aortic and mitral valves. *Rev Esp Cardiol*. 2013;66:662.
4. Yamauchi H, Satoh H, Yamashita T, et al. Immunoglobulin G4-related disease of the heart causing aortic regurgitation and heart block. *Ann Thorac Surg*. 2013;95:e151–e153.
5. Carbajal H, Waters L, Popovich J, et al. IgG4 related cardiac disease. *Methodist DeBakey Cardiovasc J*. 2013;9:230–232.
6. Ishida M, Sakaguchi T, Miyagawa S, et al. Right Ventricular Outflow Tract Obstruction Due to Immunoglobulin G4-Related Disease. *Ann Thorac Surg*. 2017;103:e235–e237.

<https://doi.org/10.1016/j.rec.2018.02.010>
1885-5857/

© 2018 Sociedad Española de Cardiología. Published by Elsevier España, S.L.U. All rights reserved.

Leadless Pacemaker Implantation in a Transplanted Heart



Implante de marcapasos sin cables en un corazón trasplantado

To the Editor,

Leadless pacemakers are a proven alternative to conventional pacemakers, with excellent outcomes in terms of safety and efficacy, a lower rate of complications, and optimal electrical performance in the short- and mid-term.^{1–3} These outcomes have been reported in both pivotal studies and in the clinical practice setting.^{2,3}

We present the case of a 54-year-old man who underwent orthotopic heart transplant with biatrial anastomosis for the indication of end-stage nonischemic heart disease in 2004. In the first 3 months after transplant, routine endomyocardial biopsies showed mild graft rejection (grade \leq IA), which resolved after increasing the intensity of immunosuppressive therapy. The patient remained asymptomatic until 2016, when he was admitted to hospital with broad QRS tachycardia (Figure 1A). Transthoracic echocardiography showed normal ventricular function, slight right ventricular dilatation, moderate tricuspid regurgitation, and right atrial dilatation. In the electrophysiology study, supraventricular tachycardia with aberrant conduction was detected (Figure 1A). Activation mapping confirmed a right atrial macro-reentrant circuit involving the superior vena cava. Radiofrequency ablation was applied to this site (Figure 2A), with reversion to sinus rhythm without subsequent arrhythmic reinduction. The patient remained asymptomatic in treatment with β -blockers and calcium antagonists for 6 months before experiencing clinical tachycardia associated with heart failure. A second electrophysiology study was scheduled. This study revealed severe sinus dysfunction,

prolonged infra-Hisian conduction (HV-interval), and alternating bundle branch block (Figure 1A and B). Programmed pacing was performed, without reinduction of clinical tachycardia or ventricular arrhythmias. In view of the limited efficacy of β -blockers in transplant patients and the possible negative effect of calcium antagonists, definitive pacemaker placement was considered the best option. Moreover, in view of the absence of atrial capture in the broad scarring area (Figure 2A) and immunosuppressive therapy, as well as the possible indication for a second heart transplant, a Micra leadless pacemaker (Medtronic Ibérica, S.A.) was implanted. The device was deployed in the mid-septal position after 3 attempts at different sites in the right ventricle, due to high thresholds; the acute parameters were impedance, 520 Ω ; R wave, 7.2 mV; and threshold, 1.88 V at 0.24 ms. After placement of the Micra device, atrioventricular node ablation was performed in the same procedure (Figure 2B). During follow-up, the pacing parameters were stable at 6 and 10 months after implantation: impedance, 500 Ω ; R wave, 7.9 mV; and threshold, 1.13 V at 0.24 ms. The ventricular pacing percentage was 100% and there were no infectious complications, embolisms, or readmissions due to heart failure.

Permanent electrical pacing is required in 5.8% of patients with orthotopic transplant,⁴ and in the late period this requirement can be a sign of rejection or severe vascular disease in the graft. In this case, in which aggressive immunosuppressive therapy is needed, pacemaker placement may increase the risk of infection.⁴ Leadless pacemaker placement is a promising alternative for transplant recipients given the lower risk of infection.⁵

It is important to note that the slightly increased pacing threshold in our patient could be due to diffuse cardiac fibrosis. This may call into question whether the strategy of atrioventricular node ablation and pacemaker placement in the same procedure is safe and more convenient for the patient or

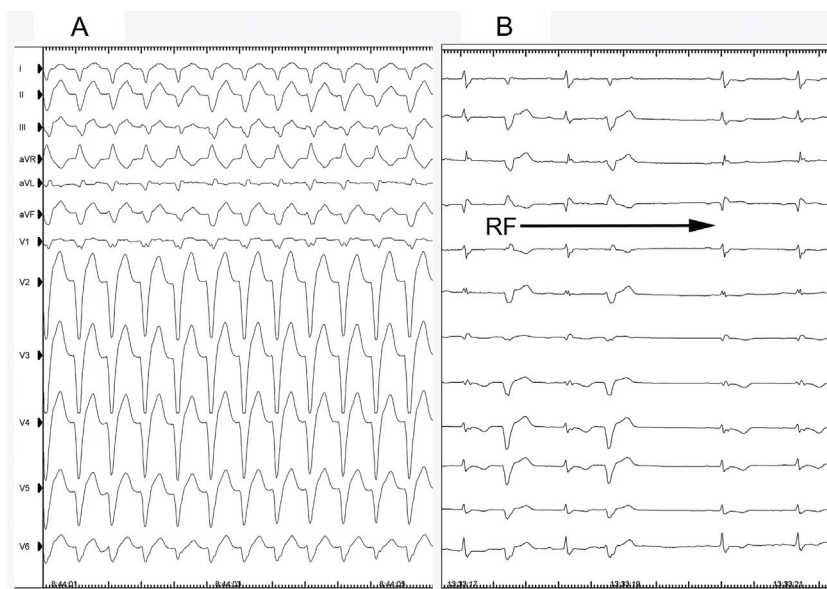


Figure 1. A, Electrocardiogram showing broad QRS tachycardia with left bundle branch block morphology. B, Intermittent aberrance during ablation and reversion to sinus rhythm. RF, radiofrequency.

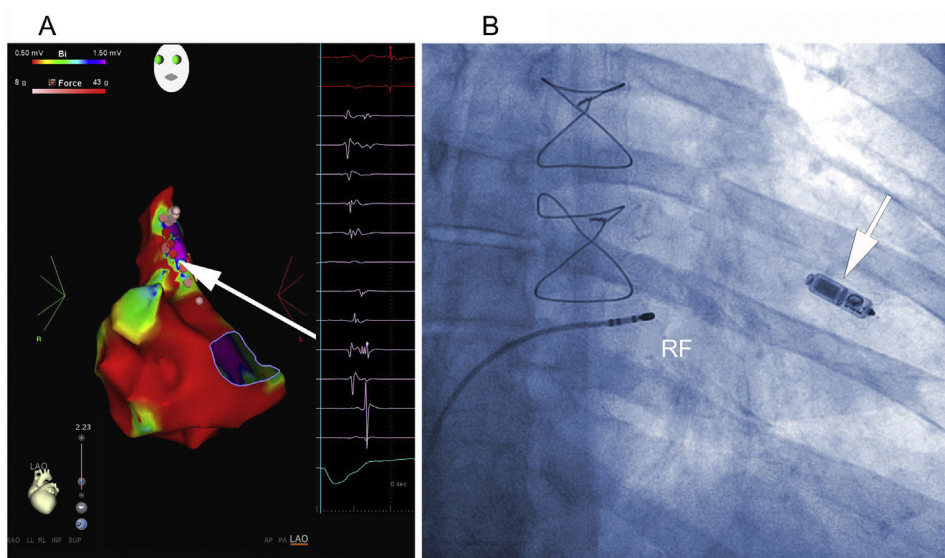


Figure 2. A, Electroanatomic voltage map of the right atrium during sinus rhythm, with ablation lesions toward the scarring areas and fractionated electrograms in the superolateral region of the right atrium. The arrow shows the site where flutter was interrupted during RF application. B, Ablation position of the atrioventricular node after Micra deployment in the mid septum of the right ventricle (arrow). RF, radiofrequency.

whether ablation should be performed once it has been confirmed that the device is working properly. As indicated in a recent publication,⁶ in most patients the device has a moderately increased threshold (<2 V at 0.24 ms), which decreases during follow-up, as was the case in this patient. In fact, in our center, this strategy is common practice without device capture or dislocation complications. However, we also believe that the strategy should be confirmed in future studies that demonstrate its safety in a larger number of patients before the approach becomes widespread.

This case shows the feasibility of leadless pacemaker placement with atrioventricular node ablation in a patient with orthotopic transplant. Given the risk of rejection and infection in these patients, use of a leadless pacemaker could be considered as an alternative to conventional pacemakers.

CONFLICTS OF INTEREST

J.L. Martínez-Sande is a Micra pacemaker (Medtronic) consultant.

José Luis Martínez-Sande,* Javier García-Seara,
Laila González-Melchor, Moisés Rodríguez-Mañero,
Inés Gómez-Otero, and José Ramón González-Juanatey

Unidad de Arritmias y Electrofisiología Cardíaca, Servicio de
Cardiología, Hospital Clínico Universitario de Santiago de Compostela,
Instituto para el Desarrollo e Integración de la Salud (IDIS), Centro de
Investigación Biomédica en Red de Enfermedades Cardiovasculares
(CIBERCV), Santiago de Compostela, A Coruña, Spain

* Corresponding author:

E-mail address: luismartinezsande@gmail.com

(J.L. Martínez-Sande).

Available online 17 May 2018

REFERENCES

1. Reynolds D, Duray GZ, Omar R, et al. Micra Transcatheter Pacing Study Group. A leadless intracardiac transcatheter pacing system. *N Engl J Med*. 2016;374:533–541.

2. Roberts PR, Clementy N, Al Samadi F, et al. A leadless pacemaker in the real-world setting: The Micra Transcatheter Pacing System PostApproval Registry. *Heart Rhythm*. 2017;14:1375–1379.
3. Martínez-Sande JL, García-Seara J, Rodríguez-Mañero M, et al. The Micra leadless transcatheter pacemaker. Implantation and mid-term follow-up results in a single center. *Rev Esp Cardiol*. 2017;70:275–281.
4. Mallidi HR, Bates M. Pacemaker use following heart transplantation. *Ochsner J*. 2017;17:20–24.
5. Kypta A, Blessberger H, Kammler J, et al. Leadless cardiac pacemaker implantation after lead extraction in patients with severe device infection. *J Cardiovasc Electro-physiol*. 2016;27:1067–1071.
6. Piccini JP, Stromberg K, Jackson KP, et al. Long-term outcomes in leadless Micra transcatheter pacemakers with elevated thresholds at implantation: Results from the Micra Transcatheter Pacing System Global Clinical Trial. *Heart Rhythm*. 2017;14:685–691.

<https://doi.org/10.1016/j.rec.2018.02.022>

1885-5857/

© 2018 Sociedad Española de Cardiología. Published by Elsevier España, S.L.U. All rights reserved.

Gender Differences in the Professional Lives of Cardiologists in 70 Spanish Hospitals



Diferencias de género en la carrera profesional de los cardiólogos en 70 hospitales españoles

To the Editor,

In Spain, the number of female physicians has increased considerably, rising from 35% in 2000 to 51.9% in 2017 (in the United States this figure is 35%; in Italy, 40%; and in the United Kingdom, 46%).¹ However, there remain fewer women in positions of responsibility and internal promotion.^{2–5} The current representation of women in the clinical and academic ranks of Spanish cardiology is unknown. The aims of this study were to analyze: *a*) the sex distribution in the different subspecialties, and *b*) the representation of women in cardiology in Spain in all the clinical and academic strata.

We designed a cross-sectional study consisting of a questionnaire sent to heads of department of cardiology from the 98 hospitals across the country, via the Spanish Society of Cardiology and the IESE Business School of Barcelona. The cardiology departments were classified according to the unit type classification used in the SEC-RECALCAR 2016 registry.⁶

The Spanish Society of Cardiology provided a list of the 98 hospitals. The questionnaire included 26 items related to: *a*) level of hospital; *b*) demographic characteristics (sex distribution by age range); *c*) sex distribution by specialty and subspecialty; *d*) sex distribution by clinical rank, and *e*) sex distribution by academic rank.

Subspecialties were assigned according to each cardiologist's primary role. The definitions of fellow and area coordinator were, respectively: a specialist in cardiology undergoing training in a subspecialty, and a cardiologist coordinating a particular health care area, similar to the role of clinical head, but without an official designation. The other positions were as per standard use. Categorical variables are described as No. (%). Differences between percentage rates were analyzed with the chi-square test.

Seventy cardiology departments completed the questionnaire (71% of the hospitals surveyed) (supplementary material). Of all the hospitals that took part, 19.5% were level 1-2; 31.6% were level 3, and 48.9% were level 4. The participation rate was higher in level 3 and 4 hospitals, at 64% in level 1 and level 2, 71% in level 3, and 85.5% in level 4.

In the autonomous communities of Aragón, Asturias, Cantabria, Castile and León, Extremadura, Murcia, and the Basque Country,

100% of the hospitals surveyed responded, while in the Balearic Islands, Canary Islands, and Valencian Community the participation rate was < 60%. For all 70 hospitals, there were 2353 cardiologists in total, and 40% were women. The women were significantly younger than the men: 67.3% were ≤ 40 years old ($P < .001$). Women tended to choose less invasive subspecialties (clinical cardiology and imaging) than men ($P < .001$) (Figure A).

The representation of women by clinical rank is shown in Figure B; the higher up the hierarchy, the lower the representation of women, with women comprising only 19% and 11% of head of section and head of department posts, respectively.

There was higher inclusion of women in lower-category hospitals, and this decreased as the hospital category increased (Table). Specifically, the number of female heads of department was lower in the higher hospital levels, and there were no women in the level 4 hospitals. By autonomous community, we observed that the communities with the highest female representation in cardiology were Aragón (46%), the Basque Country (44%), and Catalonia and Navarra (43%). Last, regarding academic representation, a total of 220 cardiologists reported that they worked as university professors, 66 of whom were women (30%). Among associate professors, 35% were women and only 4 of the tenured professors (7%) were women.

From the results of this study (with a high response rate, making the data robust), we can conclude that: *a*) overall, including trainees, women comprise almost half of all cardiologists (40% of the total); *b*) the higher the clinical and academic rank, the lower the female representation: representation is particularly low among heads of department and tenured professors, generating a vertical gap; *c*) in Spain there is a horizontal gap, as female cardiologists tend to opt for less invasive subspecialties; *d*) representation of women is lower in higher hospital categories; and *e*) the distribution of women by autonomous community is homogenous.

Several studies have investigated the possible causes of lower representation of women in senior positions.^{2–5} Among them is difficulty balancing professional and family life, which, as reported in several national and international surveys, is the main concern for women in medicine.^{2–5} The responsibility for childcare—falling mainly to women—means that they consider themselves unlikely to be able to compete successfully with other colleagues.^{4–5} This renunciation could reflect the lower number of women in the cardiological hierarchy, as shown by our data. This lower