

Image in cardiology

Rare Variant of Aortic Dissection: Circumferential Dissection

Variante rara de disección de aorta: disección circumferencial

Laura Díaz-Chirón Sánchez,^{a,*} Carlota Vigil-Escalera López,^a and Juan Calvo Blanco^b

^aÁrea de Gestión Clínica del Corazón, Hospital Universitario Central de Asturias, Oviedo, Asturias, Spain

^bServicio de Radiología, Hospital Universitario Central de Asturias, Oviedo, Asturias, Spain

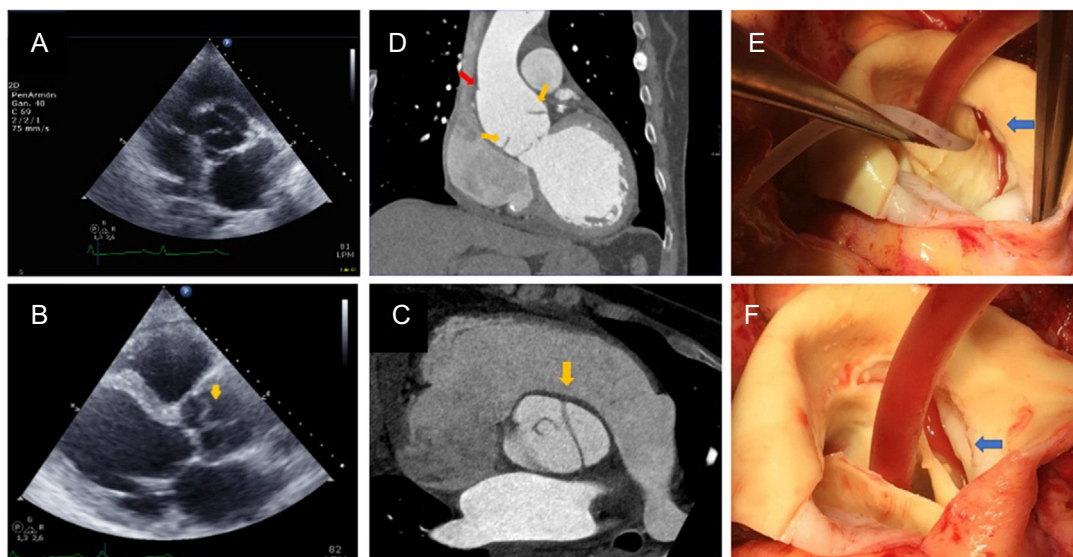


Figure.

A 45-year-old man, whose only medical history of interest was that he was a smoker who drank alcohol, attended the clinic for dyspnea with onset a few weeks earlier, orthopnea, paroxysmal nocturnal dyspnea, and leg edema. Physical examination revealed systolic murmur with aortic diastolic murmur, bilateral rales, and edema up to the top of the thighs. The echocardiogram showed biventricular dilatation and severe dysfunction, severe bicuspid aortic valve regurgitation, dilatation of the ascending aorta, and, within the aorta, a mobile image indicative of dissection (Figure A and B; arrow shows intimal flap). Computed tomography showed an intimal flap in the supracoronary region (Figure C and D, yellow arrows) and an irregular aortic wall (Figure D, red arrow), consistent with limited intimal rupture. This is a case of severe, probably chronic, bicuspid valve regurgitation, dilatation, and secondary ventricular failure and silent type 3 dissection according to the Svensson classification.

In surgery, chronic dissection was confirmed, located in the aortic root, with damage to the right and left ostium without spread to the ascending aorta (Figure E and F; arrows: line of dissection). Replacement of the valve and ascending aorta was performed by the Bentall-Bono procedure. The postoperative period was free of complications.

Circumferential dissection is a rare type of aortic dissection, characterized by an intimal flap and absence of false lumen. Circumferential detachment of the intima occurs, and this becomes invaginated. Given the absence of false lumen, it is difficult to diagnose, as the only finding may be a protuberance in the aortic wall. The imaging findings are an intimal flap with flap inversion, absence of false lumen, and aortic dilation with an irregular wall.

* Corresponding author:

E-mail address: lauradcs89@gmail.com (L. Díaz-Chirón Sánchez).

Available online 17 July 2018