

Image in cardiology

# Physiology and imaging for woven disease management

## Fisiología e imagen en el abordaje de la enfermedad coronaria en entramado

Victoria Vilalta,\* Oriol Rodriguez-Leor, and Omar Abdul-Jawad

Unidad de Cardiología Intervencionista, Servicio de Cardiología, Hospital Universitari Germans Trias i Pujol, Badalona, Barcelona, Spain

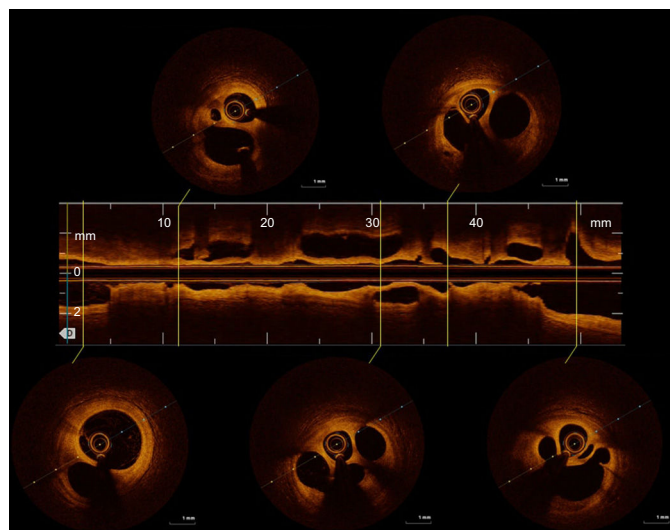


Figure 1.

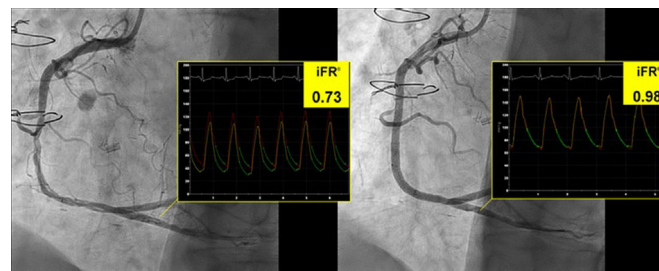


Figure 2.

Woven coronary artery disease is a rare congenital anomaly in which epicardial coronary arteries are divided into multiple microchannels that merge again in a main conduit.

This vascular variation has been considered benign, and conservative treatment has been the recommended strategy for treating these patients. However, myocardial infarction and thrombus formation is reported in some woven arteries. Angiography and optical coherence tomography are used to establish the diagnosis and to rule out other conditions such as thrombus, spontaneous dissection, and chronic occlusion with collaterals. No physiological evidence has been previously reported.

We report the case of a 59-year-old male, smoker with a history of hypertension, diabetes, and 2-vessel disease (left anterior descending and circumflex) treated with a coronary bypass graft in 2012. He was referred to our hospital with a non-ST elevation myocardial infarction. Angiography disclosed patent grafts and a multiple twisted lumen in the midsegment of the right coronary artery (Video 1 of the supplementary data), which was confirmed with optical coherence tomography (Figure 1, Video 2 of the supplementary data). An instantaneous wave-free ratio (iFR) of 0.73, suggestive of flow impairment (Figure 2), prompted implantation of a drug eluting stent with good result (Video 3 of the supplementary data). The iFR after stent implantation was 0.98.

Physiological lesion assessment is valuable for prognosis in percutaneous revascularization, and both European and American guidelines recommend this practice. Conservative management has been previously proposed in woven disease, yet here we show for the first time flow impairment induced by woven microchannels. Our finding contributes to a better understanding of this anomaly with important management implications.

### APPENDIX. SUPPLEMENTARY DATA

Supplementary data associated with this article can be found in the online version, at <https://doi.org/10.1016/j.rec.2018.09.010>.

\* Corresponding author:

E-mail address: [victoria.vilalta@gmail.com](mailto:victoria.vilalta@gmail.com) (V. Vilalta).