

Scientific letters

Incomplete Mass Phenotype: Description of a New Pathogenic Variant of the Fibrillin-1 Gene



Fenotipo incompleto de síndrome de Marfan tipo MASS: descripción de nueva variante patogénica del gen de la fibrilina-1

To the Editor,

We report a family with many members affected by a form of incomplete Marfan syndrome (MS) called the MASS phenotype. The MASS phenotype consists of mitral valve prolapse (M), nonprogressive aortic root dilatation (A), musculoskeletal findings (S), and skin striae (S), thus resembling features of MS but not meeting the diagnostic criteria for this disease.¹ Familial genetic analysis confirmed the pathogenicity of a nonsynonymous mutation (NP_000129.3:p.Pro1424Ser, NM_000138.4:c.4270C >T) in the fibrillin-1 gene (FBN1).

The index patients were 2 brothers who underwent aortic replacement for aortic root dilatation (patients IV.8 and IV.9 in

Figure 1A). These patients had a family history of sudden cardiac death, with postmortem examinations of their mother and aunt having revealed aortic dissection. The patients were assessed for ocular and locomotor function and underwent a thoracoabdominal computed tomography examination, and 1 of the patients was screened by high throughput sequencing targeting a 30-gene panel. A single study with this panel permitted cost-effective analysis of point mutations and copy number variants (CNV; large deletions and duplications) and elimination of other candidate syndromes.

The genetic screen detected a missense mutation in a coding region in exon 34 of FBN1 (a single nucleotide change resulting in an amino acid alteration: p.Pro1424Ser). This mutation appears in the UMD-FBN1 mutation database in a single patient who met the criteria for MS; however, there was no recorded analysis of familial cosegregation, which is essential for confirming a mutation as pathogenic.^{1,2} No record of this mutation was found in other publicly available genotype databases, and searches of the ExAC

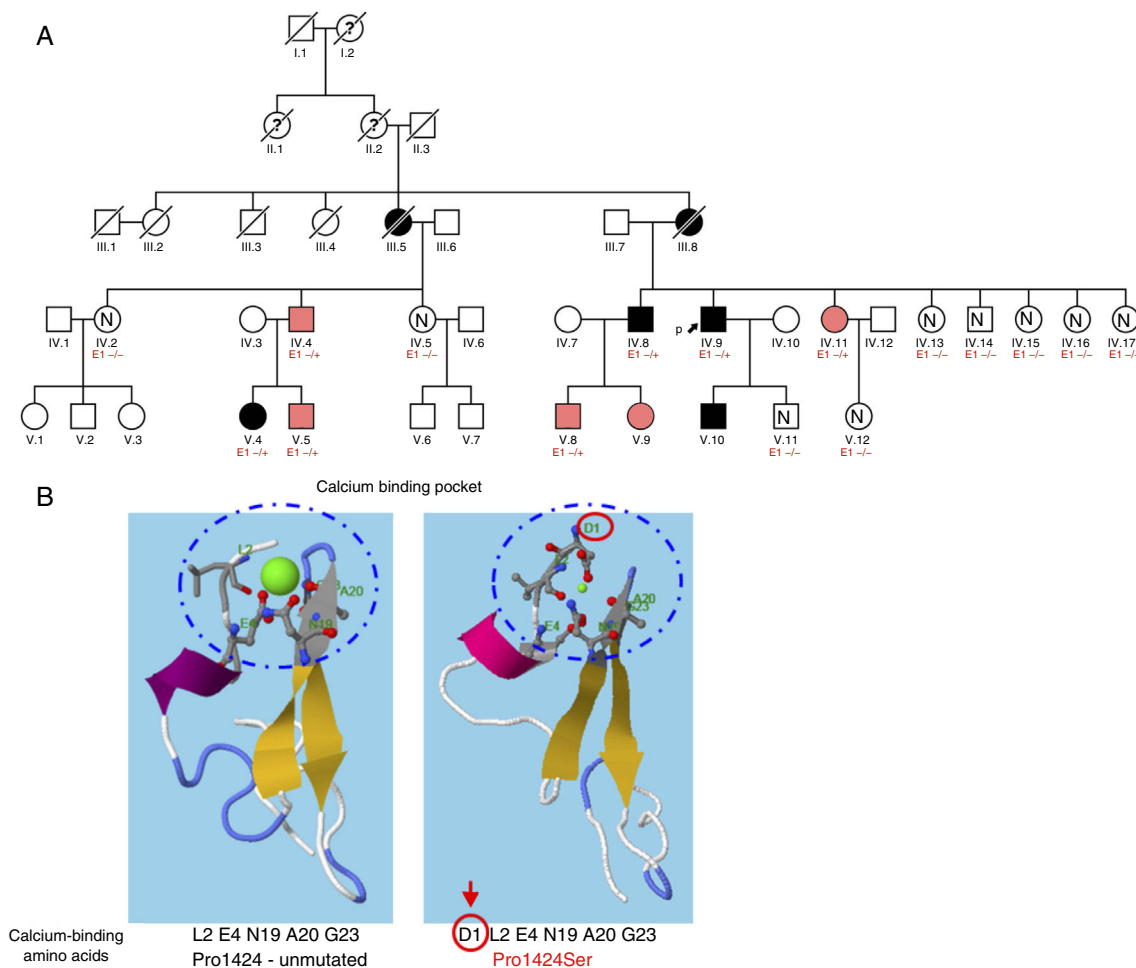


Figure 1. A, Family tree. Patients represented by black shading meet the criteria for Marfan syndrome, whereas those represented by pink shading have the MASS phenotype. B, RaptorX *in silico* analysis of the calcium binding site in the EGF-like domain 24 of FBN1, comparing the unmutated form with the change caused by the Pro1424Ser mutation in FBN1. E1-/+ , heterozygote for Pro1424Ser; E1-/-, noncarrier.

Table 1
Phenotypic Characteristics of Family Members

	Sex	Age, Years	Cardiovascular System	Eyes	Nervous System	Locomotor Apparatus	Skin	Lungs	Other	MS Diagnosis (Revised Ghent Nosology)
IV.4	Man	55	Z score = 1.3	Myopia < 3 diopters	No DE	Scoliosis		–	Above-normal height (1.9 m) Bilateral inguinal hernias Hip osteoarthritis	No (systemic score = 1)
IV.8	Man	48	Treated for aortic aneurysm		*	Flat foot deformity		–	Above-normal height (1.9 m) Hip osteoarthritis Inguinal hernia	Yes (mutation + aorta Z score \geq 2)
IV.9	Man	55	Treated for aortic aneurysm	Myopia < 3 diopters	No DE	Hip osteoarthritis		–	Hip osteoarthritis	Yes (mutation + aorta Z score \geq 2)
IV.11	Woman	50	Z score = 1.2	Myopia > 3 diopters	*	Positive wrist sign Hindfoot deformity			Above-normal height (1.8 m)	No (systemic score = 1)
V.4	Woman	26	MVP Z score = 1	Myopia > 3 diopters	Spina bifida occulta	Scoliosis Pectus carinatum deformity	Skin striae		Facial characteristics (retrognathia, malar hypoplasia, and enophthalmos) Above-normal height (1.85 m)	Yes (mutation + systemic score = 7)
V.5	Man	29	MVP Z score = 1.2		Spina bifida occulta	Positive wrist sign Flat foot deformity Scoliosis	Skin striae		Above-normal height (1.9 m), Facial characteristics (retrognathia, enophthalmos, and malar hypoplasia)	No (systemic score = 6)
V.8	Man	17	MVP Z score = 1.3		*	Positive thumb sign Scoliosis Hindfoot deformity			Above-normal height (1.96 m)	No (systemic score = 5)
V.9	Woman	12	MVP Z score = 0.9		*	Kyphosis Hindfoot deformity				No (systemic score = 4)
V.10	Man	29	Z score = 2.1	Myopia < 3 diopters	*	Above-normal height				Yes (mutation + aorta Z score \geq 2)

DE, dural ectasia; MVP, mitral valve prolapse.

* No assessment of the vertebral column by magnetic resonance imaging or computed tomography.

and gnomAD population databases identified no mutation carriers, indicating a very low allele frequency in control populations. *In silico* studies with the RaptorX program showed that the affected proline residue (Pro1424) participates in hydrogen bonds required for the formation of the calcium binding site in this region (epidermal growth factor [EGF] like domain 24). The substitution of this proline by serine would alter the site and cause protein misfolding and disrupted function (Figure 1B).³

A complete familial analysis (Figure 1A) detected the c.4270C >T mutation in 9 family members manifesting variable signs of MS (Table 1). Aortic root dilatation was reported only in the probands and patient V.10, and the most frequent cardiovascular finding was mitral valve prolapse. Myopia > 3 diopters was recorded in 2 patients, and none of the patients had ectopia lentis. Almost all patients had skeletal alterations. Most had scoliosis, flat foot deformity, or above-normal height, whereas wrist or thumb signs were found in only 3 patients. No pathological findings were recorded in noncarrier relatives.

Together, these data indicate familial cosegregation of the mutation with variable clinical manifestations. This behavior has been described previously for pathogenic mutations of this gene,⁴ and complete familial analyses should therefore be conducted at referral centers to obtain a better understanding of the phenotypic behavior of these gene variants.⁵ All the patients apart from V.4, IV.8, and IV.9 can be categorized as having the MASS phenotype because they do not meet one of the revised Ghent criteria for MS.¹ Most of the carriers are young, which might explain the general absence of cardinal manifestations such as aortic root dilatation and ectopia lentis. Trans-acting mutations in *FBN1* have been proposed to play a modifying role,⁴ and a recent study demonstrated that cis-regulatory variants can be present in the same allele as a disease-causing mutation, providing a possible explanation for the variable penetrance and expressivity observed in mutation carriers.⁶ Although c.4270C >T mutation carriers showed no signs of dural ectasia, spina bifida occulta was detected in 2 brothers (V.4 and V.5).

Another mutation affecting the same amino acid has been identified in several MS patients. However, the Pro1424Ala (g.48764814G >C) mutation has not been examined by cosegregation analysis, and this variant has been identified in 54 out of 277 166 individuals in gnomAD control populations, raising doubts about its pathogenicity.

In summary, the clinical and genetic study of this family confirms the association of the p.Pro1424Ser genetic variant in *FBN1* with the development of the MASS phenotype and MS. Although the phenotypes generated by this genetic variant vary widely and are sometimes mild, it is important to monitor aortic diameter regularly in carriers of this mutation because it can be associated with aneurysm and dissection.

CONFLICTS OF INTEREST

J.P. Trujillo-Quintero and L. Montserrat are members of the genetic diagnostics company *Health in Code*.

Jesús Piqueras-Flores,^{a,b,*} Juan Pablo Trujillo-Quintero,^c Raquel Frías-García,^a María Arántzazu González-Marín,^d Lorenzo Monserrat,^c and Germán Hernández-Herrera^a

^aServicio de Cardiología, Hospital General Universitario de Ciudad Real, Ciudad Real, Spain

^bUnidad de Cardiopatías Familiares y Muerte Súbita, Hospital General Universitario de Ciudad Real, Ciudad Real, Spain

^cComité científico, Health in Code, A Coruña, Spain

^dServicio de Pediatría, Hospital General Universitario de Ciudad Real, Ciudad Real, Spain

* Corresponding author: Hospital General Universitario de Ciudad Real. Avenida Obispo Rafael Torija, 13005 Ciudad Real, Spain. 6372720679.

E-mail address: jesus.piqueras.flores@gmail.com (J. Piqueras-Flores).

Available online 01 May 2019

REFERENCES

- Loeys BL, Dietz HC, Braverman AC, et al. The revised Ghent nosology for the Marfan syndrome. *J Med Genet.* 2010;47:476–485.
- Arbustini E, Grasso M, Ansaldi S, et al. Identification of sixty-two novel and twelve known *FBN1* mutations in eighty-one unrelated probands with Marfan syndrome and other fibrillinopathies. *Hum Mutat.* 2005;26:494.
- Kallberg M, Wang H, Wang S, et al. Template-based protein structure modeling using the RaptorX web server. *Nat Protoc.* 2012;7:1511–1522.
- Díaz de Bustamante A, Ruiz-Casares E, Darnaude MT, Perucho T, Martínez-Quesada G. Variabilidad fenotípica del síndrome de Marfan en una familia con una nueva mutación en el gen *FBN1*. *Rev Esp Cardiol.* 2012;65:380–381.
- Trujillo-Quintero JP, Herrera-Noreña JM, Mosquera-Rodríguez VX, Fernández-Fernández X, Vázquez-Rodríguez JM, Barriales-Villa R. Extensa familia con síndrome de Marfan en la que se demuestra la patogenicidad de una variante «sinónima» (p.Ile2118 =) en el gen de la fibrilina 1. *Rev Esp Cardiol.* 2017;70:679–681.
- Castel SE, Cervera A, Mohammadi P, et al. Modified penetrance of coding variants by cis-regulatory variation contributes to disease risk. *Nat Genet.* 2018;50:1327–1334.

<https://doi.org/10.1016/j.rec.2019.01.014>
1885-5857/

© 2019 Sociedad Española de Cardiología. Published by Elsevier España, S.L.U. All rights reserved.

Palliative Care Needs in Heart Failure. A Multicenter Study Using the NECPAL Questionnaire



Necesidad de cuidados paliativos en insuficiencia cardiaca: estudio multicéntrico utilizando el cuestionario NECPAL

To the Editor,

Palliative care (PC) support has been broadened in the last few years to include patients with advanced-stage disease. Although heart failure (HF) has a poor prognosis, very few patients are actually included in PC programs¹ due to a lack of integration of PC

in HF management and its unpredictable clinical trajectory. Currently, prognostic markers in HF are highly focused on heart disease and have major limitations, since they do not include multimorbidity or other parameters such as dependence and frailty. PC involves support of physical, emotional and spiritual needs to both patients and their families and is not limited to end-of-life care. Nowadays, PC in HF is an unresolved challenge and identifying those patients who might require some type of palliative intervention is mandatory. The aim of our study was to evaluate theoretical PC requirements in HF by a simple scale that integrates predictive variables of HF severity with palliative