

ECG Contest

Response to ecg, november 2019

Respuesta al ECG de noviembre de 2019

M. Rocío Gómez-Domínguez,\* Miguel E. Jáuregui-Abularach, and Albina Aldomá-Balash

Servicio de Cardiología, Hospital Arnau de Vilanova, IRBLleida, Lleida, Spain

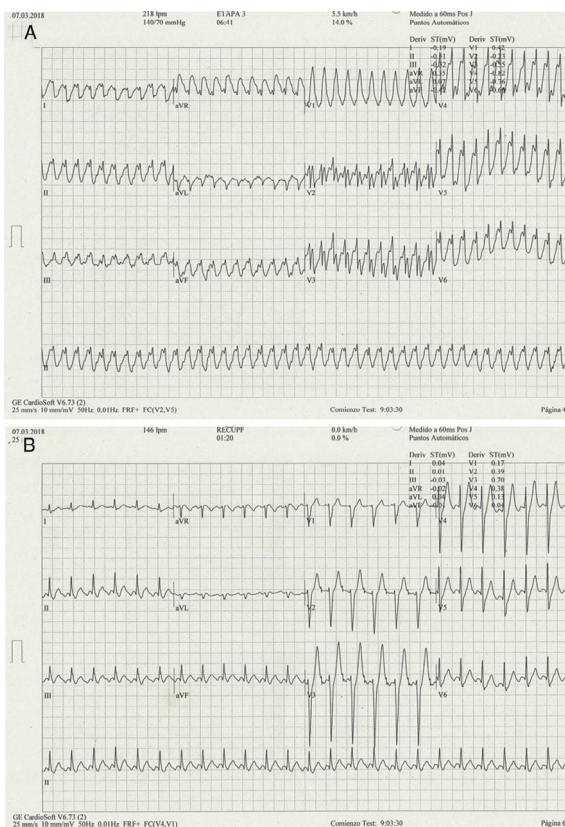


Figure 1.

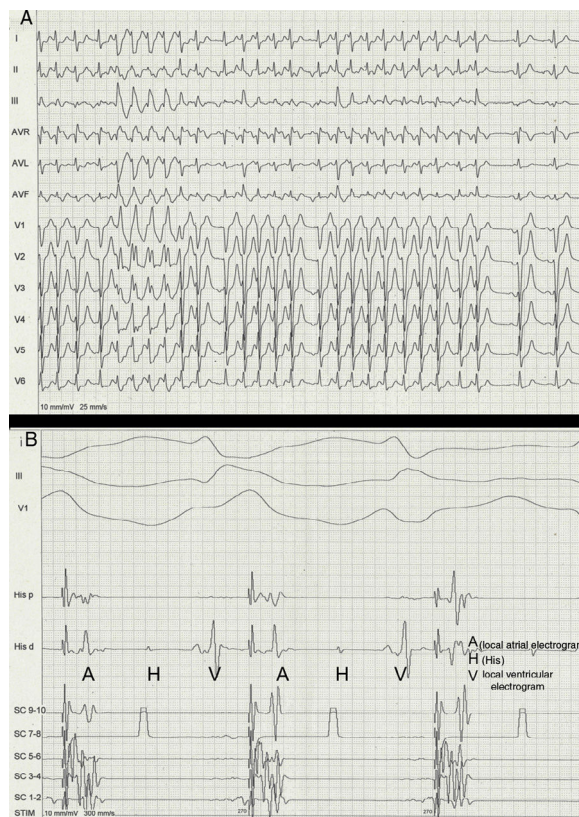


Figure 2.

Diagnostic certainty in these tachycardias is not possible with the 2 main differential diagnostic algorithms (Figure 1A), given that they yield different results: the Brugada algorithm suggests a process with a ventricular origin whereas the Vereckei one points to a supraventricular origin; therefore, responses 1 and 2 are incorrect.<sup>1</sup>

Figure 1B shows the ECG after resolution of the tachycardia. This is consistent with atrial flutter with 2:1 atrioventricular conduction and common atrial flutter with F wave morphology/polarity. During atrial stimulation with isoproterenol, electrophysiological study showed his-Purkinje axis aberrancy with a QRS complex very similar to that of the tachycardia (Figure 2A). The supraventricular origin was confirmed by the intracavitary electrogram (Figure 2B). Therefore, this is a 1:1 conduction atrial flutter with right branch and left bundle branch aberrancy, causing right shift of QRS axis (response 3 is incorrect, response 4 is correct). The cavotricuspid isthmus was successfully ablated.

REFERENCE

1. Kaiser E, Darrieux FC, Barbosa SA, et al. Differential diagnosis of wide QRS tachycardias: comparison of two electrocardiographic algorithms. *Europace*. 2015;17:1422–1427.

SEE RELATED CONTENT:  
<https://doi.org/10.1016/j.rec.2018.12.011>

\* Corresponding author:  
 E-mail address: [rousgd@hotmail.com](mailto:rousgd@hotmail.com) (M.R. Gómez-Domínguez).