

Table 1
Characteristics at baseline and 30-day follow-up

Patients, n	29
Age, y	82 ± 3.98
Male sex, %	37.9
Hypertension, %	100
Grade I-II/III-IV dyspnea, %	47.6/52.4
Diabetes mellitus, %	72.7
Hyperlipidemia, %	90.5
Chronic kidney disease, %	20.6
Obstructive pulmonary disease, %	13.6
Previous pacemaker, %	17.2
Valve-in-valve, %	10.3
Previous coronary disease, %	51.7
Previous stroke, %	10.3
Mean axillary artery diameter, mm	5.7 ± 0.63
Katz Index = 0, %	51.7
Society of Thoracic Surgeons Score	3.13 ± 1.62
EuroSCORE	15.45 ± 11.83
EuroSCORE II	3.61 ± 2.7
Follow-up at 30 days	
Death	0
Myocardial infarction	0
Minor stroke	0
Major stroke	1 (3.44)
Conversion to transaortic access	1 (3.44)
New pacemaker implant	4 (13.79)
Acute renal failure	4 (13.79)
Valve embolization	1 (3.44)
Minor vascular complication	1 (3.44)
Major vascular complication	0
Aortic paravalvular leak > grade II	1 (3.44)
Procedure success, %	100
Device success, %	97.1

CONFLICTS OF INTEREST

J.F. Díaz Fernández is a proctor for the Portico valve.

Rosa María Cardenal Piris,^{a,*} Omar Araji Tiliani,^b
José Francisco Díaz Fernández,^a Nuria Miranda Balbuena,^b
Antonio Gómez Menchero,^a and José Miguel Barquero Aroca^b

^aUnidad de Cardiología Intervencionista, Servicio de Cardiología,
Hospital Juan Ramón Jiménez, Huelva, Spain

^bServicio de Cirugía Cardiovascular, Hospital Universitario
Virgen Macarena, Sevilla, Spain

* Corresponding author:

E-mail address: rcpiris@gmail.com (R.M. Cardenal Piris).

Available online 4 November 2019

REFERENCES

- Baumgartner H, Falk V, Bax JJ, et al. 2017 ESC/EACTS Guidelines on the management of valvular heart disease. *Eur Heart J*. 2017;38:2739–2791.
- Pasala TKR, Ruiz CE. El TAVI como primera opción en la estenosis aórtica grave: ¿quimera o realidad? *Rev Esp Cardiol*. 2018;71:141–145.
- Chandrasekhar J, Hibbert B, Ruel M, Lam BK, Labinaz M, Glover C. Transfemoral vs non-transfemoral access for transcatheter aortic valve implantation: a systematic review and meta-analysis. *Can J Cardiol*. 2015;31:1427–1438.
- Bruschi G, Colombo P, Botta L, et al. Portico sheathless transcatheter aortic valve implantation via distal axillary artery. *Ann Thorac Surg*. 2017;103:e175–e177.
- Taramasso M, Denegri A, Kuwata S, et al. Feasibility and safety of transfemoral sheathless Portico aortic valve implantation: preliminary results in a single center experience. *Catheter Cardiovasc Interv*. 2018;91:533–539.
- Schäfer U, Deuschl F, Schofer N, et al. Safety and efficacy of the percutaneous transaxillary access for transcatheter aortic valve implantation using various transcatheter heart valves in 100 consecutive patients. *Int J Cardiol*. 2017;232:247–254.

<https://doi.org/10.1016/j.rec.2019.07.016>
1885-5857/

© 2019 Sociedad Española de Cardiología. Published by Elsevier España, S.L.U. All rights reserved.

A new mutation affecting the converter region of the beta-myosin heavy chain related to hypertrophic cardiomyopathy with poor prognosis



Nueva mutación de la región conversora de la cadena pesada de la beta-miosina relacionada con miocardiopatía hipertrófica de mal pronóstico

To the Editor,

Hypertrophic cardiomyopathy (HCM) is an autosomal dominant disorder and is the most common heritable cardiomyopathy.¹ Although several mutations have been related to HCM with poor prognosis, the prognostic value of specific mutations in HCM remains controversial. Genetic variants in the β -myosin heavy

chain encoded by *MYH7* involving the so-called “converter region” have been associated with early disease and higher rates of transplant and malignant arrhythmias.² The converter domain extends from Phe-709 to Arg-777 and is believed to be a key element of the actomyosin complex where elastic distortion occurs.

We describe a family with a previously undescribed genetic variant in the converter region in *MYH7* (c.2212A > C; p.Ser738Arg). The index case is a 42-year-old woman diagnosed with HCM when she was 24 years old and who was admitted to the cardiology ward due to heart failure. An echocardiogram showed severe biventricular systolic dysfunction. Although she received specific treatment for heart failure (table 1), at the age of 45 years she required a heart transplant.

Table 1

Patients' clinical characteristics

Patient	Birth year	Age at HCM diagnosis, y	Maximum myocardial thickness	LVOT gradient	Mitral regurgitation	LVEF	LGE	Symptoms	Arrhythmia	Treatment	Implantable devices	Final outcome
1 (index case)	1960	24 y (1984)	> 18 mm	NA	Moderate (functional)	< 30%	NA	Syncope (29 y) Heart failure (42 y)	Atrial fibrillation	ACEI Sotalol Digitalis Warfarin Loop diuretics	ICD – CRT (2002)	Transplant (45 y)
2	1990	22 y (2012)	18 mm	48 mmHg	Moderate (SAM)	61%	Yes	None	NSVT	Atenolol	ICD (2015)	Follow-up

ACEI, angiotensin-converting enzyme inhibitor; CRT, cardiac resynchronization therapy; HCM, hypertrophic cardiomyopathy; ICD, implantable cardiac defibrillator; LGE, late gadolinium enhancement; LVEF, left ventricular ejection fraction; LVOT, left ventricular outflow tract; NA, not available; NSVT, nonsustained ventricular tachycardia; SAM, systolic anterior motion.

A genetic test using new generation sequencing of a cardiomyopathies general panel including 17 genes (*ACTC*, *DES*, *FLNC*, *GLA*, *LAMP2*, *MYBPC3*, *MYH7*, *MYL2*, *MYL3*, *PLN*, *PRKAG2*, *PTPN11*, *TNNC1*, *TNNI3*, *TNNI2*, *TPM1*, and *TTR*) was performed using an Illumina HiSeq sequencer. Alignment and filtering of variants was performed in a custom in-house pipeline. Variant pathogenicity was classified according to the American College of Medical Genetics and Genomics recommendations.

A missense genetic variant in *MYH7* (c.2212A > C; p.Ser738Arg) was identified. This genetic variant had neither been previously described nor reported in general population databases. The variant affects a conserved amino-acid in the “converter region” of the protein. Three other variants have been described in the same residue in association with HCM (p.Ser738Asn, p.Ser738Arg and p.Ser738Thr). In silico predictors (SIFT, Polyphen-2) consider this variant probably deleterious. The variant was considered likely pathogenic.

Family screening showed that the patient had 2 (a male and a female) healthy children with negative genetic testing. Her third child, a male diagnosed with HCM when he was 22 years old, carried the same mutation. The patient's mother died before HCM diagnosis. Her father is currently alive and HCM has been ruled out with echocardiogram, although he declined to provide consent for genetic testing. In one of the patient's sisters, HCM was ruled out after complete evaluation and genetic testing. The other three siblings refused evaluation. The family pedigree is shown in figure 1A.

The son of the index case was diagnosed with HCM when he was 22 years old. He is currently 28 years old. Severe hypertrophy has been documented (maximal wall thickness of 18 mm) with normal ventricular function and basal left ventricular outflow tract obstruction (48 mmHg despite atenolol 100 mg twice a day) and moderate mitral regurgitation secondary to systolic anterior motion of the mitral valve. Cardiac magnetic resonance showed intramyocardial late gadolinium enhancement (LGE) in the basal anterior segment and in the mid inferoseptal segment (figure 1B–E). Holter-electrocardiogram showed nonsustained ventricular tachycardia. Estimated sudden cardiac risk was 6.65%¹ and an ICD

was implanted when he was 25 years old. Sanger sequencing showed that this patient was also a carrier of p.Ser738Arg.

Guidelines for HCM recommend long-term follow-up for healthy carriers of genetic variants.¹ However, recommendations based on specific variants are still lacking. Identification of variants related to worse prognosis is key to taking personalized therapeutic decisions.

García-Gustiniani et al.³ reported a cohort of 117 patients with mutations in the converter region and described low and high-risk variants.

We describe a variant in the *MYH7* converter region related to HCM with early development of myocardial hypertrophy and fibrosis, and rapid progression to systolic dysfunction and heart failure.

Almost 3% of HCM patients develop systolic dysfunction. Early identification of these high-risk patients is mandatory. Family history of end-stage HCM, diagnosis at a young age, ventricular tachycardia and the presence and the extension of LGE can predict the development of systolic dysfunction in HCM.⁴ Mutations in the *MYH7* converter region have been associated with early development of HCM and an increased incidence of left ventricular dysfunction.³ The same region has also been associated with a phenotypic spectrum including dilated, noncompacted and restrictive cardiomyopathies with some individuals showing overlapping features.³

Our index case was diagnosed with HCM at a young age and showed rapidly progressive systolic dysfunction requiring heart transplant. Her son was diagnosed at the age of 22 years, had an elevated high-risk for SCD and received an implantable cardiac defibrillator when he was 25 years old. In addition, he has several risk factors for early systolic dysfunction.

In conclusion, genetic testing seems to be an adequate tool to assess prognosis in HCM, although it is still underused. The c.2212A > C; p.Ser738Arg mutation in the *MYH7* converter region may be a marker of rapid progression to end-stage HCM and may also confer an increased risk of SCD. Future studies and reports would help to increase our knowledge of this field and to offer personalized follow-up.

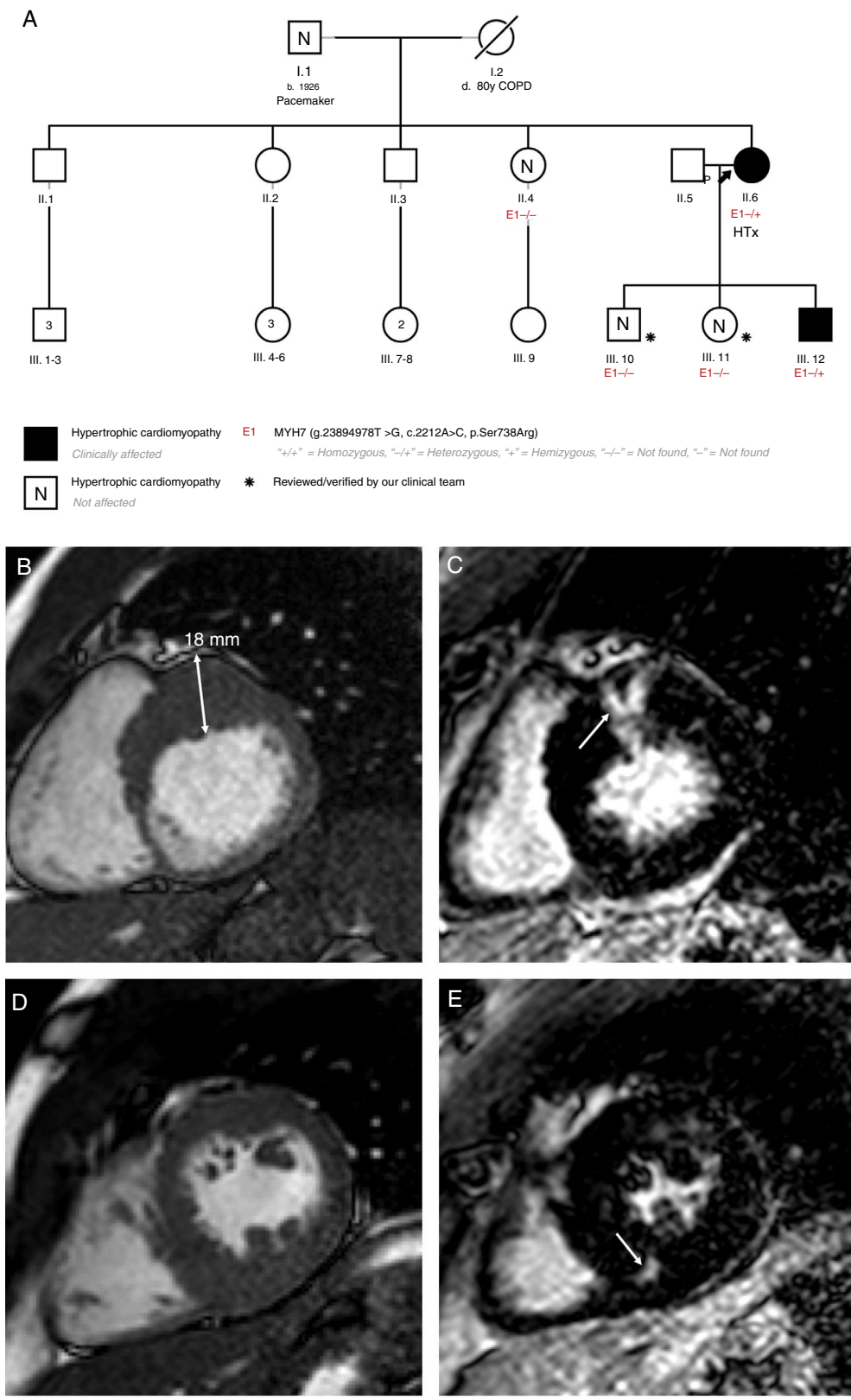


Figure 1. A: patients' familial pedigree. Black arrow points to index case. B: case 2, cardiac magnetic resonance. Short axis-basal. C: case 2, cardiac magnetic resonance. Late gadolinium enhancement in the basal anterior segment (arrow). D: case 2, cardiac magnetic resonance. Short axis-papillary muscles. E: case 2, cardiac magnetic resonance. Late gadolinium enhancement in the mid inferoseptal segment (arrow). COPD, chronic obstructive pulmonary disease; HTX, heart transplant.

Jorge Nuche,^{a,b,c,d} Rafael Salguero-Bodes,^{a,b,d}
 María Valverde-Gómez,^{a,b,d} Juan F. Delgado,^{a,b,d}
 Fernando Arribas-Ynsaurriaga,^{a,b,d} and Julián Palomino-Doza^{a,b,*}

^aServicio de Cardiología, Hospital Universitario 12 de Octubre, Instituto de Investigación Sanitaria Hospital 12 de Octubre (i+12), Madrid, Spain

^bCentro de Investigación Biomédica en Red de enfermedades Cardiovasculares (CIBERCV), Spain

^cCentro Nacional de Investigaciones Cardiovasculares, Madrid, Spain

^dDepartamento de Medicina, Facultad de Medicina, Universidad Complutense, Madrid, Spain

* Corresponding author:

E-mail address: julian.palomino@salud.madrid.org

(J. Palomino-Doza).

Available online 12 August 2019

REFERENCES

1. Elliott PM, Anastakis A, Borger MA, et al. 2014 ESC Guidelines on diagnosis and management of hypertrophic cardiomyopathy: the Task Force for the Diagnosis and Management of Hypertrophic Cardiomyopathy of the European Society of Cardiology (ESC). *Eur Heart J*. 2014;35:2733–2779.
2. Geske JB, Ommen SR, Gersh BJ. Hypertrophic Cardiomyopathy: Clinical Update. *JACC Heart Fail*. 2018;6:364–375.
3. García-Giustiniani D, Arad M, Ortíz-Genga M, et al. Phenotype and prognostic correlations of the converter region mutations affecting the β myosin heavy chain. *Heart Br Card Soc*. 2015;101:1047–1053.
4. Lopes LR, Brito D, Belo A, Cardim N. Portuguese Registry of Hypertrophic Cardiomyopathy Genetic characterization and genotype-phenotype associations in a large cohort of patients with hypertrophic cardiomyopathy - An ancillary study of the Portuguese registry of hypertrophic cardiomyopathy. *Int J Cardiol*. 2019;278:173–179.

<https://doi.org/10.1016/j.rec.2019.07.001>

1885-5857/

© 2019 Sociedad Española de Cardiología. Published by Elsevier España, S.L.U. All rights reserved.

Impact of preoperative management with subatmospheric therapy using nitrogen in neonates with congenital heart disease



Impacto del tratamiento preoperatorio subatmosférico con nitrógeno en neonatos afectados de cardiopatía congénita

To the Editor,

Preoperative measures aiming to achieve a correct balance between pulmonary flow and systemic flow is of paramount importance in the preoperative stabilization of patients with single ventricle (SV) physiology and in congenital heart diseases with duct-dependent systemic or pulmonary circulation. The physiologic drop in pulmonary vascular resistance (PVR) observed after birth leads to pulmonary over-circulation and to systemic hypoperfusion with increased risk of pulmonary edema, necrotizing enterocolitis,¹ and brain stroke.²

Nitrogen inhalation therapy reduces the fraction of inhaled oxygen inducing hypoxic vascular vasoconstriction and hence PVR, thus preventing pulmonary over-circulation³ and improving cardiac output and cerebral blood supply.⁴ Nevertheless, the use of nitrogen therapy remains controversial. Moreover, no study has evaluated the direct effect of nitrogen inhalation in decreasing pulmonary over-circulation.

Lung ultrasound (LUS) has proven to be a useful tool to monitor pulmonary edema in newborns and children with congenital heart disease.^{5,6}

We report our institutional experience in the management of patients with a combination of afterload reduction and inhaled subatmospheric therapy. We included patients with SV physiology and systemic ductal dependent circulation admitted to our institution between 2016 and 2018.

After appropriate stabilization at the delivery room, and upon arrival at the neonatal intensive care unit, patients were started on prostaglandin infusion, milrinone infusion, and subatmospheric therapy. Prostaglandin infusion was initiated at 0.01 $\mu\text{g}/\text{kg}/\text{min}$, interquartile range [0.005–0.02] and milrinone at a dose ranging between 0.15 and 1 $\mu\text{g}/\text{kg}/\text{min}$. Subatmospheric therapy was instituted by adding nitrogen, targeting a fraction of inhaled oxygen of 15% to 20% through a high-flow nasal cannula or noninvasive ventilation depending on the patient's condition.

Pulmonary overflow was assessed with the LUCAS score (Lung Ultrasonography in Cardiac Surgery) score, a LUS score created by

our group (Table 1). Six sections for each patient were studied. LUS procedures were performed prior to cardiopulmonary bypass and postcardiopulmonary bypass: at 12, 24, 36, 48, and 72 hours later. This score was compared with a chest X-ray score (Table 1). Chest X-ray was done in all patients prior to and immediately after surgery.

The assessment of systemic cardiac output was based on arterial blood analyses, urine output, serum creatinine, need for inotropic support (excluding milrinone), and the presence of necrotizing enterocolitis or brain stroke (Table 2).

Eleven consecutive patients were included in this sample. The main data are shown in Table 2.

There was no correlation between scores on LUS and chest X-ray before surgery ($P = .57$) and after surgery ($P = .62$).

Blood analyses were evaluated according to the worst result prior to surgery (Table 2). Before surgery, all patients maintained adequate systemic cardiac output, urine output, and creatinine levels. There were no episodes of necrotizing enterocolitis.

Assessment of pulmonary over-circulation through LUS showed low values and only 1 patient required mechanical ventilation before surgery.

Regarding outcomes, length of mechanical ventilation after surgery was 3 days [IQR, 3–5]. One patient had a brain stroke (9.1%). Overall mortality after surgery was nil.

There was a strong correlation between inotrope score and LUCAS score ($P \leq .05$ at all evaluated times). Higher LUCAS scores were correlated with more inotropic medication.

Blood tests showed no differences in partial pressure of oxygen (PaO_2) or partial pressure of carbon dioxide (PaCO_2) in patients with lower or higher LUCAS scores ($P > .05$).

The ratio of pulmonary/systemic blood flow in SV physiology patients directly depends on the ratio between existing vascular resistances. Immediately after birth, newborns with SV physiology usually remain well balanced since circulation remains as in fetal life, with high PVR and low systemic vascular resistance. This balance is altered by the physiologic drop in PVR that occurs after the first days of life. To avoid pulmonary over-circulation and systemic hypoperfusion, several strategies have been evaluated including permissive mild acidosis, hypoventilation, therapeutic hypercarbia, and subatmospheric gas therapy.

As blood flow follows the path of least resistance, it is extremely important to decrease systemic vascular resistance in order to avoid systemic hypoperfusion. The rapid use of both milrinone and subatmospheric therapy could play an important role in balancing it.