

ECG Contest

ECG, August 2020

ECG de agosto de 2020

Martín Ibarrola

Centro Cardiovascular BV, Buenos Aires, Argentina



An 8-year-old boy attended the clinic for assessment of a murmur. He played football 3 times a week and was asymptomatic, with no personal or family history of interest. His blood pressure was 90/50 mmHg. S_1 and S_2 were normal while S_3 and S_4 were absent. He had a 2/6 systolic murmur in the aortic area, without radiation.

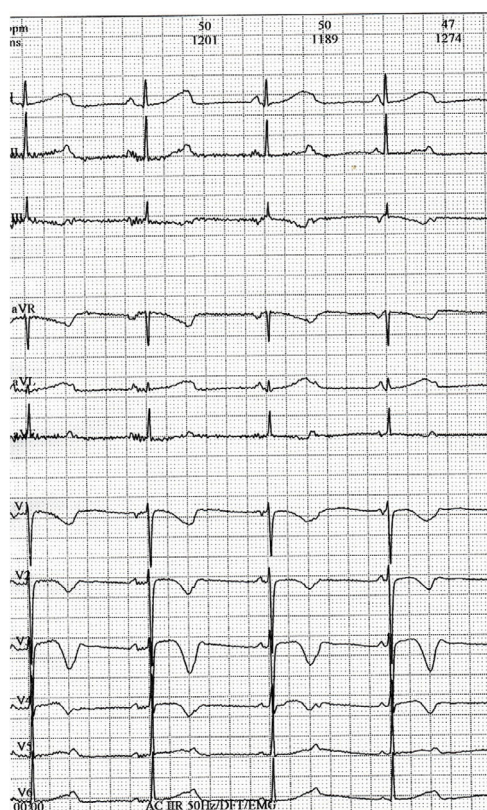


Figure 1.

What is the interpretation of the electrocardiogram recorded (figure 1)?

1. Sinus bradycardia with short PR. Physiological adaptation to exercise
2. Negative T waves are not normal until V_4 and he presented prolonged QTc
3. Complete atrioventricular block
4. Isorhythmic atrioventricular dissociation of physiological origin, given the patient plays sports

Submit your answer to <http://www.revespcardiol.org/en/electroreto/73/08>. The answer will be published in the next issue (September 2020). #RetoECG.

E-mail address: martinibarrola@gmail.com

<https://doi.org/10.1016/j.rec.2019.12.018>

1885-5857/© 2019 Sociedad Española de Cardiología. Published by Elsevier España, S.L.U. All rights reserved.