

ECG Contest

ECG, October 2020

ECG de octubre de 2020

Francisco Ribes,* Ángel Martínez-Brótons, and Ricardo Ruiz-Granell

Unidad de Arritmias, Servicio de Cardiología, Hospital Clínico Universitario de Valencia, Valencia, Spain



A 17-year-old boy experienced an episode of palpitations and presyncope while participating in competitive sports. The patient arrived at the emergency room after 30 minutes, and the symptoms remitted spontaneously. Resting ECG showed a negative T-wave in V₁₋₂, with no other abnormal findings. Echocardiography and exercise testing were normal. A 24-hour Holter ECG showed frequent ventricular extrasystoles without any complex forms or tachycardias. In view of the patient's history, a Holter monitoring device was implanted and cardiac magnetic resonance was performed. This imaging study showed intense gadolinium uptake at the free right ventricular wall, with no morphological abnormalities or dysfunction. The day after implantation, the warning shown in figure 1 and figure 2 was received during remote monitoring and the patient reported that he had been running.

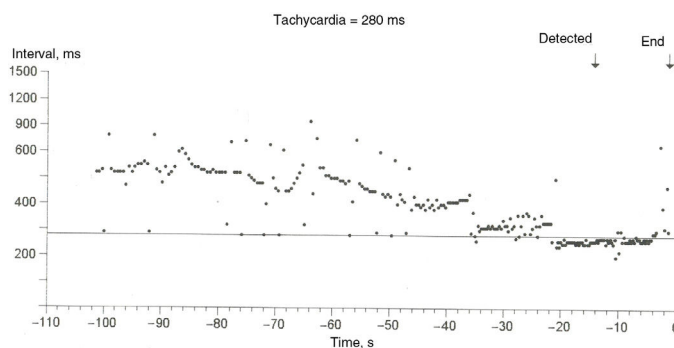


Figure 1.

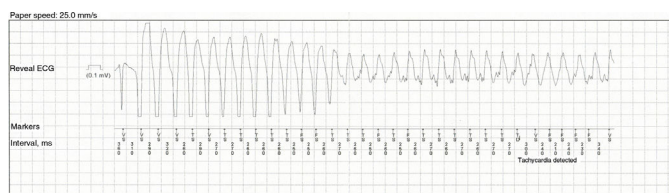


Figure 2.

What do you think was the most likely diagnosis?

1. Sinus tachycardia
2. Aberrant supraventricular tachycardia
3. Pre-excited atrial flutter
4. Sustained monomorphic ventricular tachycardia

Submit your answer for this ECG Contest to <http://www.revespcardiol.org/en/electroreto/73/10>. The answer will be published in the next issue (November 2020). #RetoECG.

* Corresponding author:
E-mail address: fribestur@gmail.com (F. Ribes).