

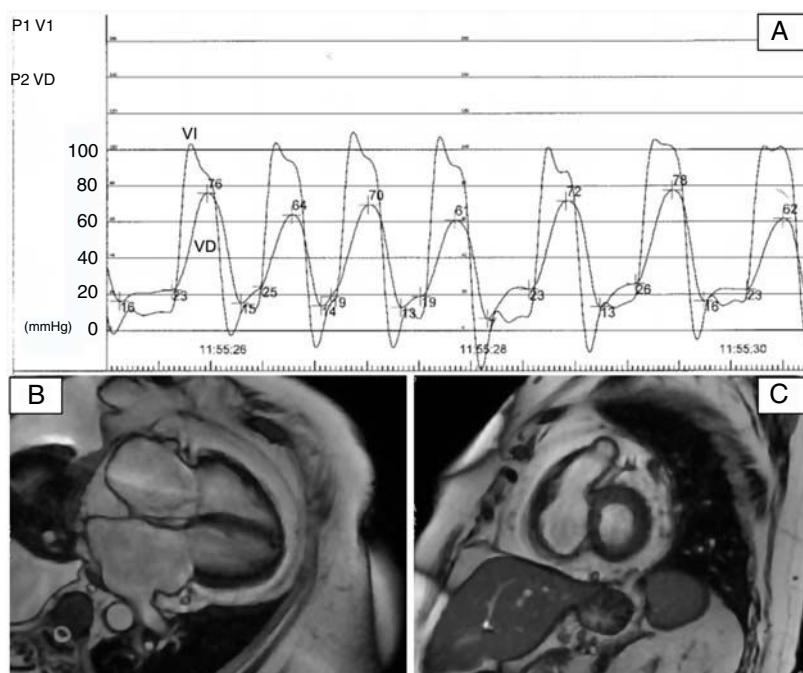Figure 2. A, Cardiac catheterization showing a left ventricular dip and plateau pattern with elevation and equalization of end-diastolic pressures in both ventricles. B and C, Steady-state free precession cardiac magnetic resonance imaging 4-chamber view (B) and short-axis (C) showing abundant epicardial fat accumulation.

As occurred in our case, a Doppler echocardiogram can show some signs of constrictive physiology and impaired ventricular filling, such as an early diastolic notch on the interventricular septal echocardiogram in mode M, in addition to prominent diastolic flow in the inferior vena cava and the hepatic veins, which show flow reversal with expiration. Characteristic cardiac catheterization findings, also observed in our case, include elevation and equalization of diastolic pressures in both ventricles (the classic dip and plateau or square root sign).

Constrictive physiology due to epicardial fat should be suspected in patients with compatible clinical and other diagnostic findings.

APPENDIX. SUPPLEMENTARY DATA

Supplementary data associated with this article can be found in the online version available at <https://doi.org/10.1016/j.rec.2020.04.022>

Eduardo Martínez-Gómez,* Javier Higuera, and Carmen Olmos

Servicio de Cardiología, Hospital Clínico San Carlos, Madrid, Spain

*Corresponding author:

E-mail address: emartinezg1@gmail.com (E. Martínez-Gómez).

Available online 27 June 2022

REFERENCES

1. Derelis S, Bayramoğlu A, Yontar OC, Cerçit S, Gürsoy MO. Epicardial fat thickness: a new predictor of successful electrical cardioversion and atrial fibrillation recurrence. *Echocardiography*. 2018;35:1926–1931.
2. Van Woerden G, Gorter TM, Westenbrink BD, Willems TP, van Veldhuisen DJ, Rienstra M. Epicardial fat in heart failure patients with mid-range and preserved ejection fraction. *Eur J Heart Fail*. 2018;20:1559–1566.
3. Gi-Won Do, Gorter TM, Westenbrink BD, Willems TP, van Veldhuisen DJ, Rienstra M. A case of constrictive pericarditis associated with huge epicardial fat volume. *Korean Circ J*. 2009;39:116–120.
4. Nestelberger T, Rupprecht Lange, Michael Kühne, Philip Haafa. Calcified epicardial fat necrosis causing epicardial constriction. *Eur Heart J*. 2019;40:3698.
5. Ardhanari S. Systematic review of non-invasive cardiovascular imaging in the diagnosis of constrictive pericarditis. *Indian Heart J*. 2017;69:57–67.

<https://doi.org/10.1016/j.rec.2020.04.022>
1885-5857/

© 2020 Sociedad Española de Cardiología. Published by Elsevier España, S.L.U. All rights reserved.

Coronary arterial segmental stenosis quantified by MDCT: correlation with quantitative coronary analyses by invasive angiography



Estudio de lesiones coronarias por segmentos mediante TCMD coronaria: correlación con el análisis cuantitativo por coronariografía invasiva

To the Editor,

Multidetector computed tomography (MDCT) is an established noninvasive technique that enables evaluation of calcium deposit and stenosis of the coronary arteries.¹ Some authors have assessed

the overall correlation between MDCT and invasive coronary angiography (ICA). MDCT has shown good performance for detecting coronary disease (CD), with a tendency to identify a larger atherosclerotic burden, particularly in the proximal segments.² However, there are no studies correlating the severity of coronary lesions assessed by these two techniques.

The objective of this study was to determine the diagnostic performance of MDCT in each coronary segment, using quantitative coronary analysis (QCA) of stenosis detected on ICA as the reference pattern.

We analyzed 1648 segments in 103 patients with a previous MDCT examination referred for ICA between November and March 2019. The inclusion criteria were age \geq 18 years, stable clinical

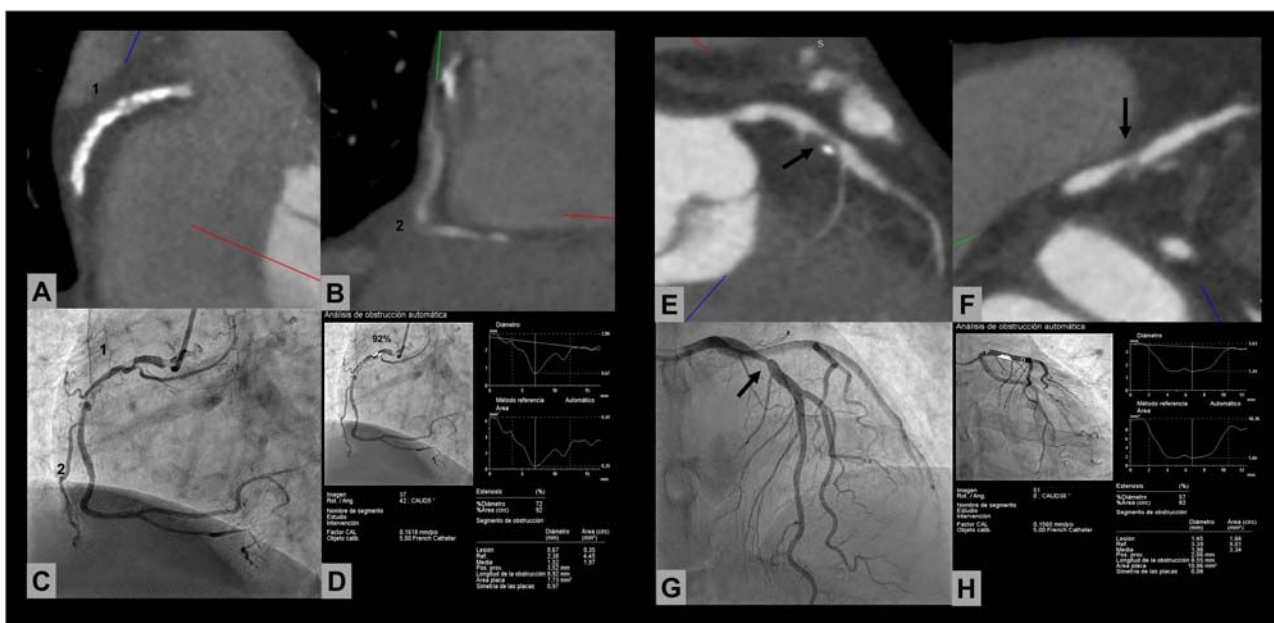


Figure 1. Correlation analysis between multidetector computed tomography (MDCT) and invasive coronary angiography (ICA). The series of images at the left shows a right middle coronary artery lesion that is not assessable on MDCT in a patient with a calcium score > 2000. On quantitative coronary analysis (QCA), stenosis was 92%. The series on the right shows an example of a good correlation between MDCT and QCA in a patient with a focal lesion in the proximal left anterior descending artery (arrow).

status, and radial artery access, where vasodilators were administered at the start of the procedure. We did not exclude patients with a history of ischemic heart disease, previous stents, atrial fibrillation, and elevated coronary artery calcium (CAC) score (Agatston > 400), for which some studies have shown a good diagnostic yield for MDCT.³ The study was approved by the hospital ethics committee, and informed consent for participation was obtained from all patients (CEIm code: 19.03.1384-GHM).

MDCT was performed on 160-detector and 320-detector Toshiba systems (Toshiba Medical Systems, Japan) (61 and

42 imaging studies, respectively), and images were evaluated by experienced cardiologists (> 1000 MDCT/year). Significant CD was defined as stenosis ≥ 50%: moderate between 50% and 70%, and severe > 70%.

Lesion quantification by ICA involved a deferred, masked analysis performed with the QCA software package provided in the Philips Medical System Integris Allura Xper FD-20. Measurements were done in the projection showing maximum angiographic stenosis, in end-diastole, with calibration of the diagnostic catheter (figure 1). The classification in the modified

Table 1

Correlation study: stenosis quantified by multidetector computed tomography vs invasive coronary angiography in each of the coronary segments

Segment analyzed	Number of segments	κ	Degree of correlation
Proximal RCA (1)	50	0.91	Excellent
Mid RCA (2)	135	0.71	Good
Distal RCA (3)	44	0.72	Good
Posterior interventricular (4)	16	0.79	Good
Posterolateral (16)	7	0.77	Good
Left main coronary artery (5)	41	0.88	Good
Proximal LAD (6)	179	0.96	Excellent
Mid LAD (7)	180	0.92	Excellent
Distal LAD (8)	35	0.76	Good
First diagonal (9)	17	0.93	Excellent
Second diagonal (10)	5	Not assessable	
Proximal circumflex (11)	20	0.96	Excellent
Intermediate/First obtuse marginal (12)	68	0.92	Excellent
Mid circumflex (13)	17	0.93	Excellent
Second obtuse marginal (14)	3	Not assessable	
Third obtuse marginal (15)	1	Not assessable	

RCA, right coronary artery; LAD, left anterior descending artery.

American Heart Association model was used for coronary segmentation.⁴

The mean age of the population was 67 years, 78% were men, and hypertension was the most prevalent risk factor. The mean CAC score was 782 ± 1034 [23–4523], and 14% of patients had a CAC score > 400. The mean heart rate during image acquisition was 66 bpm.

Of the 1648 coronary segments analyzed, 1549 (94%) could be assessed, and MDCT was considered of good quality in 96 patients (93%). Among segments that could not be assessed ($n = 99$), the most frequent were the mid- and distal right coronary artery, and 84% were in patients with a CAC score > 100. MDCT was rated suboptimal in 7 patients: 5 had a CAC score > 1000, and 2 had an elevated heart rate at image acquisition.

In the MDCT images, CD was detected in 53.2% (824/1549) of the segments evaluated; stenosis was mild in 6% (50/824), moderate in 63% (519/824), and severe in 31% (255/824).

As to the ICA evaluation, QCA was performed in 889 lesions: stenosis was mild in 8% (69/889), moderate in 60% (531/889), and severe in 32% (289/889). In total, 98 significant lesions ($\geq 50\%$) were detected on ICA, but not on MDCT; 67 of these (68%) were located in the distal segments (distal left anterior descending artery and distal right coronary-posterior descending artery).

In the analysis by segments, excellent correlations ($\kappa > 0.81$) were found for most segments. Correlations were good (κ between 0.61 and 0.80) for the main coronary, mid-right coronary artery, distal left anterior descending, and distal posterior descending, with MDCT showing a tendency to overestimate the degree of stenosis in the main coronary and mid-right coronary arteries, and underestimate lesions in the distal segments (table 1).

The overall sensitivity of MDCT for detecting significant CD, using QCA on ICA as the reference pattern, was 90.5%, with a specificity of 89.8%, positive predictive value of 90.1%, and negative predictive value of 90.3%. Eighty-two lesions showing $\geq 50\%$ stenosis on MDCT were not significant in the ICA QCA analysis (false positives) and 78 lesions showing $\geq 50\%$ stenosis on ICA were not significant on MDCT (false negatives). The net diagnostic yield of MDCT (estimated by ROC curve) was 0.95 (95% confidence interval 0.92–0.97).

In this study, MDCT was suitable for quantifying stenosis of the major coronary vessels, using QCA on ICA as the reference, even in patients with previous stents, coronary calcification, or atrial fibrillation, with the greatest limitation in the assessment of distal lesions. To our knowledge, this is the first study to carry out a correlation analysis between these 2 techniques for each coronary segment in an unselected study population.

FUNDING

L. Fernández-Friera received a grant from Carlos III Health Institute, Spain (PI15/O2019). L. Fernández-Friera and A. Moreno-Arciniegas received a grant from the Community of Madrid, Spain (AORTASANA-CM; B2017/BMD-3676), European Social Fund (ESF).

Leire Unzué,^{a,d,*} Belén Díaz-Antón,^{b,c,d} Eulogio García,^a Andrea Moreno-Arciniegas,^{b,c} Francisco Javier Parra,^c and Leticia Fernández-Friera^{b,c,d,e,f,*}

^aServicio de Hemodinámica y Cardiología Intervencionista-HM CIEC, Hospital Universitario HM Montepíncipe, HM Hospitales, Madrid, Spain

^bUnidad de Imagen Cardíaca, Hospital Universitario HM Montepíncipe-CIEC, HM Hospitales, Madrid, Spain

^cServicio de Cardiología, Hospital Universitario HM Montepíncipe-CIEC, HM Hospitales, Madrid, Spain

^dUniversidad CEU San Pablo, Madrid, Spain

^eCentro Nacional de Investigaciones Cardiovasculares Carlos III (CNIC), Madrid, Spain

^fCIBER de enfermedades Cardiovasculares (CIBERCV), Madrid, Spain

*Corresponding author:

E-mail addresses: lfernandezfriera@hmhospitales.com (L. Unzué), leireunzue@yahoo.es (L. Fernández-Friera).

Available online 18 July 2020

REFERENCES

- Meijboom WB, van Mieghem CA, Mollet NR, et al. 64-slice computed tomography coronary angiography in patients with high, intermediate, or low pretest probability of significant coronary artery disease. *J Am Coll Cardiol.* 2007;50:469–1475.
- Rodríguez-Granillo. Carrascosa P, Deviggiano A, et al. Extension and spatial distribution of atherosclerotic burden using virtual monochromatic imaging derived from dual-energy computed tomography. *Rev Esp Cardiol.* 2016;69:915–922.
- Díaz-Antón B, Solís J, Díaz-Morales R, et al. Diagnostic and prognostic value of coronary computed tomography angiography in patients with severe calcification. *J Cardiovasc Transl Res.* 2020. <http://dx.doi.org/10.1007/s12265-020-09977-4>.
- Cerqueira. Weissman NJ, Dilsizian V, et al. Standardized myocardial segmentation and nomenclature for tomographic imaging of the heart. A statement for healthcare professionals from the Cardiac Imaging Committee of the Council on Clinical Cardiology of the American Heart Association. *Circulation.* 2020;105:539–542.

<https://doi.org/10.1016/j.rec.2020.04.029>
1885-5857/

© 2020 Sociedad Española de Cardiología. Published by Elsevier España, S.L.U. All rights reserved.

Spanish Cardiovascular Imaging Registry. Second Official Report of the Cardiovascular Imaging Association of the Spanish Society of Cardiology (2019)



Registro Español de Imagen Cardíaca. II Informe Oficial de la Asociación de Imagen Cardíaca de la Sociedad Española de Cardiología (2019)

To the Editor,

In 2017 the Cardiovascular Imaging Association of the Spanish Society of Cardiology created the first Cardiovascular Imaging

Registry.¹ Another online survey was conducted in January 2020 to provide a longitudinal analysis, collecting data from 94 Spanish institutions on activity during the year 2019. Responses were received from 60% of those surveyed; 86% of these were from public institutions, and all autonomous communities except the Canary Islands were represented.

Table 1 lists the human and material resources, as well as the activity levels of the various cardiovascular imaging modalities. A total of 69% of clinicians devoted more than 50% of their work hours to cardiovascular imaging. In echocardiography, 69.3% of machines was less than 10 years old, and more than 50% of those in institutions with more than 500 beds had advanced cardiovascular imaging